

# DESIGN AND IMPLEMENTATION OF AN IMAGE PROCESSING MODEL FOR THE DETECTION AND ANALYSIS OF DIABETIC NEPHROPATHY AT EARLY STAGE

<sup>1</sup>Dr.Shreesha Kalkoor M,<sup>2</sup>Dr.Priyamvada Singh,<sup>3</sup>Dr.Jayadeva T S,<sup>4</sup>Rajani K V  
<sup>1</sup>Associate Professor,<sup>2</sup>Associate Professor,<sup>3</sup>Associate Professor,<sup>4</sup>Assistant Professor  
<sup>1234</sup>Electronics and Communication Engineering Department  
<sup>1234</sup>New Horizon College of Engineering, Bangalore, India

## Abstract

A method for detection of glomerulosclerosis in diabetic nephropathy using Contour-Based Segmentation is proposed here. Pathological images of the glomerulosclerosis were acquired from various patients. It is a challenging task as 100% detection of Nephropathy disease with regular pathological procedure is not possible. A solution to the problem of segmentation of the glomerulosclerosis images for the analysis of abnormalities is proposed in this paper. The proposed method is the modification of the original ChanVese algorithm, with the varied values of parameters. The proposed method achieved better segmentation and the results are encouraging.

**Keywords—** Diabetes, Diabetic nephropathy, Fundus Images, OCT Images, Thermal IR Images, Foot Ulcers, Chanvase Algorithm, Enhancement, Segmentation, Hyperthermia

## I. INTRODUCTION

The general objective of this paper lies in the domain of diabetic foot and it follows the two already mentioned research directions: i.e., to improve the early findings and diagnosis of diabetic foot and reduce the ulcer occurrence in a diabetic foot. It will be on the basis of analysis of infrared image of thermal of sole of foot.

The two possible directions are:

Find the new strategies to improve the early stage diagnosis with detection of diabetic foot at hospitals from the analysis of infrared thermal images. Design and test a home based system to monitor foot temperature using an IR camera. Here the second objective will require the development of a dedicated system, using an IR camera to measure the temperature of the plantar foot at home. Developing and testing such a device in a small time is a difficult issue. The Fundus image quality depends on procedure of acquisition and under which operators using, and the quality again depends upon the exclusion criteria which applied on the images. The conversion of colour image into black and white image then moat operator is applied. Diabetic Mellitus (DM) is a metabolic disorder that characterized by inability of the pancreas to control blood glucose concentration. This predicament results may make out blood glucose levels out of range. According to International Diabetic Federation (IDF), India is one of the 6 countries of the IDF SEA (South East Asia) region. 387 million people have diabetes in the world and 75 mil-lion people in the SEA Region; by 2035 this will rise to 123 million. There were 66.8 million cases of diabetes in India in 2014.

Diabetic nephropathy has been classified into stages:

Microalbuminuria and Macroalbuminuria. Diabetic nephropathy is a clinical syndrome characterized by the following: Persistent albuminuria ( $>300$  mg/d or  $>200$   $\mu$ g/ min) that is confirmed on at least 2 occasions 3-6 months apart. Progressive decline in the Glomerular Filtration Rate (GFR) Elevated arterial blood pressure.

Diabetic Neuropathy is more common in those who have had the disease for a number of years and can lead to many kinds of problems. In other sense this is defined as grouped family of nerve problems. This disorder might result in non-functioning of various organs. Sedentary lifestyle (such as irregular eating habits, smoking and drinking) and mechanical injury to nerves because of prolonged non-diagnosis and treatment are some of the causes this disorder. Mainly this leads to faults in decision making capability of human by damaging or slowing the process of brain and neurologically connected parts of the body.

In diabetic foot, the incidence of an ulcer is time and again linked with hyperthermia. Hyperthermia is defined as a temperature greater than  $2.2^{\circ}\text{C}$  in a given region of one of the foot compared to the temperature of the same region of the contralateral foot. The major imaging modality used in this diagnosis are IR based Thermograph scanners which are most sophisticated and state-of-art modules, but the installation and the equipment are expensive leading to non-availability to the poor people.

In most of the practical cases, Image Processing methods are employed to extort or derive the imperative features from the images, which can be made use for the better understanding and analysis for further processes. The organic vision system is one of the most essential means of looking at of the world to humans, making intricate task easier for betterment of understanding. There are numerous algorithms that can be utilized for different applications but enhancement and segmentation are considered as most sort out methods for improving the details in an image. The judgment of a particular method or procedure in Image processing methods is not possible to say that one method is best for all applications, but one can use trial and error method as a practical approach for obtaining the perfect results. Even though a good number of methods available in Digital Image Processing Literature, the foremost methods used in for the most part of the recent day Image Processing models are Enhancement and Segmentation methods because of their ease to use and applicability. Image Enhancement is an elementary assignment in digital image processing and analysis, intended to perk up the manifestation of image in terms of human brightness perception. Whereas the Segmentation is principally helpful in categorization of objects and labeling of the features extracted from image for easy analysis. One should look into that processing of images is done exclusive of blotching the veracity of original image.

## II. OBJECTIVES AND SCOPE

The Objectives of this work are given below in a simple and obvious way that on attaining these goals will lead to the betterment of mankind to prevent further complications of diabetes.

- To study recent algorithms related to Image
- Enhancement (**Histograms, CLAHE** etc) and Segmentation (**K-Means, Fuzzy C means and Watershed**) to solve the problem and attempt to modify the algorithm for specific application.
- To establish the **new approach** by combining the image processing (Enhancement and segmentation) techniques as per requirements and also to tabulate statistical comparison of image attributes.
- To explore and investigate the significance of less commonly used estimate parameters in process of medical image analysis.
- To develop a frame work for qualitative automatic medical imaging to detect and forecast the abnormalities in the considered problem for accurate diagnosis.
- To make the products of this research freely avail-able to the academic and medical community as open standard system.

### III. GENERAL INFORMATION ON DIABETIC FOOT

The Ulcer in the foot is important with a serious complication of diabetes mellitus (DM). Our aim is for prevention of Ulcers, with treatment of multi disciplinary of ulcers, and near monitoring on a regular basis, which reduces the surgical operation that compel frequencies from 50 to 90%. By this several organizations in countries, such as the W.H.O. and the International Diabetes Federation, set goals to reduce the rate of surgical operations as maximum as possible and diabetic patients has up to 22 times greater risk of amputation of lower limbs compared with normal person However, the patients with both weak nerves and proper blood flow the foot ulcer, symptoms not present. Below Figure explains the visualization of the ulceration mechanism, and Figure below shows an illustration of foot ulcers.

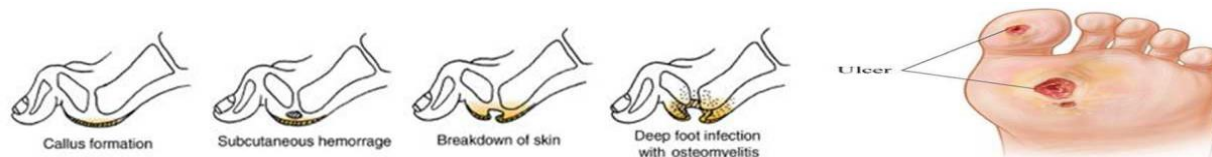


Figure 1. Foot ulcer due to repetitive stress

The above figure shows the areas where foot ulcer is very likely to occur. These can be named areas at high risk as illustrates in the picture. So detecting these problems in these zones is of a great interest. Here we may consider the tiny areas at less risk are circle with 2cm of radius. This characteristic is an important for systems build to detect these problems in a diabetic foot.

#### Diagnosis of Diabetic Foot

From this analysis, a risk based classification is given by the medical doctor. The risk here means that the risk of developing a foot ulcer. This classification may not be same in every country.

For example, in India, the classification used in most of the hospitals is as follows:

**Grade 0:** No neuropathy, no ischemia, possible foot deformations are independent of the diabetes.

**Grade 1:** Small neuropathy defined as the absence of sensation at least one point of the points is at risk on the feet.

**Grade 2:** Neuropathy with foot deformation and ischemia.

**Grade 3:** Previous amputations and ulcers that has been more than for 3 months.

A zero grade means that the patient has no diabetic foot. Any other numbers of grade mean patient has diabetic foot. And the risk based classification is Low risk, Medium risk and High risk, and MRI images also used to determine the earliest stage diabetic. In Diabetic Retinopathy, we use the MOAT Operator for image sharpening, which can be done within the frequency domain using a high - pass filter, the transitions of edges, and sharpness in the gray levels of the images represent the high-frequency components. The attenuation of low-frequency components will be done in the Fourier Transform, without disturbing the high-frequency information.

### IV. PROPOSED METHOD

In Figure 2 a modified Chanvese method named “Global Region Based Chanvese Algorithm for betterment of results is being used. Global region thresholding used here is based on Morphological operation. The Methodology is given below as a step by step procedure to solve the considered application.

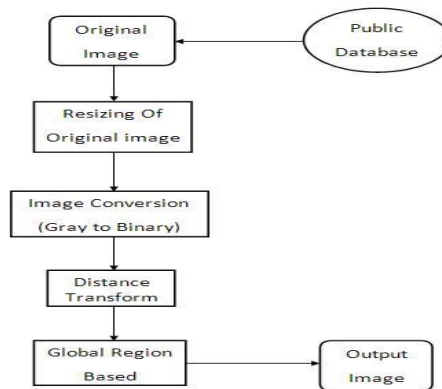


Figure 2. Global region based chanvase algorithm

### A. Medical Visual Data Base Collection

To collect the image data base (Nephropathy related images) from public database and also from Diabetic research institutes (**Already taking help from Diabetic Care Centre, Nandalur, A.P.**) The visual data consists of varied databases with documents of differing modalities and varying characteristics.

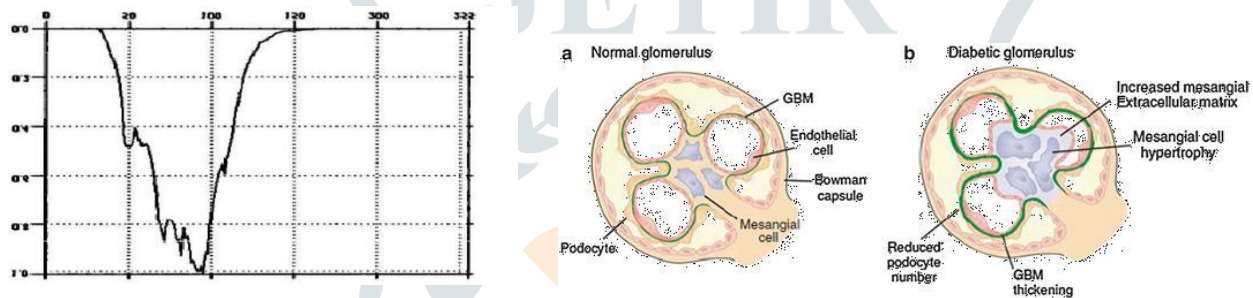


Figure 3. Characteristic glomerular changes of diabetic nephropathy

As an instance an image is used in Figure 3 shows the difference between normal and abnormal (Diabetic) groups. Main changes observed here are with reduction in podocytes and increased mesangial cell enlargement leading to Diabetic Nephropathy.

Figure 3 shows the difference between healthy nerves and damaged nerves. It is obvious pictures that a Diabetic patient will have a some sort of nerve and blood vessel damage in his lifetime when compared to normal healthy people.

### B. Implementation of Algorithms

The image enhancement and segmentation algorithms for which implementations are available will be considered for the purpose. The algorithms for which no implementation is available will be adopted as part of the project.

The preferred programming platform is **MATLAB** technical computing language (**R2010a**) using toolboxes image acquisition, image processing, fixed point and neural networks. Algorithms implemented on other platform such as medical imaging software **MIPAV**.

### C. Testing

The algorithms will be tested on the collected medical visual data base. Some algorithms may extract important features from extensive testing.

### D. Analysis

Using the results of the tests, an assessment of the algorithm will be made. Therefore a statistical comparison and graphical representation between a normal group (DM) and abnormal group (DM with nephropathy and neuropathy) will be tabulated for each algorithm. The results will be compared with

the clinical characteristics for a certain period of time taking the help of medical community. Any relative strengths or weaknesses of algorithms should be found. The concepts in the algorithms will be assessed for relevance based on the quality of the algorithms with reference to considered problem/application.

### ***E. Modified Algorithm***

Based on the analysis, one or more improvements to existing recent Image enhancement and segmentation techniques may become apparent. If this occurs, a new algorithm will be devised which demonstrates the improvements.

### ***F. Test Modified Algorithm***

The improved algorithm will then be evaluated on the basis of the requirements.

### ***G. Expected Result***

- Survey and analysis of existing methods.
- Strengths and weaknesses of algorithm in comparison with each other.
- Finally the research project might result in the creation of a new algorithm that combines ideas from the existing image processing techniques.

### **Segmentation**

There are many common methods for segmentation, such as edge detection, region growing, and most recently active contours. Active contours are the methods which iteratively modify an initial contour to fit the desired contour. Here we choose to implement the globalization based Chan and Vese segmentation method. It is particularly adapted when the contours are not sharp as it is the case of this thesis.

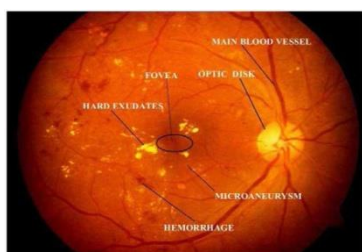
The results which are shown in Figure below is with 300 iterations. The initial contour is a circle in the middle of the image and having a diameter of 150 pixels.

## **V. RESULTS**

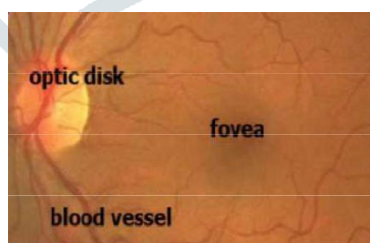
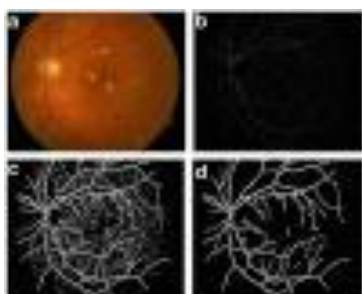
The reliable determination, the relationship between the average retinal vessel diameter and the distance from the optic disc and the width of blood vessel shows monotonic decrease by taking the distance into account of the optic disc to the centre.

### **Distance with Optic Disc to Width of Vessel**

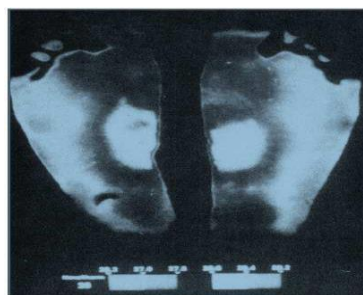
The Vessel pixels near the centre of optic disc and the width of blood vessel shows the Monotonic decrease with the centre. If the blood vessel volume isn't changed, then no need of branching.



**Figure 4: After the Distance Evaluation**



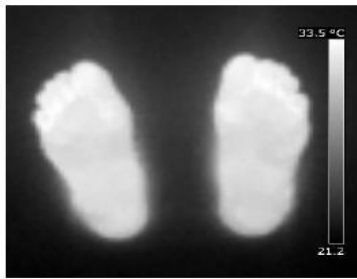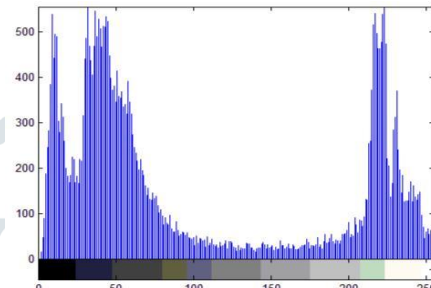
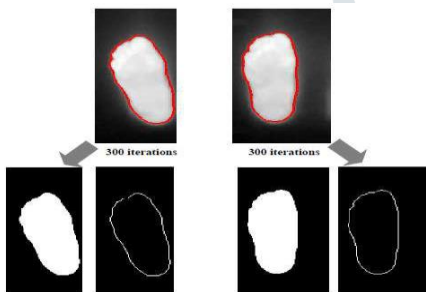
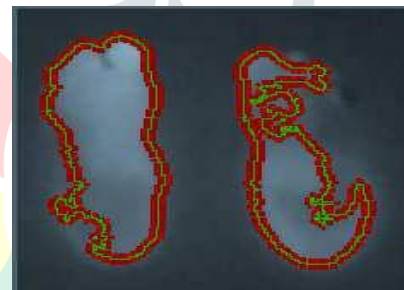
**Figure 5: Optic Disk, Blood Vessel of Eye**



**Figure 6: The Identification of Blood Vessel****Figure 7: Thermal Image Processing in a Normal Person**

After analyzing the images, in this paper the Histogram process used for funds images for color normalization, here it is required that the uniform intensity should spread along with the image and the remaining optic disc area cannot be classified generally and it is called as noise. The optic disc can be removed by edge base detection.

After detection of blood vessels by edge detection, further the morphological filter algorithm operation is used for segmentation.

**Figure 8: Mirror Image of the Foot****Figure 9: Histogram Representation****Figure 10: After Segmentation of the Image****Figure 11: After Complete Iterations, the Segmented Image**

## VI. CONCLUSION

The analysis to be carried out on the simulation results using novel image processing methods will be useful even to educate common man and easy perception of about what might be the consequences one has to face if Diabetes Mellitus is not considered as a problem to be taken care off within right time. The methods concerned here are more enhanced with respect to present persistent methods as proposed work involves sophisticated non-invasive methods to detect the abnormalities.

Guntakal Division supported here while discussing the details about Diabetes and its abnormalities.

## REFERENCES

1. Sharifi A, Vosolipour A, Sh MA, Teshnehlab M. Hierarchical takagi-sugeno type fuzzy system for diabetes mellitus fore-casting, Proceedings of 7th International Conference on Machine Learning and Cybernetics, Iran; 2008 Jul. p. 1265– 70.
2. Peres FA, Oliveira FR, Neves LA, Godoy MF. Automatic segmentation of digital images applied in cardiac medical images, Health Care Exchange (PAHCE), Pan American, Brazil; 2010 Mar. p. 38–42.
3. Intajag S, Tipsuwanporn V, Chatree CR. Retinal image enhancement in multi-mode histogram, Proceedings of World Congress on Computer Science and Information Engineering, Thailand; 2009 Mar. p. 745–49.

4. Gonzalez RC, Woods RE. Digital image processing, 1st edition, Addison-Wesley: Pearson/Prentice Hall; 1992.
5. Neuropathy (Nerve Damage) [Internet]. 2016 [cited 2016]. Available from: <http://www.diabetes.org/livingwithdiabetes/complications/neuropathy>.
6. Hom M, De Land P. Self-reported dry eyes and diabetic history. *Optometry*. 2006 Nov; 77 (11): 554-8
7. Retinopathy Working Party. A Protocol for screening for diabetic retinopathy.
8. Harrison TR: Diabetes Mellitus. In *Harrison Principle of Internal Medicine, 15th* edition. Edited by: Braunwald E, Fauci S, Kasper D, Hauser LS, Longo D, Jameson JL. USA, McGraw-Hill; 2001:2121.
9. Riordan-Eva, Asbury T, Whitaker JP: Vaughan and Asbury's General Ophthalmology. 16th edition. USA, McGraw-Hill Medical; 2003:308-310.
10. Rema M, Premkumar S, Anitha B, Deepa R, Pradeepa R, Mohan V: Prevalence of Diabetic Retinopathy in Urban India: The Chennai Urban Rural Epidemiology Study (CURES) Eye Study. *Investigative Ophthalmology and Visual Science* 2005, 46: 2328-2333
11. T. Y. Wong, F. M. Islam, and R. Klein, "Retinal vascular caliber, cardiovascular risk factors, and inflammation: The multiethnic study of atherosclerosis (MESA)," *Investigative Ophthalmology and Visual Science*, vol. 47, no. 6, pp. 2341–2350, 2006.
12. Facey K, Cummins E, Macpherson K, et al. Organisation of Services for Diabetic Retinopathy Screening. Health Technology Assessment Report 1. Health Technology Board for Scotland, 2002
13. S. S. Hayreh, "Hypertensive retinopathy," *Ophthalmologica*, vol. 198, no. 4, pp. 173–177, 1989
14. M. U. Akram, A. Tariq, M. A. Anjum, M. Y. Javed, "Automated Detection of Exudates in Colored Retinal Images for Diagnosis of Diabetic Retinopathy", *OSA Journal of Applied Optics*, Vol.51, No.20.2012
15. S. Lee, M. D. Abramoff, and J. M. Reinhardt, "Retinal atlas statistics from color fundus images," vol. 7623, 2010.
16. "A Model-Based Approach for Automated Feature Extraction in Fundus Images" Proceedings of the Ninth IEEE International Conference on Computer Vision (ICCV 2003) 2-Volume Set 0-7695-1950-4/03 \$17.00 © 2003 IEEE.
17. "Computer Based Diagnosis of Glaucoma Using Digital Fundus Images" Proceedings of the World Congress on Engineering 2013 Vol III, WCE 2013, July 3 - 5, 2013, London, U.K.
18. "Development of A Simple Diagnostic Method For The Glaucoma Using Ocular Fundus Pictures", in the Proceedings of the 2005 IEEE Engineering in Medicine and Biology 27th Annual Conference Shanghai, China, September 1-4, 2005.
19. ADA American Diabetes Association. Clinical practice recommendations 2009. *Diabetes Care* 32, S1–S98 (2009).
20. ADA American Diabetes Association. Diagnosis and Classification of Diabetes Mellitus. *Diabetes Care*, Volume 35, Supplement 1, January 2012: S64 – S71.
21. Riphagen IJ, Lambers HJ, Heerspin K, Gans ROB, Gaillard CAJM. Diseases of renal microcirculation: diabetic nephropathy, living reference work entry, *pan vascular medicine*. Springer Publications; 2015. p. 3739–68.
22. Diabetic Neuropathies [Internet]. 2016 [updated 2016 Dec 6; cited 2016 Jun 9]. Available from: <http://neuropathy-treatment.net/diabeticneuropathies/>.
23. Auliffe MM, Garry LM. Medical image processing, analysis, and visualization in clinical research, Proceedings of 14th Symposium on Computer based Medical Systems, Bethesda; 2001 Jul. p. 381–6.

24. Shenbagarajan V, Ramalingam C, Balasubramanian S, Palanivel. Tumor diagnosis in MRI brain image using ACM segmentation and ANN-LM classification techniques. Indian Journal of Science and Technology. 2016 Jan; 9(1):1– 12

