

# RUPTURED TUBAL ECTOPIC PREGNANCY WITH HEMOPERITONEUM: A CASE REPORT

\*Rajani Nanam, <sup>1</sup>Kartheek Kumar Allam, <sup>1</sup>Sowmya Tirumala, <sup>1</sup>Rishitha Krishna Kantheti, <sup>1</sup>Endla Snigdha  
Doctor of Pharmacy Students from Department of Pharmacy Practice,  
St. Peter's Institute of Pharmaceutical Sciences, Kakatiya University Warangal-506001, Telangana State, India.

## ABSTRACT:

**Introduction:** Ectopic pregnancy is a fatal condition which occurs outside of the uterine cavity approximately in 2% of all pregnancies. It has reported the incidence of 1 in 2,200 to 1 in 10,200 of all pregnancies. **Case presentation:** A 26 year old female patient was admitted in the hospital with chief complaints of lower abdominal pain, per vaginal bleeding continuously, vomiting one episode and loose motions 2 episodes since one day. Ruptured tubal ectopic pregnancy with hemoperitoneum was observed, laparoscopic salpingectomy was done to prevent further complications. **Conclusion:** As ectopic pregnancy is a more complicated condition, it should be identified and treated immediately. If undiagnosed or untreated it may result in maternal death due to the rupture of implantation site and intraperitoneal haemorrhage.

**Key words:** Ectopic pregnancy, salpingectomy, hemoperitoneum

## INTRODUCTION:

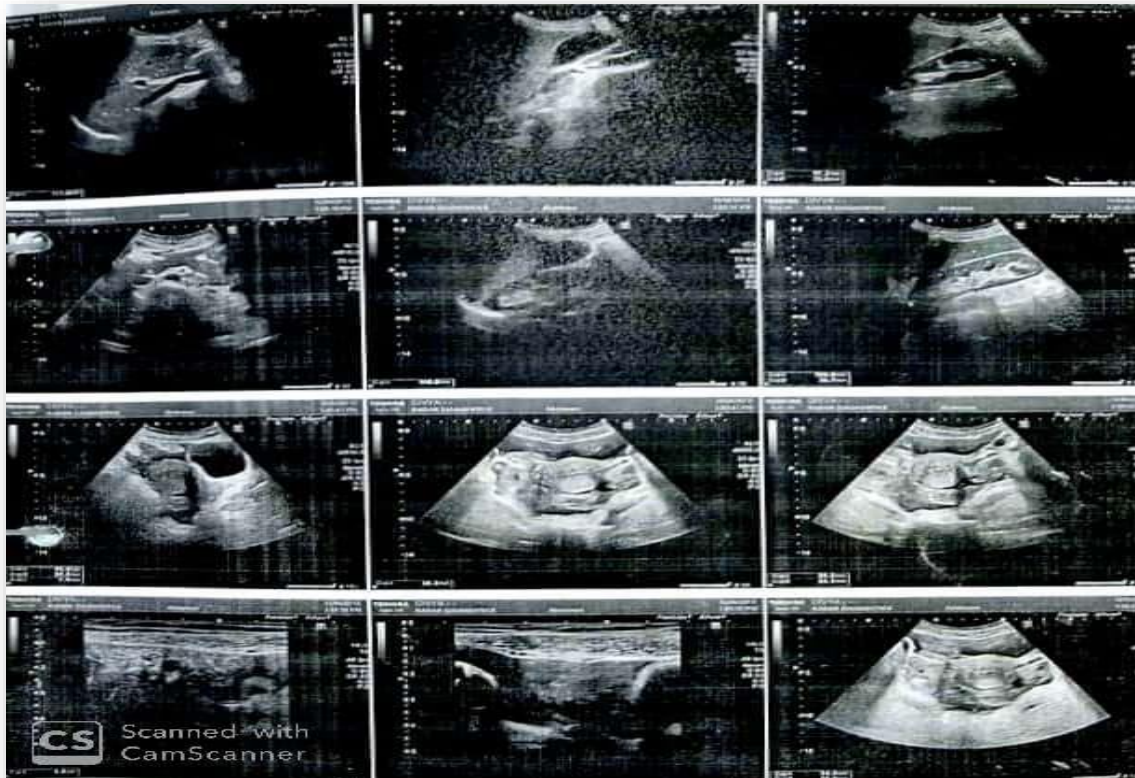
Ectopic pregnancy is a fertilized ovum implanting and maturing outside of the uterine endometrial cavity with the most common site being the fallopian tube followed by ovary and the abdomen. Most cases of abdominal pregnancy are secondary where the ovum first implants in the fallopian tube [1]. The multitude of the clinical presentations to the physician on first contact can be misleading in absence of a high index of suspicion [2]. As pregnancy advances tubal pregnancies may diminish in size or eventually lead to tubal rupture. The aetiology of ectopic pregnancy is unclear but the ectopic pregnancy arising from reproductive or contraceptive failure may be considered as separate entity with differing risk factors and reproductive outcomes [3]. Prior tubal pregnancy or prior tubal pregnancy is the most important risk factors for tubal ectopic pregnancy [4]. Extrauterine pregnancy may be asymptomatic (intact tubal pregnancy) or it may present with pelvic pain or it may worsen on one side i.e. tubal abortion or with severe hemorrhagic shock (tubal rupture) [5]. Treatment includes salpingectomy may be laparoscopic or lapotomy, methotrexate a folic acid antagonist which is generally used for medical management of in patients [6].

## CASE PRESENTATION:

A 26 years old female patient was admitted to the hospital with chief complaints of lower abdominal pain, continuous per vaginal bleeding and vomiting one episode and loose motions two episodes since one day. Laboratory investigations: haemoglobin: 8.0 gm%, RBCs: 3.1 million/cu.mm, WBC: 11000/cu.mm, neutrophils: 9,240/mm<sup>3</sup>, lymphocytes: 1100/mm<sup>3</sup>, platelets were adequate and RBC is in microcytic and hypo chromic presence. Ultrasonography of abdomen and pelvis demonstrated "irregular heterogenous lesion in the right adnexa and mild free fluid with floating internal echoes in pelvis—possibly tubal ectopic pregnancy with hemoperitoneum". Urine for pregnancy was found to be positive. ECG demonstrated slight ST depression. Vitals include: BP: 100/60mm/Hg, pulse rate: 89b/m, respiratory rate: 25/minutes. Immediately after admission, based on USG abdomen and pelvis report and complaints of the patient surgery was planned. Laparoscopic salpingectomy was done. Before initiation of surgery the patient was given nothing by mouth and injection cefpodoxime 1g was given twice daily, injection pantoprazole 40mg twice daily, injection tramadol twice daily was given. IV fluids include NS 2 pints, DNS 1 pint, RL 1 pint

was given. Immediately after surgery 1 pint blood transfusion was done and injection pheniramine maleate 1 ampoule was given. On day two, 2 pints blood transfusion was done and injection calcium gluconate 1 ampoule was started. Tramadol was stopped on 1<sup>st</sup> post operative day and everything was fine. On 2<sup>nd</sup> post operative day the patient complained of abdominal pain. All the medications which were given previously were stopped and freshly new medications were started which includes: injection cefoperazone sodium+sulbactam 1gm twice daily, injection amikacin 250mg twice daily, injection pantoprazole 40mg twice daily, injection tramadol intramuscularly twice daily, injection vitamin K twice daily and IV

fluids were continued as previous. The patient was recovered and discharged and was advised to review after 10 days.



**Figure 1: USG scan of abdomen and pelvis demonstrating irregular heterogenous lesion in the right adnexa and mild free fluid with floating internal echoes in pelvis—possibly tubal ectopic pregnancy with hemoperitoneum.**

#### DISCUSSION:

Ruptured tubal ectopic pregnancies are uncommon relatively in primary care. Ectopic pregnancy is generally defined as a conceptus implanting outside the uterine endometrium most commonly in the fallopian tube as in the present case [3]. It is a leading cause of maternal mortality. Tubal rupture may occur when the size of pregnancy becomes too large to be accommodated by narrow lumen of the fallopian tube [7]. Sometimes as the pregnancy advances tubal pregnancies may either spontaneously resolve or diminish in size or may also increase in size eventually leading to rupture of the tube as in the present case. In the present case the rupture of the tube and hemoperitoneum has been observed in the USG abdomen and also the patient has complained of continuous vaginal bleeding and lower abdominal pain which is the result of ruptured tube. So immediately the patient was subjected to laparoscopic salpingectomy to prevent any further complications. The patient presented with the lower abdominal pain which is the most severe and the constant symptom in tubal pregnancy which is the result of stretching of the tube wall. [8]. Due to the

rupture of the tube severe and continuous vaginal bleeding occurred which resulted in anaemia. So the patient was transfused with 3 pints of fresh blood. Early diagnosis and treatment is important to prevent any complications in ectopic pregnancy.

#### **CONCLUSION:**

Rupture of the tube in ectopic pregnancy is more commonly observed in women with a history of previous ectopic pregnancy or in women with full term pregnancy. It is one of the major complications of pregnancy. Hence immediate diagnosis and early treatment may help in the prevention of further complications.

#### **CONFLICT OF INTEREST:**

Declared none

#### **ABBREVIATIONS:**

DNS: Dextrose Normal Saline

NS: Normal Saline

RL: Ringer Lactate

ECG: Electrocardiogram

#### **REFERENCES:**

1. Zeek W, Kelters I et al.2007.Lessons learned from four advanced abdominal pregnancies at an East African Health Center. *J. Perinat Med.*2007;9(1):278-81
2. Leelavathi M, Tong SF. et al.2006. A case of tubal ectopic pregnancy. *Malaysian Family Physician.* 1(1):25-26.
3. Dr.vinod kumar.2015. Tubal ectopic pregnancy.*BMJ clin Evid.* 1406.
4. Ankum WM, Mol BW.1996. Risk factors for ectopic pregnancy: a meta-analysis. *Fertil Steril.* 65: 1093-1099.
5. Florin Andrei Taran, Karl – Oliver kagan. et al.2015. The diagnosis and treatment of ectopic pregnancy. *Deutsches Arzteblatt International.* 112(41):693-701.
6. Jackie I Tay, Judith Moore et al.2000. Ectopic Pregnancy. *Western Journal of Medicine.* 173(2):131-1
7. Gregory Latchaw, peter takacs et al.2005. Risk Factors Associated with the Rupture of Tubal Ectopic Pregnancy. *Gynecologic and Obstetric Investigation.*60:177-180.
8. C.P.Douglas. 1963.Tubal Ectopic Pregnancy. *British Medical Journal.*