

“Role of Chhaya avam Vikiran Vigyan (Radiology and Imaging) in diagnosis of Anorectal disorders”

Saxena Varsha*

Assistant Professor, Department of Shalya-Tantra, Main campus, Uttarakhand Ayurveda University,
Dehradun, Uttarakhand.

ABSTRACT

The Anorectal diseases have been known from thousands of years. *Acharya Sushruta*, the great surgeon of India gave a list of Anorectal disorders, where he discussed the normal function of *Apanavayu* in chapter of *Vatavyadhi*. Ayurvedic literature of anorectal diseases have been described as *Bhagandara* (Fistula in ano), *Arshas* (Haemorrhoids), *Nadivrana* (Pilonidal sinus) and *Gudabhramsas* (Rectal prolapse). In *Ayurveda* diagnosis of these diseases is based on sign and symptoms. A full clinical history and diagnostic imaging techniques are very useful to gain information about type of Anorectal diseases and to rule out associated conditions. In *Trividha Pareeksha* (3 fold examination) of *Ayurveda*, *Darshan Pariksha* is one of them and may do with many tools like *Nadi Yantra* etc. The *Vikiran Avum Chhaya* (Radiology and Imaging), the most efficient and non-invasive diagnostic area, is also a tool for *Darshan Pariksha*. Today Radiology and Imaging techniques used for diagnosis of Anorectal diseases is mainly Plain X-ray, Fistulogram /Sinogram, Trans rectal/Endoanal Ultrasonography (TRUS), CT fistulography, MRI and Anorectal Manometry. X-ray procedure done to view an abnormal passage (fistula/sinus) between two or more organs is called as Fistulogram or Sinogram. This technique is minimal invasive, less expensive and provides as accurate representation of anal and rectal anatomy. It is used for staging of both benign and malignant anorectal diseases. CT fistulography and MR imaging have their respective advantages for the preoperative evaluation of perianal fistulas and can be applied when necessary. Anorectal manometry is useful to assess sphincter functions.

KEYWORDS: Anorectal diseases, Fistulogram, Trans rectal/Endoanal Ultrasonography (TRUS), *Darshan Pariksha*.

Introduction:-

The Anorectal diseases have been known from thousands of years. The ancient surgeons and physician due to their importance has described these diseases with various complications in separate chapters. These diseases are collectively found in modern literature but not available in ancient *Ayurveda* at one place. However few diseases of this group have been scattered in Ayurvedic literature. Few of them have been described as complications with some diseases. Sometimes associated symptoms are localized like bleeding per rectal, protruding mass, pus discharge, itching, pain etc. *Acharya Sushruta*, the great surgeon of India gave a list of Anorectal disorders, where he discussed the normal function of *Apana vayu* in chapter of *Vatavyadhi*^[1]. Anorectal region is that anatomical part of the body which excretes excreta. Due to being gate of excreta it always carries infectious materials. It possess problem in surgery of this part because even without eating, glands of GIT remain active, and its secretion again passes to Anorectal region. *Ayurvedic* literature of anorectal diseases have been described as *Bhagandara* (Fistula in ano), *Arshas* (Haemorrhoids), *Nadivrana* (Pilonidal sinus), *Gudabhramsas* (Rectal prolapse), *Sanniruddha Gud*, *Ahiputna*, *Gudpaka*, *Charmakila* and *Lalita*. Now *Kshara Sutra* therapy has been accepted globally as a gold standard treatment for many anorectal diseases^[2]. The *Kshara Sutra* treatment of fistula-in-ano is now found a place in the text books of colorectal surgery. The Indian Council of Medical Research (ICMR) has validated this unique and effective approach.^[3]

In *Ayurveda* diagnosis of these diseases is based on sign and symptoms. A full clinical history and diagnostic imaging techniques are very useful to gain information about type of Anorectal diseases and to rule out associated conditions. *Acharya Charaka* has stated that the purpose of clinical examination is to determine the line of treatment ^[4]. In *Ayurvedic* texts several methods of examination of the patient are described. But *Trividha Pareeksha* (3 fold examination) is most popular, rational and important part of these examinations, which is usually adopted first^{[5] [6] [7]}. *Trividha Pareeksha* (3 fold examination) of a patient is carried out as per following three steps:

1. *Darshana Pareeksha* (Visual observations i.e. Inspection)
2. *Sparshana Pareeksha* (Observation of Touch i.e. Palpation)
3. *Prashna Pareeksha* (Interrogation i.e. Case History).

Darshan Pariksha can be done with many tools like *Nadi Yantra* etc. The *Vikiran Avum Chhaya* (Radiology and Imaging), the most efficient and non-invasive diagnostic area, is also a tool for *Darshan Pariksha*. The basic purpose of Radiology was already in existence in *Ayurveda*. Today Radiology and Imaging techniques used for diagnosis of Anorectal diseases is mainly Plain X-ray, Fistulogram /Sinogram, Trans rectal/Endoanal Ultrasonography (TRUS), CT Scan, MRI and Anorectal Manometry. Plain X ray of pelvis is useful in detecting abscess located in perianal and gluteal area. A x-ray procedure done to view an abnormal passage (fistula/sinus) between two or more organs is called as Fistulogram or Sinogram. Transrectal ultrasonography (TRUS) is one of the best diagnostic and therapeutic imaging techniques. It is a popular imaging modality for evaluating the lower rectum, anal sphincter, and pelvic floor in patients with various anorectal diseases. The primary importance of magnetic resonance (MR) imaging is not only for diagnosis of anal fistulas but also demonstrate hidden areas of sepsis and secondary extensions in patients with fistula in ano. Computed tomography (CT) fistulography has played a limited role in imaging fistula in ano, largely owing to its poor resolution of soft tissue.

Radiology and Imaging for Ano rectal diseases: - Radio graphic techniques useful in the diagnosis of Anorectal diseases are ^[8]:-

1. Plain X-ray
2. Fistulogram/Sinogram
3. Trans rectal Ultrasonography (TRUS)
4. CT Scan
5. MRI
6. Anorectal Manometry

1. Plain X-ray:-

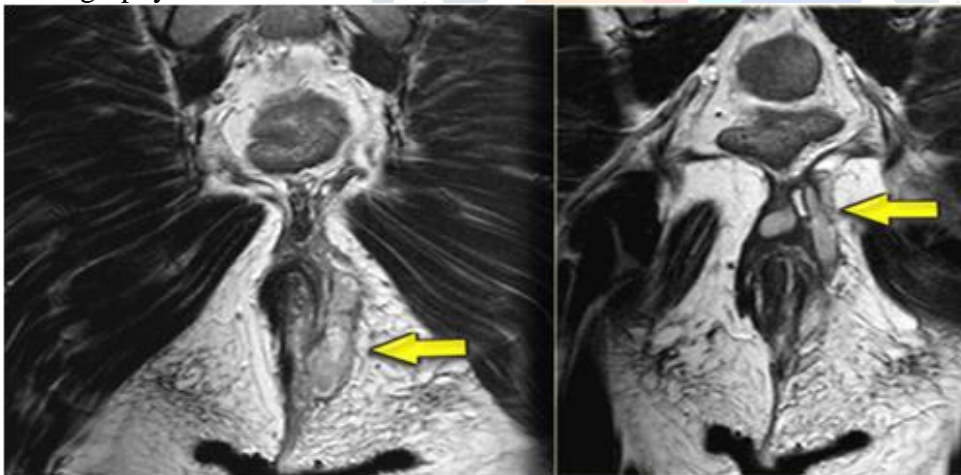
For the confirmation of fistula in ano radiographs are taken to exclude the pathological condition like osteomyelitis and tuberculosis. Chest X ray are also useful to detect pulmonary tuberculosis. But rarely the plain X ray of pelvis is useful in detecting abscess located in perianal and gluteal area. Normally there is presence of gas in rectum, stomach and loop of small bowel which can be seen as dark shadow. **(Figure-1)**

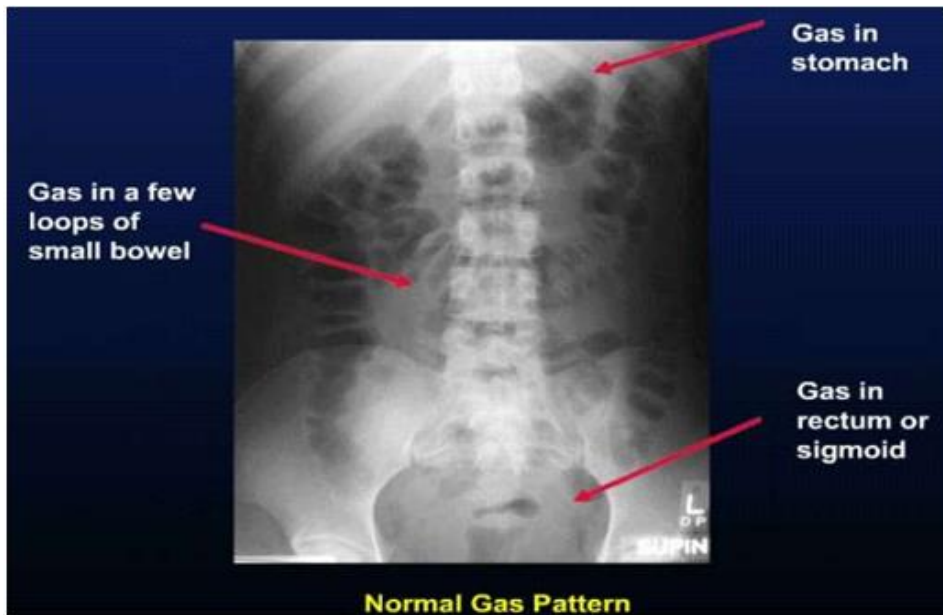

Figure-1 (Gas in stomach, rectum and loops of small bowel) (Source: www.slideshare.net)

2. Fistulogram/Sinogram:

A Sinogram or Fistulogram is a x-ray technique to view an abnormal passage (sinus/fistula) between two or more organs. It may include a passage from internal of the body to an external opening on the skin. Contrast (X-ray dyes) is used to identify the start of the fistula/sinus, its pathway and what organs are involved. This procedure is likely to cause the incidence of inflammation. But Deshpande and colleagues (BHU, 1974) used a technique using a double contrast method for fistulography, used widely by the practitioners of *Kshara sutra* therapy and these techniques has many advantages over the conventional fistulography.



(Figure: 2 Perianal fistulas (Source: <http://www.radiologyassistant.nl>)

▪ Deshpande technique of Fistulogram:

This modified technique was developed by Professor P.J Deshpande (former Head, department of *Shalya tantra*, Institute of medical sciences, Banaras Hindu university-1974). In this technique, a rubber catheter is used with a pump at one end and at the other end a condom is tied. A movable metallic marker is placed below the condom. The end tied with condom is lubricated and pushed inside the anal canal such that the condom is placed into the rectum and the lead marker is at the anal orifices. Then, air is inflated inside the condom and the air gives a better view of the track and branches in relation to rectum and anal canal.

▪ Conventional Fistulogram:

Radio-opaque, contrast agent is injected into the sinus track with the help of syringes and serial radiographs are taken. But this technique has shown some disadvantages in comparison in Deshpande technique which are mentioned in table-

Features	Conventional Fistulogram	Deshpande Fistulogram
▪ Anal canal and rectum	Difficulty to identify	Easy to identify
▪ Radio opaque contrast	Only Radio opaque contrast is used	Only Radio opaque contrast and air are used.
▪ Marker	Not used	Used for anatomical landmarks
▪ Cavity identification	Difficult to assess	Assessment is possible
▪ Internal opening	Sites cannot be assessed	Sites can be identify
▪ Assessment of high and low anal fistula	Difficult to assess	Easily assess
▪ Fistula with multiple opening	Difficult to assess	Easily assess
▪ Blind external fistula	Difficult to assess	Easily assess
▪ Communication with a nearby structure	Not possible	Easily detect

Complication of Fistulogram: Common complication following fistulogram is -

- Local discomfort.
- Infection
- Fistulous abscess
- Portal pyemia (rare, but serious complication)

3. Trans rectal Ultrasonography:-

Transrectal ultrasonography (TRUS) is one of the best diagnostic and therapeutic imaging techniques. It is a popular imaging modality for evaluating the pelvic floor, lower rectum, and anal sphincter in patients with various anorectal diseases [9]. This technique is minimal invasive, less expensive and provides an accurate representation of anal and rectal anatomy. It is used for staging of both benign and malignant anorectal diseases and it has emerged as the primary method for imaging of anal fistula as it gives diagnostic accuracy ranging from 63%-94% for classification of the primary track and gives an accurate predictions of internal opening. Before doing 3D Endo-anal USG, careful inspection of the perianal region is to be done followed by digital examination of the anal canal. Areas of tenderness, discoloration or external drainage are noted. Bowel preparation and rectal cleaning is necessary. It does not allow the imaging of gluteal region and is difficult to perform in acute perianal inflammatory conditions.

3.1 Advantages of 3D Transrectal ultrasonography (TRUS):

It sees all layers of rectal layers and assesses the extent of anal sphincter damage. It accurately diagnose fistula, perianal abscess, fecal incontinence, carcinoma of anal canal and rectum, rectal prolapsed and solitary rectal ulcer syndrome. This technique determines the depth of penetration of carcinoma of the anal canal and rectum into the sphincter complex and can be used for response of these tumors to chemo radiation therapy. TRUS is a safe imaging modality for the appraisal of tumor invasion and lymph node metastasis in rectal cancer patients.

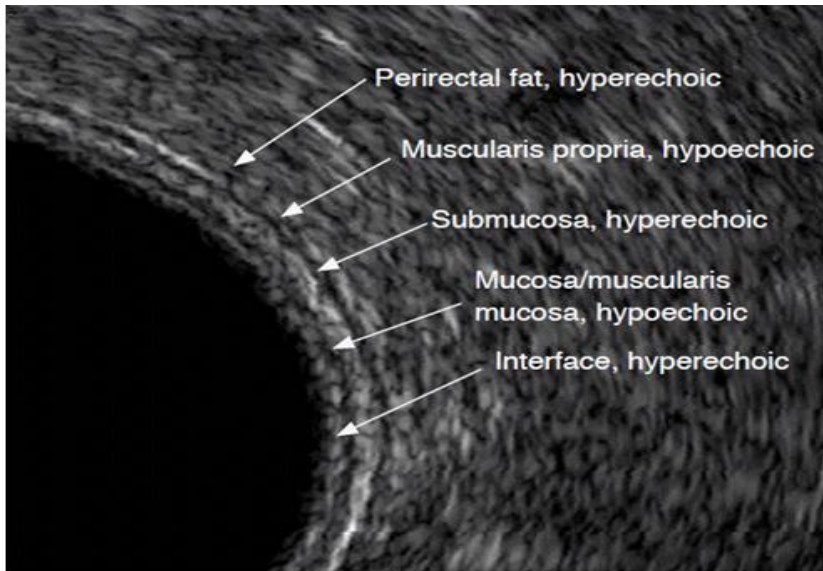


Figure:-3 Normal rectal wall layers in USG (Source:ultrasonography.org)

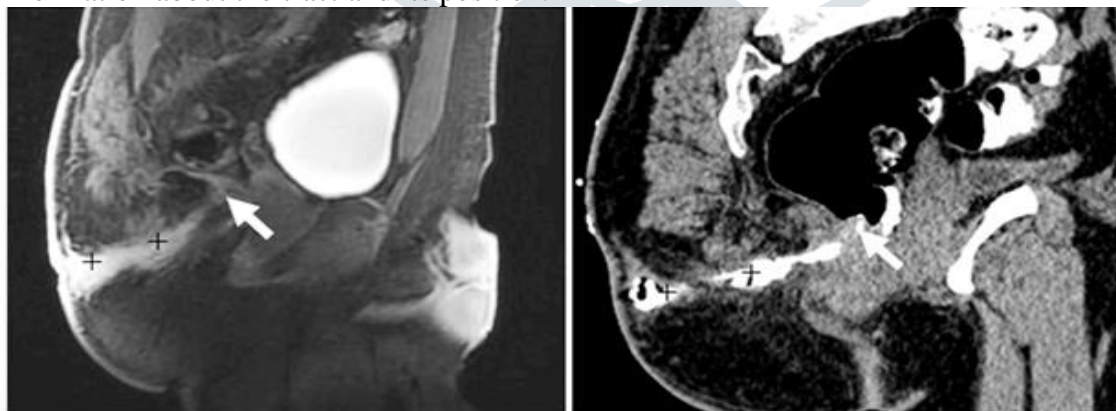
There are many advantages and disadvantages of TRUS compared with magnetic resonance imaging (MRI) for the accurate assessment of anorectal diseases. Such as –

3.2 Role of MRI and TRUS in Rectal Prolapse^[10]:-

Factors	MRI	TRUS
Anatomical location	Good	Excellent
Tissue resolution	Excellent	Good
Early stage of carcinoma	Poor	Good
Infiltration of levator muscle	Good	Moderate
Infiltration of anal sphincter	Moderate	Good
Contraindication	Metal implants	No contraindication

4. CT Fistulogram:-

It is specialized techniques in which modified form of X-Ray is used and organ can be viewed in different levels in the form of slices. This technique is inferior to MRI, endoanal ultrasonography and transcutaneous perianal USG for assessment of fistula in ano. But it may be helpful in detecting the perianal abscess and bone involvement. Virtual CT Fistulogram can provide more accurate information about the tract and its position.



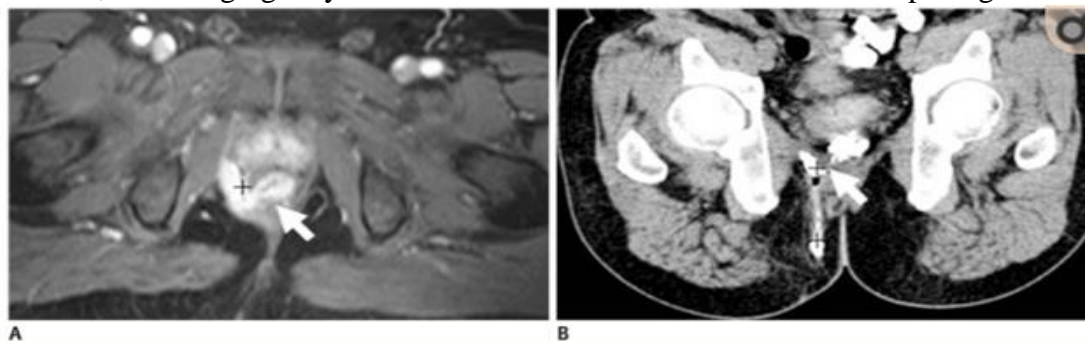
(Figure - Extrasphincteric fistula MRI (Figure- Extrasphincteric fistula CT Fistulography)

(Source: www.semanticscholar.org)

5. Magnetic resonance imaging (MRI):-

Magnetic resonance imaging is regarded as investigation of the choice to define complex anorectal sepsis and fistulae. It defines the presence of fistula, site of extension, the anatomy of the primary track, sepsis without fistula, scar tissue and blind fistula without internal opening. It helps to detect

outlining in primary and secondary sinus tracks. When the opening fails to fill with the contrast material, MR imaging may be the best choice to visualize the internal opening.



(Figure A- Perianal complex fistula (MRI) (Figure B- Perianal complex fistula (CT Fistulography) (Sources: www.ncbi.nlm.nih.gov)

6. Anorectal Manometry:-

Anorectal manometry is an important investigation in anorectal disorders. Anorectal manometry is equipment which provides useful information regarding function of anus and rectum. This test is performed for –

- Sensation in the rectum
- Length of anal canal
- Tone of anal sphincter muscles.

Anorectal manometry is mandatory to assess sphincter functions before the *Kshara sutra* treatment as well as after treatment.

Discussion and Conclusion:-

Anorectal disorders are a group of medical disorders that occur at perianal and the junction of the anal canal and the rectum. These disorders are commonly encountered in general surgical practice. Patients with anus and rectum diseases are some of the most dependent people in the world. Anorectal disorders are very common, but most patients do not seek medical attention so their prevalence seen in clinical practice is probably much lower than that in the general population. These disorders affect men and women of all ages. The spectrum of Anorectal disorders ranges from benign and irritating (pruritus ani) to potentially life-threatening (anorectal cancer). There are so many diseases of anorectal region such as Fistula in ano, Haemorrhoids, Pilonidal sinus and Rectal prolapsed

In *Trividha Pareeksha* (3 fold examination) of *Ayurveda*, *Darshan Pariksha* is one of them and may do with many tools like *Nadi Yantra* etc. The *Vikiran Avum Chhaya* (Radiology and Imaging), the most efficient and non-invasive diagnostic tool, is also a tool for *Darshan Pariksha*. Today Radiology and Imaging techniques used for diagnosis of Anorectal diseases is mainly Plain X-ray, Fistulogram /Sinogram, Trans rectal/Endoanal Ultrasonography (TRUS), CT fistulography, MRI and Anorectal Manometry. CT fistulography and MR imaging have their respective advantages for the preoperative evaluation of perianal fistulas and can be applied when necessary. These modalities of investigation may improve the surgeon's knowledge regarding the morphology of the fistulas and help in even more complicated surgery on safer side. TRUS provides excellent visualization of the layers of the rectal wall. It is an accurate and useful tool for determining rectal wall integrity and staging primary rectal cancer. It is a fast and minimum invasive technique performed in outdoor also. TRUS also help in assessment of anal sphincter and provide significant information helpful for planning of treatment of perianal fistulas and fecal incontinence^[11]. TRUS is better than MRI for the evaluation of superficial tumors, whereas MRI provides a better visualization of locally and advanced cancers. Deshpande and colleagues (BHU, 1974) used a techniques using double contrast method for fistulography, which is used widely by the practitioners of *Kshara sutra* therapy^[12]. Anorectal manometry is useful to assess sphincter functions.

Source of support- Nil

Conflict of interest- None Declared

References:-

1. **Sushruta. Sushruta samhita**, English translation by Sharma P.V, Vol II, *Nidan-sthan* (1:19-20), Chaukhambha Vishvabharati , Varanasi. (2005)
2. **Sahu. M:** A Mannual on Fistula in Ano and Ksharasutra therapy. First edition 2015, vol 1, issue-1, published by National resource Centre on *Ksharsutra* therapy 2015.
3. **Multicentric randomized controlled**, clinical trial of *Ksharasutra* (Ayurvedic medicated thread) in the management of fistula-in-ano. Indian Council of Medical Research.Indian J Med Res. 1991 Jun; 94():177-85.
4. **Agnivesha.** Charaka samhita , English translation by Sharma RK, Dash B. Vol-1, *Viman Sthan*(8:32),Chaukhambha Sanskrit series office, Varanasi. (2010)
5. **Vagbhata** .Astanga Hriday, English translation by SrikanthaMurty KR, Vol-I, *Sutra sthana* (1:22) Chaukhambha, Krishnadas Academy Varanasi. (2015)
6. **Agnivesha.** Charaka samhita , English translation by Sharma RK, Dash B. Vol-11, *Chikitsa Sthan* (25:22),Chaukhambha Sanskrit series office, Varanasi. (2010)
7. **Sushruta. Sushruta samhita**, English translation by Sharma P.V, Vol II, *Sutra-sthan* (10:5), Chaukhambha Vishvabharati , Varanasi. (2005)
8. **Sahu M.** A Mannual on Fistula in Ano and *Kshara Sutra* Therapy. 1st ed., Vol. 1. Varanasi, India: National Resource: Centre on *Kshara Sutra* Therapy; 2015.
9. **Engin G.** Endosonographic imaging of anorectal diseases. J Ultrasound Med 2006;25:57–73
10. **Changhu Liang, Yongchao Lu, Bin Zhao, Yinglin Du, Cuiyan Wang, Wanli Jiang:** Imaging of Anal Fistulas: Comparison of Computed Tomographic Fistulography and Magnetic Resonance Imaging Korean J Radiol. 2014 Nov-Dec; 15(6): 712–723. Published online 2014 Nov 7. doi: 10.3348/kjr.2014.15.6.71
11. **Min Ju Kim:** Transrectal ultrasonography of anorectal diseases: advantages and disadvantages; Ultrasonography 2015; 34(1): 19-31. <https://doi.org/10.14366/usg.14051>
12. **Sahu M.** A Mannual on Fistula in Ano and *Kshara Sutra* Therapy. 1st ed., Vol. 1. Varanasi, India: National Resource: Centre on *Kshara Sutra* Therapy; 2015.