



TITLE: AN AYURVEDIC MANAGEMENT OF SHOSHA ROGA (COLLAPSED LUNG) – A SINGLE CASE STUDY

**Author: Dr. Ravina More¹, Dr. Alpesh Munjani², Dr. Anamika S. Soni³,
Prof. Dr. Surendra A. Soni⁴**

1. PG Scholar, Department of Kayachikitsa, Government Akhandanand Ayurveda College and Hospital, Ahmedabad.
2. PG Scholar, Department of Kayachikitsa, Government Akhandanand Ayurveda College and Hospital, Ahmedabad.
3. Associate Professor, Kayachikitsa department, Government Akhandanand Ayurveda College and Hospital Ahmedabad.
4. HOD, Department of Kayachikitsa, Government Akhandanand Ayurveda College and Hospital Ahmedabad.

ABSTRACT

A collapsed lung is a condition in which the air sacs in the lungs collapse and do not expand properly. Its also called "atelectasis". Atelectasis refers either to incomplete expansion of the lungs (neonatal atelectasis) or to the collapse of previously inflated lung, producing areas of relatively airless pulmonary parenchyma¹. In Ayurveda, atelectasis can be understand as *shosharoga* with specific involvement of *Pranavaha Srotas*. In this case study a 60 year old female patient previously diagnosed with Collapsed lung since 1 year along with history of DM, Hypertension, Pulmonary Tuberculosis and COVID-19. She came for ayurvedic treatment in Govt. Akhandanand Ayurveda college & hospital, Ahemdabad. Patient was treated the principles of treatment mentioned for *shosha roga* in Ayurveda according to predominance of *dosha* and *dushya*, with principles of *Deepana-Pachana*, *Snehana*, *Vata anulomana*, *Srotoshodhana*, *Laghu-Sanatarpan* and *Brihan* of weakened *Dhatu* (body tissues) as well as *Rasayana* (Immunobooster) drugs were administered. With the help of above mentioned treatment principle the patient got remarkable relief symptomatically as well as in laboratory findings, X-ray and other investigation, which is quite encouraging.

KEY WORDS

Collapse lungs, *Shosha*, *Kshaya*, *Shamana chikitsa*, *Rasayana*

INTRODUCTION

Collapse or atelectasis means airlessness or a loss of volume in the lung, lobe or segment from any cause. It may be obstructive due to occlusion of bronchus to the involved area, or may result from contraction due to chronic inflammation and fibrosis². Common causes are mucus plug, foreign body and tumor in airways, Injury or chest trauma, complication of anaesthesia, narrowing or blockage of major airways, Asthma, Lung cancer, Pneumonia, Pleural effusions, Pneumothorax etc. The characteristic symptoms of collapsed lung are Cough, breathlessness, chest pain, haemoptysis, pleural effusion and respiratory failure etc.

In Charaka Samhita *nidana* and *chikitsa sthana*, Acharya mentioned *shosha roga*³. In this article collapsed lung is correlated with *shosha roga* because *shosha* is one of major disease in which involvement of all *dhatu*s and mainly *pranavahasrotas* respectively with vitiated *Vata*. The classification of disease according to the involved *nidana* is divided as *Sahasajanya*, *Vega Sandaranajanya*, *Vishamashana janya shosha* and *Kshaya janya shosha*⁴ i.e. dries up *rasadidhatu*, called as *kshaya*.

Various physiological activities are constantly performed in the body like respiration, circulation and digestion. In *shosha*, those activities affected and gradually decreases, i.e. “*Kshaya*” of *Rasadidhatu*s. When the *Rasavahasrotas* obstructed vitiated *Dosha* where *Vata* is predominant or in person who gets indulged in excessive sexual activity leading to *Shukrakshaya* and all other *Dhatu*s undergoes in deficiency, making the person too much emaciated. The prevalence of disease is alarmingly increasing. Ayurveda has a number of formulations to treat this condition according to *Roga-Rogi bala* and is in practice with proven efficacy. The goal of Ayurveda treatment is not merely treating the symptoms of diseases, but also entire wellbeing in the health. In this clinical study, *Shamana chikitsa* has been adapted to a female patient aged 60 years for 1 year and got better results from symptoms related to collapsed lung.

CASE REPORT

A female patient aged 60 years old came to Kayachikitsa OPD Government Akhandanand Ayurveda Hospital, Ahmedabad with the complaints of *Shushka Kasa* (Dry coughing), *Swasakruchhata* (breathlessness), *Vama-parswashoola* (Left lateral side chest pain), *Rakta-shthivana* (Haemoptysis), *Daurbalaya* (Weakness), *Kshudhanash* (Anorexia) since last 1 year. She has taken allopathy treatment for a month but got no relief.

K/C/O Diabetes mellitus, Hypertension, Hypothyroidism since 8 years

PAST HISTORY – Pulmonary tuberculosis in 2009 – taken AKT
Pneumonia in 2010
Covid infection in 2019-20 (2 times) – taken Ayurvedic treatment

FAMILY HISTORY- no any relevant family history

PERSONAL HISTORY

Diet- Veg, *Madhura rasa pradhana*, Irregular timing
Sleep- Disturbed
Appetite- Poor
Bowel- 1-2 times/day (unsatisfactory)
Micturition- 5 to 6 times/day, 1-2times/night
Allergy- allergic to dust
Addiction- Nil

GENERAL EXAMINATION

Blood pressure- 130/84mmhg
Pulse- 86/min
Respiratory rate- 20/min
Temperature-98.6° F

SYSTEMIC EXAMINATION:**TABLE 1: Respiratory System Examination**

INSPECTION	Chest wall is Flattened on left side Movement of chest wall is diminished over left lung
PALPATION	Trachea and mediastinum shifted towards the left side
PERCUSSION	Dull Note over upper lobe of left lung
AUSCULTATION	Absent breath sounds on left supraclavicular and infraclavicular and axillary region.

TREATMENT PLAN

The Patient was treated in the out patient department. The treatment begin from first visit of the patient in the OPD. The treatment was continued for 8 months with every 14 days of follow up. The treatment given is as follows:

TABLE 2: (Treatment Chart)

Treatment	Medicine	Time	Anupana
Internal	<i>Talisadichurna</i> 3gm + <i>Tankan bhasma</i> 500mg + <i>Sphatik bhasma</i> 125mg + <i>Abhrak bhasma</i> 125mg	2 times/day	<i>Koshna Jala</i>
	<i>Bhargiyadi kwath</i> 10gm + <i>Pathyadikwath</i> 10gm with + <i>Vasa churna</i> 5gm + <i>Yastimadhu churna</i> 5gm + <i>Kalmegha churna</i> 5gm	2 times/day	<i>Koshna Jala</i>
	<i>Yastimadhu ghanvati</i> 500mg (1 tab)	4 times/day	
	<i>Mahalaxmivilas rasa</i> 125mg (1 tab.)	2 times/day	
	<i>Go ghris</i> 2tsp (10ml)	Morning (empty stomach)	
External	Local <i>Abhyang Swedan</i> (chest region): by <i>Tila taila</i> + <i>Saindhav lavana</i>		

RESULTS

The Patient is symptomatically improved. The Subjective parameter shows improvement in the clinical symptoms.

TABLE 3: (Subjective Parameter – Before and after treatment)

SIGN & SYMPTOMS	BEFORE TREATMENT Date of starting (05/07/2022)	AFTER TREATMENT Date of last follow up (07/03/2023)
<i>Shushka Kasa</i> (Dry coughing)	++++	+
<i>Swasakruchhata</i> (Breathlessness)	+	-
<i>Vama-parswashoola</i> (Left lateral side chest pain)	++++	+
<i>Rakta-shthivana</i> (Haemoptysis)	+	-
<i>Daurbalaya</i> (Weakness)	+++	-
<i>Kshudhanash</i> (Anorexia)	++	-

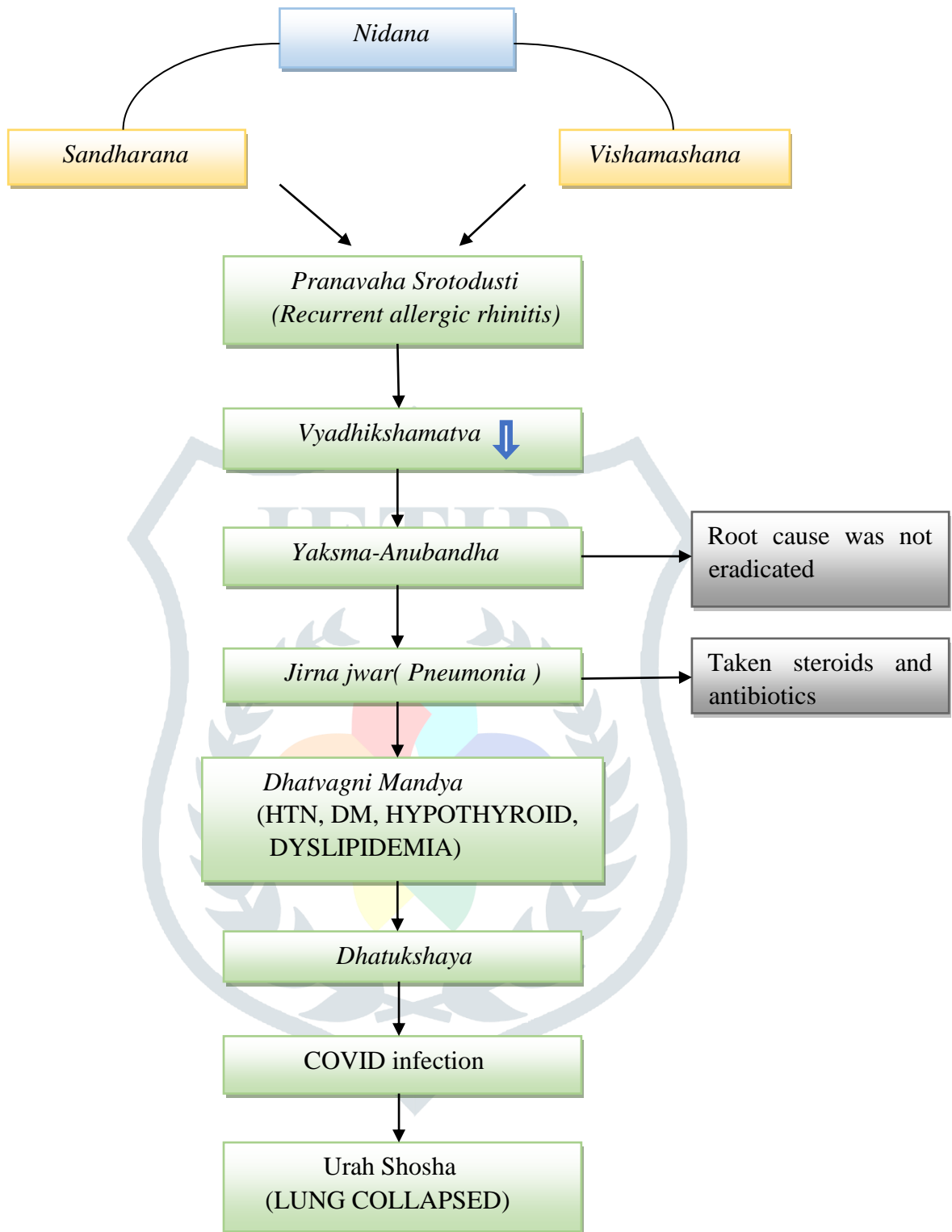
RADIOLOGICAL EXAMINATION-**TABLE 4: X-RAY CHEST-PA VIEW ON GIVEN DATE**

DATES	REPORTS
03/06/2022 (BEFORE TREATMENT)	Right lung field shows prominent brocho-vascular markings with hyperinflation. Complete collapse of left lung with shifting of mediastinum to left side with bronchiectatic areas in left upper zone. Shifting of trachea to left side is noted. Cardiac shadow appears partially obscured.
07/03/2023 (AFTER TREATMENT)	Brochiectatic with cavitary destruction with marked volume loss with haziness of left lung is noted. Resultant shifting of mediastinum to left side. Hyperinflation of right lung is noted.

DISCUSSION

Avoiding etiological factors is primary line of treatment in any disease. In this case, day sleep, suppression of natural urges of urine and stool, faulty diet habits, Past infections of TB and Pneumonia are found as etiological factors.

Samprapti can be understood as shown in chart:



SAMPRAPTI GHATAK

Dosha- Kapha pradhan tridosha

Dushya- Rasa, Rakta, Mamsa, Meda, Asthi, Majja, Shukra

Srotas- Prana, Anna, Rasa, Rakta, Mamsa, Meda, Asthi, Majja, Shukra

Srotodusti- Atipravtti, Sanga, Vimarggaman, Granthi

Rogamarga- Madhyam

Agni- Manda

Dhatwagni- Manda

Samata- Sama

Adhistan- Sharir and Manshik

Udbhavsthan- Amashya samuttha

Vyaktisthan- Urahpradesh

Swabhav- Chirkari

Sadhyaasadyata- Kruccha sadhya

The treatment principle applied for the management of this disease condition are based on the principles of *Shosha roga chikitsa* with *Agnideepan*, *Snehan*, *Vata anuloman*, *Srotovishodhan* and *Vata-kapha shamana* pacifying treatment. The probable mode of action of these medicines can be explain as follows:

Talishadi choorna:

The effect of *Talishadi choorna* in copious expectoration in every bouts of cough and useful in counteracting the pathology. It acts through all ingredients (*Talishapatra*, *Maricha*, *Shunthi*, *Pippali*, *Vamsalochana*, *ela*, *Twak*, *Sharkara*). *Maricha* stimulate alveolar membrane. *Pippali* and *Shunthi* release the sputum. *Tankan bhasma* is antispasmodic and removes *kapha*.

Goghrita: (In shaman matra)

Snehpana pacifies *Vata dosha* that subsequently cause lubrication of *srotas* (decreases breathlessness). *Sneha* also helps in disintegrating accumulated *Dosha or Mala* from *shakha* to *kostha* for their easy expulsion.

Bharangyadi kwatha:

As the collapse lung is *Vata tridoshaj pradhan* condition with narrowing airless bronchioles. It needs the *dravyas* having *Vata-Kaphaghna* property, *Amapachana*, *Srotoshodhan*, *Agnisandhukshan Karma* i.e. *Deepana-Pachana*. *Shunthi* has anti-allergic property. *Bharangi* is mentioned as *Agyadravya* for *Shwasavyadhi* and has been proven as anti-histaminic, Mast cell stabilizer, Brochodilator. *Pippali* has expectorant, digestive property and mentioned as *Rasayana* for *Pranavahasrotas*. *Pippali* also has anti-allergic effect. This medicine also improves and stimulates immune function.

Mahalaxmivilas rasa:

Composition: *Bhasma*(calcined preparation) of *abhraka*(mica), *Tamra*(copper), *Vanga*(tin), *Mauktik*(pearl), *Suvarna*(gold), *Raupya*(silver) and *Naga*(lead).

Mahalaxmivilas rasa acts as a *Rasayana* specific for *Pranavahasrotas*. It strengthens whole body, especially lungs. It improves the function of airways and lungs. It has *Kasa-Shwasahara* action by its *kaphavata shamaka*, *Srotoshodhan* & *rasayana* properties.

CONCLUSION-

There is a very big scope in Ayurveda for treatment of such critical condition in which there is damage in the structure and function of organs like atelectasis. As per modern medical science, these permanent damage and pathological changes are irreversible but with the Ayurveda treatment it helpful in reversing these permanent pathological damage or changes in many conditions such like atelectasis without producing adverse effects rather patient feels better in general health & quality of life.

REFERENCES:

1. Robbins & Cotran Pathologic Basis of Disease, part 2, chapter 15, page no.670-671
2. Aspi F Golwalla, Sharukh A Golwalla,.Golwalla”s MEDICINE for students, chapter-3, page no.181
3. Agnivesha Charak Samhita Vidyotini hindi commentary by Pandit Kashinath Pandey & Dr. Gorakhnath Chaturvedi published by chaukhambha bharti academy, Charak Samhita Nidanasthana chapter 6, page no.648
4. Agnivesha Charak Samhita Vidyotini hindi commentary by Pandit Kashinath Pandey & Dr. Gorakhnath Chaturvedi published by chaukhambha bharti academy, Charak Samhita Nidanasthana chapter 6, page no. 648, Sholka 3

