DIABETIC RETINOPATHY IMAGE DATABASE(DRiDB): A COMPARISON

Ashima Gambhir
Assistant Professor
Department of Computer Science
Amity University Haryana, India

Abstract: Diabetic retinopathy is one of the main impairing ceaseless sicknesses, and one of the main sources of preventable visual deficiency on the planet. Early determination of diabetic retinopathy empowers auspicious treatment and with a specific end goal to accomplish it a noteworthy exertion should be put into screening programs and particularly into mechanized screening programs. For robotized screening projects to work powerfully a delegate fundus picture database is required. In this paper we give an outline of right now accessible databases and present another diabetic retinopathy database. Our database is as far as anyone is concerned the first and just database which has diabetic retinopathy pathologies and real fundus structures explained for each picture from the database which makes it ideal for outline and assessment of right now accessible and new picture handling calculations for early recognition of diabetic retinopathy utilizing shading fundus pictures.

IndexTerms: Diabetic Retinopathy, Hemorrhages, Exudates, Database.

I INTRODUCTION

Diabetic retinopathy (DR) is one of the leading disabling chronic diseases, and one of the leading causes of preventable blindness in the world [1]. It was found to be the fourth most frequently managed chronic disease in general practice in 2009, and the projections go as high as the second most frequent disease by the year 2030 [1]. The global burden of diabetic patients is expected to rise from 171 million in 2000 to 366 million in 2030 [1]. In Europe more than 52.8 million people are diagnosed with diabetes with the number expected to rise to 64 million by 2030. In Croatia about 300 thousand people are estimated to have diabetes and of those only 190 thousand are registered. Early diagnosis of diabetic retinopathy enables timely treatment that can ease the burden of the disease on the patients and their families by maintaining a sufficient quality of vision and preventing severe vision loss and blindness [2]. In addition to the obvious medical benefits, significant positive economical effects are achieved by maintaining patient's workability and self-sustainability.

Fundus imaging has an essential part in diabetic retinopathy location and checking on the grounds that eye fundus is touchy to vascular ailments and we can consider fundus imaging as a possibility for non-obtrusive screening. The accomplishment of this kind of screening approach relies upon exact fundus picture catch, and particularly on precise and strong picture handling and examination calculations for variations from the norm location. Numerous calculations have been proposed for fundus picture investigation utilizing distinctive techniques and methodologies yet it is some of the time difficult to quantify the exactness and dependability of the proposed calculations on the grounds that no regularly acknowledged and agent fundus picture database exists in general society area.

The principle commitment of this work is to introduce another, entire and freely accessible, diabetic retinopathy database, DRiDB which contains the ground truth information from a few ophthalmological specialists. In Section II regular indications of diabetic retinopathy are clarified. In Section III current best in class diabetic retinopathy databases are introduced. In Section IV comparative analysis of already available databases. In Section V we give a concise conclusion with short discourse about expected future work.

II DIABETIC RETINOPATHY

Diabetes is a notable infection and may cause variations from the norm in the retina (diabetic retinopathy), kidneys (diabetic nephropathy), sensory system (diabetic neuropathy) and is known to be a noteworthy hazard for cardiovascular illnesses. Diabetic retinopathy is a micro vascular entanglement caused by diabetes which can prompt visual deficiency. In beginning periods of diabetic retinopathy regularly there are no noticeable signs yet the number eighth International Symposium on Image and Signal Processing and Analysis (ISPA 2013) September 4-6, 2013, Trieste, Italy Unique Sessions Retinal Image Analysis 711 also, seriousness of irregularities increase during the time. Diabetic retinopathy ordinarily begins with little changes in retinal vessels. The first recognizable variations from the norm are microaneurysms which speak to neighborhood amplifications of the retinal vessels. The cracked micro aneurysms can cause hemorrhages. After a timeframe, hard exudates may show up. The hard exudates are lipid developments spilling from debilitated veins. As the retinopathy progresses, the veins may wind up hindered which causes micro infarcts in the retina. These micro infarcts are called delicate exudates. Broad absence of oxygen caused by micro infarcts causes the advancement of new delicate vessels. This wonder is called revascularization which is a genuine vision undermining state and may cause sudden misfortune in visual keenness or even changeless visual deficiency. Cases of micro aneurysms, hemorrhages, hard exudates, delicate exudates and revascularization are unmistakable. After determination of diabetic

retinopathy, general observing is required because of dynamic nature of the sickness. Unfortunately, expansive screening can't be performed because of the way that fundus picture examination requires therapeutic specialists. For the screening, computerized picture preparing strategies must be created and to create robotized picture handling techniques top notch databases for calculation assessment are required.

Diabetic Retinopathy is mainly categorized into Proliferative Diabetic Retinopathy(PDR) and Non Proliferative Diabetic Retinopathy(NPDR). Figure 1 shows the different stages of Diabetic Retinopathy.

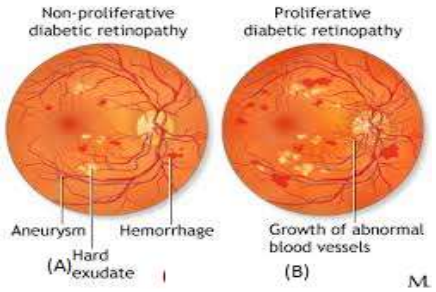

Fig 1 Stages of Diabetic Retinopathy (A) Signs of NPDR (B) Signs of PDR

III PUBLICALY AVAILABLE DATABASES

In this section, an overview of online available fundus images databases including DRIVE, STARE, Messidor, Retinopathy Online Challenge (ROC), Image Ret, HEI-MED.

a. **DRIVE Database**: The DRIVE (Digital Retinal Images for Vessel Extraction) is an openly accessible database, consisting of an aggregate of 40 shading fundus photos [7]. The photos were acquired from a diabetic retinopathy screening program in the Netherlands. The screening populace comprised of 400 subjects in the vicinity of 25 and 90yearsofage.EachimagehasbeenJPEGcompressed, which is normal practice in screening programs. Of the 40 pictures in the database, 7 contain pathology, in particular exudates, haemorrhages and shade epithelium changes. The pictures were gained utilizing a Canon CR5 non-mydriatic 3-CCD camera with a 45◦ field of view (FOV). Each picture was caught utilizing 8 bits for each shading plane at 768×584 pixels. The FOV of each picture was round with a distance across of roughly 540 pixels. The arrangement of 40 pictures was separated into a test and preparing set both containing 20 pictures. Three spectators, the first and second creator and a software engineering understudy physically sectioned various pictures. All eyewitnesses were prepared by an accomplished ophthalmologist (the last creator). The first spectator portioned 14 pictures of the preparation set while the second onlooker divided the other 6 pictures. The test set was portioned twice bringing about a set X and Y. Set X was fragmented by both the first and second spectator (13 and 7 pictures, individually) while set Y was totally portioned by the third eyewitness. The execution of the vessel division calculations was estimated on the test set. In set X the onlookers stamped 577,649 pixels as vessel and 3,960,494 as foundation (12.7% vessel). In set Y 556,532 pixels wew set apart as vessel and 3,981,611 as foundation (12.3% vessel). This database does not contain commented on pathologies and different fundus structures like optic plate and macula.

b. **STARE Database**: The STARE database contains 20 pictures for vein division; ten of these contain pathology [8]. The slides were caught by a Topcon TRV-50 fundus camera at 35◦ field of view. Each slide was digitized to deliver a 605×700 pixel picture, 24 bits for each pixel (standard RGB). Two eyewitnesses physically fragmented every one of the pictures. By and large, the first individual named 32,200 pixels in each picture as vessel, while the second individual named 46,100 pixels in each picture as vessel. A resulting survey demonstrated that the first individual took a more traditionalist perspective of the limits of vessels and in the identification of little vessels than the second individual. Execution was processed with the division of the first spectator as the ground truth.

c. **Image Ret: I**mageRet database was made openly accessible in 2008 and is subdivided into two sub-databases, DIARETDB0 and DIARETDB1 [10]. DIARETDB0 contains 130 retinal pictures of which 20 are typical and 110 contain different indications of diabetic retinopathy. DIARETDB1 contains 89 pictures out of which 5 pictures speak to sound retinas while the other 84 have some diabetic retinopathy signs. The pictures were obtained with a 50◦ FOV utilizing a fundus camera at a size of 1500×1152 pixels in PNG arrange. The pictures were commented on by four specialists for the nearness of Microanurysms, haemorrhages, and hard and delicate exudates. Commented on pictures from four specialists were consolidated to create a solitary ground truth picture. There are no physically sectioned vessel pictures in this database

d. **Messidor**: The Messidor-project database, with 1200 retinal images, is the largest database currently available on the internet and is provided by the Messidor program partners [11]. The images were acquired by 3 ophthalmologic departments using a color video 3CCD camera on a Topcon TRC NW6 non-mydriatic camera with a 45◦ FOV. The images were captured using 8 bits per color plane at 1440×960, 2240×1488, or 2304×1536 pixels. 800 images were acquired with pupil dilation (one drop of Tropicamide at 0.5%) and 400 without dilation. The reference standard provided contains the grading for diabetic retinopathy and the risk of macular edema in each image. This database does not contain any other annotations and is used to facilitate studies on computer-assisted diagnoses of diabetic retinopathy.

e. **ARIA Online**: This database was created in 2006, in a research collaboration between St. Paul's Eye Unit, Royal Liverpool University Hospital Trust, Liverpool, UK and the Department of Ophthalmology, Clinical Sciences, University of Liverpool, Liverpool, UK [9]. The database consists of three groups; the first group has 92 images with age-related macular degeneration, the second group has 59 images with diabetes and the control group consist of 61 images.

f. **Review**: The Retinal Vessel Image set for Estimation of Widths (REVIEW) was made accessible online in 2008 by the Department of Computing and Informatics at the University of Lincoln, Lincoln, UK [12]. The dataset contains 16 mydriatic pictures with 193 commented on vessel fragments comprising of 5066 profile focuses physically set apart by three autonomous specialists. The pictures were surveyed the exactness and accuracy of the vessel width estimation calculations within the sight of pathology and focal light reflex. The 16 pictures are subdivided into four sets, the high determination picture set (HRIS, 8 pictures), the vascular sickness picture set (VDIS, 4 pictures), the focal light reflex picture set (CLRIS, 2 pictures) and the kickpoint picture set (KPIS, 2 pictures).

g. **ROC Microanurysms set**: The Retinal Vessel Image set for Estimation of Widths (REVIEW) was made accessible online in 2008 by the Department of Computing and Informatics at the University of Lincoln, Lincoln, UK [12]. The dataset contains 16 mydriatic pictures with 193 commented on vessel fragments comprising of 5066 profile focuses physically set apart by three autonomous specialists. The pictures were surveyed the exactness and accuracy of the vessel width estimation calculations within the sight of pathology and focal light reflex. The 16 pictures are subdivided into four sets, the high determination picture set (HRIS, 8 pictures), the vascular sickness picture set (VDIS, 4 pictures), the focal light reflex picture set (CLRIS, 2 pictures) and the kickpoint picture set (KPIS, 2 pictures).

h. **HEI-MED:** The Hamilton Eye Institute Macular Edema Dataset (HEIMED) (formerly DMED) is a collection of 169 fundus images to train and test image processing algorithms for the detection of exudates and diabetic macular edema [15]. The dataset is composed of 169 JPEG images compressed at highest quality. Each image of the dataset was manually segmented by Dr. Edward Chaum (an expert ophthalmologist from HEI). He identified all the exudation areas and other bright lesions such as cotton wool spots, drusens or clearly visible fluid occurring on the fundus.

i. **VICAVR:** The VICAVR database is a set of retinal images used for the computation of the A/V ratio [14]. The database currently includes 58 images. The images were acquired with a Topcon NW-100non-my driatic camera and are optic disc centered with a resolution of 768×584. The database includes the calibre of the vessels measured at different radii from the optic disc as well as the vessel type (artery/vein) labeled by three experts.

IV COMPARATIVE ANALYSIS

The introduced review of picture databases demonstrates that there is no database which contains both commented on pathologies like micro aneurysms, haemorrhages, hard exudates, delicate exudates, neovascularisations and typical fundus structures like veins, macula and optic plate. Moreover, a few databases incorporate pictures that were commented on just by a solitary master, which presents the issue of manual comment predisposition. The key highlights of the assessed databases are appeared in Table 1.

Table1: Available Database Comparison

Database	Regular Fundus Structures	Pathologies	Neovascularisation	Multiple experts	Disease Grading	No of Images
DRIVE	No			No		40
STARE	No			No		20
IMAGE RET		No		No		219
MESSIDOR					No	1200
ARIA Online	No			No		212
REVIEW	No			No		16
ROC		No		No		50
HEI-MED		No				169
VICAVR	No			No		58

V CONCLUSION

Diabetic retinopathy, is retinopathy (damage to the retina) caused by complications of diabetes, which can eventually lead to blindness. It is an ocular manifestation of diabetes, a systemic disease, which affects up to 80 percent of all patients who have had diabetes for 10 years or more. Despite these intimidating statistics, research indicates that at least 90% of these new cases could

be reduced if there was proper and vigilant treatment and monitoring of the eyes. In this paper, I have done comparison of different existing databases for Diabetic Retinopathy fundus images. This work will be useful for technical persons and researchers who need to use the ongoing research in this area.

REFERENCES

[1] S. Wild, G. Roglic, A. Green, R. Sicree, and H. King, "Global prevalence of diabetes: estimates for the year 2000 and projections for 2030," Diabetes Care, vol. 27, no. 5, pp. 1047–1053, 2004.

[2] S. J. Lee, C. A. McCarty, H. R. Taylor, and J. E. Keeffe, "Costs of mobile screening for diabetic retinopathy: a practical framework for rural populations," Aust J Rural Health, vol. 9, no. 4, pp. 186–192, 2001.

[3] C. A. McCarty, C. W. Lloyd-Smith, S. E. Lee, P. M. Livingston, Y. L. Stanislavsky, and H. R. Taylor, "Use of eye care services by people with diabetes: the Melbourne Visual Impairment Project," Br J Ophthalmol, vol. 82, no. 4, pp. 410–414, 1998.

[4] D. A. Askew, L. Crossland, R. S. Ware, S. Begg, P. Cranstoun, P. Mitchell, and C. L. Jackson, "Diabetic retinopathy screening and monitoring of early stage disease in general practice: design and methods," Contemp Clin Trials, vol. 33, no. 5, pp. 969–975, 2012. [5] H. C. Looker, S. O. Nyangoma, D. Cromie, J. A. Olson, G. P. Leese, M. Black, J. Doig, N. Lee, R. S. Lindsay, J. A. McKnight, A. D. Morris, S. Philip, N. Sattar, S. H. Wild, and H. M. Colhoun, "Diabetic retinopathy at diagnosis of type 2 diabetes in Scotland," Diabetologia, vol. 55, no. 9, pp. 2335–2342, 2012.

[6] T. Peto and C. Tadros, "Screening for diabetic retinopathy and diabetic macular edema in the United Kingdom," Curr. Diab. Rep., vol. 12, no. 4, pp. 338–345, 2012.

[7] M. Niemeijer, J. J. Staal, M. Ginneken B. v., Loog, and M. D. Abramoff. (2004) DRIVE: digital retinal images for vessel extraction. [Online]. Available: http://www.isi.uu.nl/Research/Databases/DRIVE

[8] A. Hoover, V. Kouznetsova, and M. Goldbaum, "Locating blood vessels in retinal images by piecewise threshold probing of a matched filter response," Medical Imaging, IEEE Transactions on, vol. 19, no. 3, pp. 203–210, 2000.

[9] (2006) ARIA online, retinal image archive. [Online]. Available: http://www.eyecharity.com/doe/aria online [10] T. Kauppi, V. Kalesnykiene, J. K. Kamarainen, L. Lensu, I. Sorri, A. Raninen, R. Voutilainen, H. Uusitalo, H. K¨alvi¨ainen, and J. Pietil¨ a, "DIARETDB1 diabetic retinopathy database and evaluation protocol," Proc Medical Image Understanding and Analysis MIUA, vol. 1, pp. 3–7, 2007.

[11] (2004) MESSIDOR: Methods for evaluating segmentation and indexing techniques dedicated to retinal ophthalmology. [Online]. Available: http://messidor.crihan.fr/index-en.php

[12] B. Al-Diri, A. Hunter, D. Steel, M. Habib, T. Hudaib, and S. Berry, "REVIEW-a reference data set for retinal vessel profiles," Engineering in Medicine and Biology Society,30th Annual International Conference of the IEEE, vol. 2008, pp. 2262–2265, 2008.

[13] M. Niemeijer, "Retinopathy online challenge: Automatic detection of microaneurysms in digital color fundus photographs," IEEE Trans. Med. Imaging, vol. 29, p. 185–195, 2009.

[14] (2010) The VICAVR database. [Online]. Available: http://www.varpa.es/vicavr.html

[15] L. Giancardo, F. Meriaudeau, T. P. Karnowski, Y. Li, S. Garg, K. W. Tobin, and E. Chaum, "Exudate-based diabetic macular edema detection in fundus images using publicly available datasets," Med Image Anal, vol. 16, no. 1, pp. 216–226, 2012.

[16] M. Poon, G. Hamarneh, and R. Abugharbieh, "Live-vessel: Extending livewire for simultaneous extraction of optimal medial and boundary paths in vascular images," in Lecture Notes in Computer Science, Medical Image Computing and Computer-Assisted Intervention (MICCAI), 2007, pp. 444–451. [17] (2013) The Diabetic Retinopathy Image Database. [Online].Available:http://www.fer.unizg.hr/ipg/resources/image database