

A Novel Technique for Fetal Health Analysis of Ultrasound Images

Ms.Sagara M.R

M.Tech ,II year

Department of CSE

Lourdes Matha College of Science and
Technology, Kerala

Prof. Beshiba Wilson

Associate Professor and Head

Department of CSE

Lourdes Matha College of Science and
Technology, Kerala

Abstract— *Ultrasound imaging has been widely used for medical diagnosis. Health conditioning of the fetus is analyzed by doctors and medical experts who takes care of the pregnant women.. At different ages of pregnancy analysis, the condition of the baby in the womb is very important. Ultrasound image processing can be done by experts, and medical personnel to determine the development of the fetus; whether it is healthy or there is any abnormality. The parameters used for determining the development of the fetus are crown rump length (CRL) and the gestational sac diameter. The parameters are expected to be visible after the ultrasound image through a phase of segmentation by using the Active Contour Models.*

Keywords: *Ultrasound, Fetus, Active contour models*

I. INTRODUCTION

Medical imaging systems plays a significant role in modern medical world. The health status of the uterus and the fetus should be early analyzed with the help of image processing techniques. Analysis of the fetal health of the womb is important in the case of pregnant women. In every stages of the womb we have to analyze the growth of the fetus and should take the remedial measures. Ultrasound diagnosis is frequently used throughout the pregnancy period for monitoring the health and growth of the pregnancy.

Miscarriage is the most common complication in the pregnancy stage. Studies saying that, approximately one out of five pregnancies are lost before 24 weeks, mostly before 12 weeks i.e.; first trimester. Evaluation of gestation during the early period is important to confirm the presence and the number of pregnancies, the location of the gestational sac (GS) and well-being of the embryo. Ultrasound technology is used as it is safe for patients. This is safer than that of the other techniques. Even though processing is needed to eliminate the noise, low contrast and poor image quality. Segmentation is the important part of the image processing in the health sector. Image segmentation can be performed using various methods like Watershed, Clustering, Active contour, Edge Detection Algorithms and so on. Here, Active Contour Modelling Method is used. In this method, collecting several points which are connected and controlled by a line. The output of the segmentation process is a fetal ultrasound image where the fetus and gestational sac have been separated from the background object.

II. THEORY SUPPORT

A. Ultrasonography

Medical ultrasound (sonography) is an ultrasound imaging[1] diagnostic technique used to image internal organs and muscles, their size, structure and the pathology wounds, making this technique useful for examining organs. Obstetric sonography is commonly used during pregnancy. Digital image processing is one of the areas in the computer world began to grow since human understand that computers are not only able to handle text data but also image data, image processing technology is used.

These digital biomedical image processing processes generally aim to detect objects and to perform further measurements and then be used to support the diagnostic process [2]. For this purpose, the type of image processing that is often required in this

application is the process of preprocessing as well as the classification and image segmentation. Pre-processing process is often referred to as, low-level processing [3]. At that stage, it is usually necessary to improve the quality of the image, as well as the process of detecting the sides or lines of boundaries between different objects, such as between bone and tissue or between healthy tissue and diseased tissue. Image analysis in the form of detection or identification of objects can be done through the process of comparison between the object characteristics observed with knowledge of the familiar object characteristics. The process of diagnosis based on the results of this image processing is not enough just to see the difference in the gray level of the image elements between the sick and the healthy parts, but also through the differentiation of the size of body parts, under normal circumstances.

B. Fetal Anatomical Parameters

To determine the gestational age and to predict the state of a pregnancy, whether the fetus in it will grow healthy or miscarriage; the fetal length measures such as Crown Rump Length (CRL) and Gestational sac (GS) diameter are widely used. This measurement will be best done for the gestational period of 6 to 10 weeks.

1. Crown Rump Length(CRL)

Crown Rump Length (CRL) is the measurement of the length of human embryos and fetuses from the top of the head (crown) to the bottom of the buttocks (rump). It can be determined from the ultrasound imaginary and can be used to estimate the gestational age. CRL can be measured at 6-7 weeks gestation. CRL is the most accurate measurement method in determining gestational age in early pregnancy with error rate of ± 3 days only. After 10 weeks pregnancy the fetus will become more so that is why its accuracy decreases.

2. Gestational sac(GS) diameter

Gestation sac begins to be seen with ultrasound devices at 4-5 weeks gestation. By determining the gestational age by measuring the gestational sac diameter we can calculate the age of pregnancy by counting the last menstruation.

C. Image segmentation

Image segmentation [4] is the process to separate between one object with another object or between objects with background contained in an image. With the process of segmentation, each object in the image can be taken individually so it can be used as input for other processes. In this paper we used the active contour modelling for image processing.

D. Active Contour Models

In the segmentation techniques, Active contour models [5] is commonly used. Active contour models make use of the energy constrains and forces in the image for separation of region of interest. Active contour defines a separate boundary or curvature for the regions of the target object for the segmentation. The active contour models was first introduced in 1987. In active contour model, the principle of minimizing energy that detects certain features in an image is a flexible curve (surface) that can adapt dynamically to the desired edge or the object in the image can be used for object segmentation automatically.

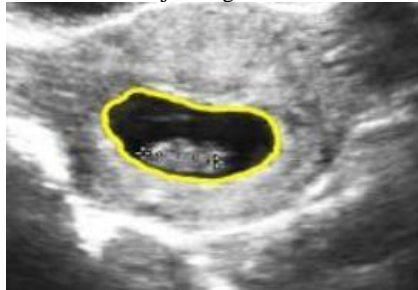


Figure 2.1. The basic form of Active contour

III. SYSTEM DESIGN

This section includes the designing and the manufacturing of the system. Here we are depicting process flow diagram of the final project:

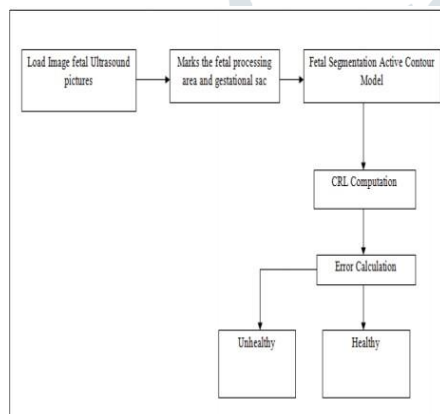


Fig. 3.1 Process flow chart

A. Load Image

In this paper, the input used is an offline image of the fetal ultrasound. The fetal image used is of 6 to 10 weeks and is of .jpg format. Here we are giving the snippet of the image used.

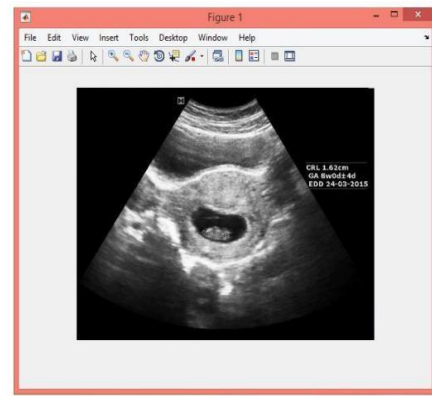


Fig. 3.2 Input Image

B. Segmentation of the pregnancy pouch

To detect the pregnancy sac on the fetal ultra sound image the next step is to segment the image. Here we used the active contour modelling method. For contouring the image we have to plot five points and then the accurate segmentation of the image is generated after 1200 iterations. Then we have to extract the exact gestational sac region of the image.

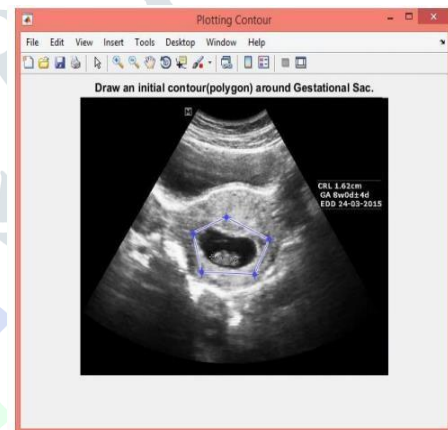


Fig 3.3 Plot of initial contour around the gestational sac

IV. EXPERIMENTS AND RESULTS

A. Fetal Segmentation Stage and Pregnancy Pouch

After processing the marked segmented area we have to segment the gestational sac from the ultrasound image.

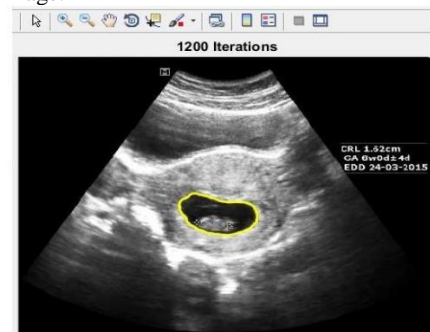

Fig 3.4 Accurate segmentation

B. Extract the Gestational sac Region

The gestational sac region should be extracted from the image.



Fig 3.5 Extracted gestational sac region

C. Computation of CRL

To compute the CRL of the fetus, we have to plot the point on the head and the buttocks part of the fetus. From that the length should be calculated and compared with the chart published by the WHO. For the analysis of the health of the fetus the CRL and gestational sac diameter should be computed and the variations are noted. Fetal images and CRL chart is given below:

Fetal Input	CRL Measurements (in cm)	Fetal Length Reference	Length Difference in %
img1.1	2.13	2.03	1.92
img2.1	4.25	4.59	0.95
img3.1	1.66	1.62	2.811
img4	6.16	5.18	16.07

Table. 3.1 CRL measurement, fetal length, length difference of various fetal input images

D. Accuracy in the measurements

The accuracy of the measurements of the CRL are calculated in percentage.

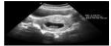



SI No.	IMAGES	VARIATION OF CRL IN %	PASS / FAIL
1		2.811	PASS
2		16.52	FAIL
3		1.607	PASS
4		2.547	PASS

Table 3.2 Accuracy in measurements of the CRL

V. FUTURE SCOPE

There is a challenging future for image processing in the medical field. The health of the fetus can be determined by using many other methods other than the computation of the CRL and the gestational sac. The machine learning concepts are also used in the image segmentation stages and the fetal growth can be easily studied.

VI. CONCLUSION

The CRL and Gestational sac diameter are computed for analyzing the health of the fetus. After the image segmentation, the CRL and the Gestational sac (GS) should be measured. The measured CRL is compared with the reference value of the CRL of that particular pregnancy month. Finally the variation in the measurements is noted and take remedial measures if necessary.

References

[1] Sanjaya Shankar Tripathy, "Automatic Health monitoring of Fetus from Ultrasound Images using Level Set Algorithm" International Conference on Green Computing Communication and Electrical Engineering (ICGCCEE),2014

[2] S. Sridevi and M. Sundaresan, "Survey of image segmentation algorithms on ultrasound medical images," 2013 International Conference on Pattern Recognition, Informatics and Mobile Engineering, Salem, 2013, pp. 215- 220

[3] Bo Ma, Zheru Chi, Tianwen Zhang "Motion Detection and Tracking Based on Level Set Algorithm" in 8th ICARCV Dec2014, Vol.1, pp. 659-664, Dec 2014

[4] N. H. Mahmood and A. H. Rusli, "Segmentation and area measurement for thyroid ultrasound image," International Journal of Scientific & Engineering Research, vol. 2, no. 12, pp. 1-8, 2011.

[5] Riyanto Sigit, S.T., M.Kom, Ph.D , " Health Monitoring of Fetal Ultrasound Image Using Active Contour Models " International Seminar on Application for Technology of Information and Communication" (iSemantic)(IEEE Xplore), 2017