

Autologous fat grafting in surgical repair of cleft lip – a preliminary study

¹Pankaj Kukreja, ²Deepak Kumar, ³Bhavna Jha Kukreja

¹Ph.D research scholar,

²Professor,

³Ph.D research scholar,

^{1,2}Department of Oral and Maxillofacial surgery, ³Department of Periodontology

^{1,2,3} Babu Banarsi Das College of dental sciences, Babu Banarasi Das University, Lucknow, Uttar Pradesh, India.

Abstract

Aim: The present study was undertaken to evaluate the post-operative cosmetic effect of fat taken from buccal fat pad and injected into deficient areas at the time of primary unilateral cleft repair in infants.

Methodology: Data from 14 subjects who had undergone surgical repair of cleft lip was analyzed retrospectively. 7 had received the processed fat graft during surgery, and 7 did not receive any graft. Postoperatively clinical evaluation of the overall appearance of face, upper lip, nose and midface of the infants was done using a Likert type scale by three blinded independent calibrated observers.

Results: Statistical analysis of the results by Mann Whitney U test showed that overall appearance of the face was not significantly improved ($p=0.75$), but was significantly improved in upper lip ($p=0.02$), nose ($p=0.032$) and midface ($p=0.037$).

Conclusion: It may be inferred from the above study that fat grafting may appear to enhance the esthetic outcome in the local anatomical region of the cleft.

Keywords: fat, graft, cleft lip.

I. INTRODUCTION

The field of cleft lip and palate surgery has undergone tremendous advancements in recent years. Yet there is no single surgical technique which gives the ideal result of cleft repair.¹ Its functional and aesthetic problems are very much debilitating. Both the child and the parents are affected. Particularly it is seen in those who grow with a bad repair or with an uncorrected defect. The child and parents are psychosocially affected. They face problems like rejection in the society, associated stigmata and decreased self-esteem. The child also is not able to accept itself. Children often face challenges of peer integration and are affected by functional derangements.^{2,3,4} Therefore, it deeply affects the health-related quality of life of the individual with cleft deformity.^{5,6} A surgical repair of the cleft deformity which is good to look at, and is equally providing functionality can relieve this huge problem.

Based on the patients' sex, age, the operative technique used and the degree of severity of the cleft before surgery, a plethora of studies have compared esthetic outcome of different cleft surgeries. From the point of view of the patients', parents, or the lay observer, they bear little relevance. But for the trained surgeon, these considerations have a really important scientific basis and are of immense clinical relevance. The cleft surgeons also have a keen and persistent interest in the betterment of the aesthetic outcome of a corrective cleft surgery. It is, therefore, quite important to develop a technique, and an outcome assessment tool that minimizes the residual deficit in cleft repair, and increases the esthetic outcome.⁷

A Successful cleft lip repair creates a minimum scar tissue and forms a symmetric nose and lip morphology while maximizing function at the same time. Autologous fat grafting is used commonly in cleft surgery. It is also used in cosmetic and reconstructive surgery. It uses an abundant reservoir of adipose tissue which contours and conditions tissue and aids healing. Previous studies have used autologous fat grafting at the time of primary cleft surgery. Some of them have revealed good results. Therefore, the present retrospective study was undertaken to compare the effect of simultaneous fat transfer in the esthetic result of the cleft lip surgery.⁸

II. MATERIALS AND METHODS

The present study included retrospective analysis of anonymous photographic data of patients who had undergone cleft lip surgery more than 9 months prior. The photographs showed only the lip, nose and midface region excluding the eyes. 10 patients' photographs were included in the study. The patients had undergone for cleft repair under oro-endotracheal general anesthesia. 5 of the patients had received autologous fat graft in the cleft region to obtain esthetic symmetry and were named group-1, the other 5 who did not receive fat grafts were termed as group-2. The fat graft was prepared by hand held aspiration by a well trained surgeon using the Coleman technique from the buccal vestibule with the overlying buccal fat pad, next to the posterior maxillary ridge. The fat was deposited at 4 different sites, submucosally (at the vermilion / mucosal junction); subcutaneously and intramuscular (along the philtrum); and preperiosteal at the piriform rim and the nose as the final stage following all suture placement. This was hoped to give a better esthetic result due to more symmetrical reconstruction. All Patients were discharged 5 to 6 days postoperatively, when it was observed that they were tolerating oral feeds well.

Care included steri-strips and silicone gel after suture removal, regular follow up and counseling. Postoperatively, cleft patients' frontal facial photographs were taken at 9 months. Each photograph was taken using a standard protocol adopted by the photography team with a single lens reflex camera. Three blinded calibrated reviewers analyzed the photographs to assess the residual cleft related stigmata on a 5 point ordinal scale, as described by Balkin et al, 2014.⁸ The sites analyzed included overall appearance of face, Upper Lip, Nose and the Midface.

The scoring criteria was Score 1 = Non Visible Stigmata (Very Good Appearance), Score 2 = Barely Visible Stigmata (Good Appearance), Score 3 = Slightly Visible Stigmata (Fair Appearance), Score 4 = Moderately Visible Stigmata (Poor Appearance) and Score 5 = Very Visible Stigmata (Very Poor Appearance). The data concerning the study was recorded on preformed proforma / case history sheet and was evaluated and analyzed using Mann Whitney U test.

III. RESULTS

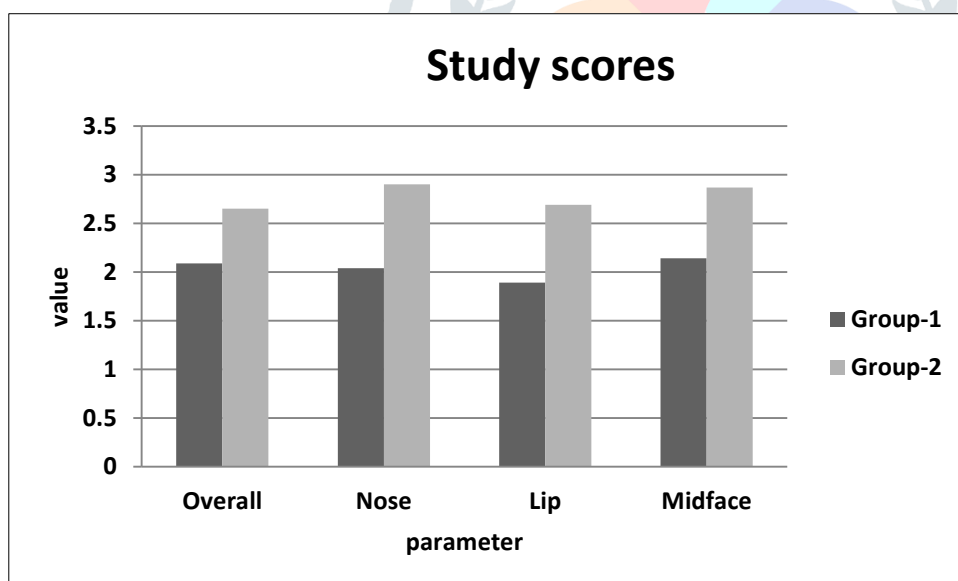
The mean age of the patients was 1.01 ± 0.28 years. 8 were males and 6 were females. All had unilateral cleft deformities. The mean time of taking the photographs was 9.6 ± 0.9 months postoperatively. The photographs were taken by a single lens reflex camera and included the front profile of the patient, showing the repaired lip, the nose and the midface excluding the eyes. They were evaluated by three different calibrated independent observers who were blinded to the study. Mann Whitney U test was used for data analysis

The results showed that for overall appearance of the face, average score in group-1 was 2.09 ± 1.07 (mean \pm standard deviation) and in group 2 was 2.65 ± 0.73 . (Table-1, Figure-1). For the nose region the score was 2.04 ± 0.92 in group-1 and 2.90 ± 0.87 in group-2 (Table-1, figure-1). For the appearance of the lip, average score in group-1 was 1.89 ± 0.18 (mean \pm standard deviation) and in group 2 was 2.69 ± 0.87 . (Table-1, Figure-1). For the midface region the score was 2.14 ± 0.32 in group-1 and 2.87 ± 0.22 in group-2 (Table-1, Figure-1). The results showed that in almost all aspects, the appearance was better in group-1 than group-2.

Table-1: Statistical analysis of study data scores

	Group-1	Group-2	p-value	Significance
Overall	2.09 \pm 1.07	2.65 \pm 0.73	0.750	Not Significant
Nose	2.04 \pm 0.92	2.90 \pm 0.87	0.020	Significant
Lip	1.89 \pm 0.18	2.69 \pm 0.87	0.032	Significant
Midface	2.14 \pm 0.32	2.87 \pm 0.22	0.037	Significant
p-value<0.05 = statistically significant				

Figure-1: Graphical representation of statistical analysis



IV. DISCUSSION

It is a daunting and challenging task to achieve a near ideal correction of the Cleft lip deformity. A number of materials like fat, dermis, mucosal grafts etc have been suggested as a means of achieving an ideal result of surgery. It is well known that autologous fat is an easily accessible and abundant reserve in the body. Fat grafting technique is quite simple to perform. It also has an advantage of no serious donor site morbidity. It also has significantly less tissue reaction than alloplastic materials and has more appropriate volume.^{5,9}

A mean age of 1.2 years was revealed by the present study. It also showed a male predilection. This is in accordance with the previously established data of male predilection of cleft lip with or without palate. In the present study, the fat grafting did not improve the result in overall appearance of the face. The results are not in accordance with results of Balkin et al (2014).⁸ They have reported in their study an improvement in the overall appearance of the face. The present study also showed a significant betterment in the appearance of the nose, lip and midface. These results are in accordance with a study by Balkin et al (2014).⁸

The present study used photographs which were cropped. It was done in a standardised circular manner. It revealed only the midface below the eyes, showing only the patient's nose and mouth. Such masked photographs were described and used by Asher-McDade et al,¹⁰ It is a well established scale for measuring the nasolabial symmetry. But it is also possible that cropping can affect the ratings. Presence of symmetry artifacts of the face can still be visible in some of the masked photographs. In cropped photographs with only a circle showing the patient's nose and mouth, it is much less likely that a symmetry artifact will occur.¹¹

Autologous fat graft can positively affect scar formation. It also enables soft-tissue augmentation. Zellener et al (2015) undertook a study on patients who underwent primary cleft lip repair with and without immediate fat grafting.¹² They opined that fat grafting during immediate cleft lip repair may be of benefit the final aesthetic appearance. Three blinded reviewers analysed the postoperative photographs. The result revealed a significant improvement in scar appearance and contour. They used Cronbach statistics and two-tailed t-test. Their study concluded that immediate fat grafting appears to be a useful technique of use in cleft surgery. It is beneficial in improvement of lip contour, appearance, and scarring.

Within its limitations, the present study shows that fat grafting is a useful technique which can be used to optimize the result of cleft lip surgery. The improvement is primarily in the aesthetic aspects, which can be immensely beneficial to the patient.

V. CONCLUSION

The autologous structured fat grafting method is a relatively easy procedure. It is of prime importance in the field of cranio-maxillofacial surgery. It has a large range of applicability in the field of tissue regeneration. It also aids in volume restoration as fillers and helps in scar modulation, especially in cleft lip and palate surgery. It can be used to fill deficient midfacial volume and treat velopharyngeal insufficiency. In this article, the authors show that immediate fat grafting in cleft lip surgery improves the facial appearance in local region. The use of fat grafting in patients with clefts is also supported adequately by recent literature.

VI. ACKNOWLEDGMENT

None

VII. REFERENCES

- [1] Sinko K, Jagsch R, Precht V, Watzinger F, Hollmann K, Baumann A. 2005. Evaluation of esthetic, functional, and quality-of-life outcome in adult cleft lip and palate patients. *Cleft Palate Craniofac J.* 42:355–61.
- [2] Van Lierde KM, Dhaeseleer E, Luyten A, Van De Woestijne K, Vermeersch H, Roche N. 2012 Parent and child ratings of satisfaction with speech and facial appearance in Flemish pre-pubescent boys and girls with unilateral cleft lip and palate. *Int J Oral Maxillofac Surg.* 41:192–99.
- [3] Fudalej P, Katsaros C, Bongaarts C, Dudkiewicz Z, Kuijpers-Jagtman AM. 2009 Nasolabial esthetics in children with complete unilateral cleft lip and palate after 1- versus 3-stage treatment protocols. *J Oral Maxillofac Surg.* 67:1661–66.
- [4] Gkantidis N, Papamanou DA, Christou P, Topouzelis N. 2013 Aesthetic outcome of cleft lip and palate treatment. Perceptions of patients, families, and health professionals compared to the general public. *J Craniomaxillofac Surg.* 41:e105–10.
- [5] Vlastos IM, Koudounnakis E, Houlakis M, Nasika M, Griva M, Stylogianni E. 2009 Cleft lip and palate treatment of 530 children over a decade in a single centre. *Int J Pediatr Otorhinolaryngol.* 73:993–97.
- [6] Marcusson A, Akerlind I, Paulin G. 2001 Quality of life in adults with repaired complete cleft lip and palate. *Cleft Palate Craniofac J.* 38:379–85.
- [7] Adeola AO, Oladimeji AA. 2015 Developing a visual rating chart for the esthetic outcome of unilateral cleft lip and palate repair. *Ann Maxillofac Surg.* 5:55–61.
- [8] Balkin DM, Samra S, Steinbacher DM. 2014 Immediate fat grafting in primary cleft lip repair. *J Plast Reconstr Aesthet Surg.* 67:1644–50.
- [9] Zuk PA, Zhu M, Mizuno H, Huang J, Futrell JW, Katz AJ, Benhaim P, Lorenz HP, Hedrick MH. 2001 Multilineage cells from human adipose tissue; implications for cell based therapies. *Tissue Eng.* 7:211–28.
- [10] Asher-McDade C, Roberts C, Shaw WC, et al 1991 Development of a method for rating nasolabial appearance in patients with clefts of the lip and the palate. *Cleft Palate Craniofac J* 28:385–391
- [11] Burgess CM. 2006. Principles of soft tissue augmentation for the aging face. *Clin Interv Aging* 1(4):349–55.
- [12] Zellener EG, Pfaff MJ, Steinbacher DM. 2015 Fat grafting in primary cleft lip repair. *Plast Reconstr Surg* 135(5): 1449–53