

# Ultrasound tailored diagnosis and treatment of sub acromial shoulder pain pathology: A case series

**Dr Depinder Kaur**

Associate professor, Department of Anaesthesia ,SHKM,GMC,Nalhar,Nuh

**DR Harnaam Singh Madan**

Associate professor,department of Orthopedics, SHKM,GMC,Nalhar,Nuh

**Dr Shanu Gupta, Senior Resident.**

department of Orthopedics, SHKM,GMC,Nalhar,Nuh

**Dr Suchitra Malhotra**

Professor, Department of Anaesthesia ,SHKM,GMC,Nalhar,Nuh.

## Introduction

Mobility of shoulder joint comes at the cost of stability. Rotator cuff is one of the main structures essential for dynamic and static stability as well as mobility of the joint. Although rotator cuff tears are common cause of subacromial shoulder pain and disability but other structures may generate pain and treatment depends upon type of underlying pathology, so clinical judgment alone is not sufficient enough to initiate interventional treatment.

MRI is the gold standard imaging modality for diagnosis of shoulder pathology. However, recently use of ultrasound (USG) has evolved as a promising tool for diagnosing extra-articular soft-tissue shoulder pathology. Portability, easy availability, low cost and advantage of planning an intervention are notable advantages of ultrasound. USG is the modality which shall be used in both diagnostic and therapeutic purposes for management of subacromial shoulder pathologies.<sup>1</sup>

Here we present a case series of 5 patients presenting at pain clinic with subacromial shoulder pain after failed conservative treatment. Each patient was evaluated with ultrasound for pathology based diagnosis and further treatment for Improved outcome. Patient feedback was recorded to capture improvement in the condition after administration of intervention based on ultrasound findings.

## Case 1

### Long head of biceps tendon pathology and subacromial pain

A 62 year old male patient presented with anterior shoulder pain and painful restriction of right shoulder movement since 2 months. Patient had VAS score of 6 at rest and 9 at movement.

## Clinical examination

On examination Neer's test and Hawkins Kennedy tests along with painful arc were positive.

Specific clinical tests were performed to assess underlying pathology. The Yergason's test and Speed's test were positive suggestive of biceps tendon pathology.

## Diagnostic ultrasound examination

Ultrasound examination of shoulder was done in a step wise manner and effusion seen around biceps tendon sheath along with rotator cuff full thickness tear. Ultrasound guided Biceps sheath injection of Local anesthetic and steroid was given.

**Follow up** At 2 months follow up patient had VAS score of 3 at rest and 5 at movements. She was put on supervised physiotherapy for further management.

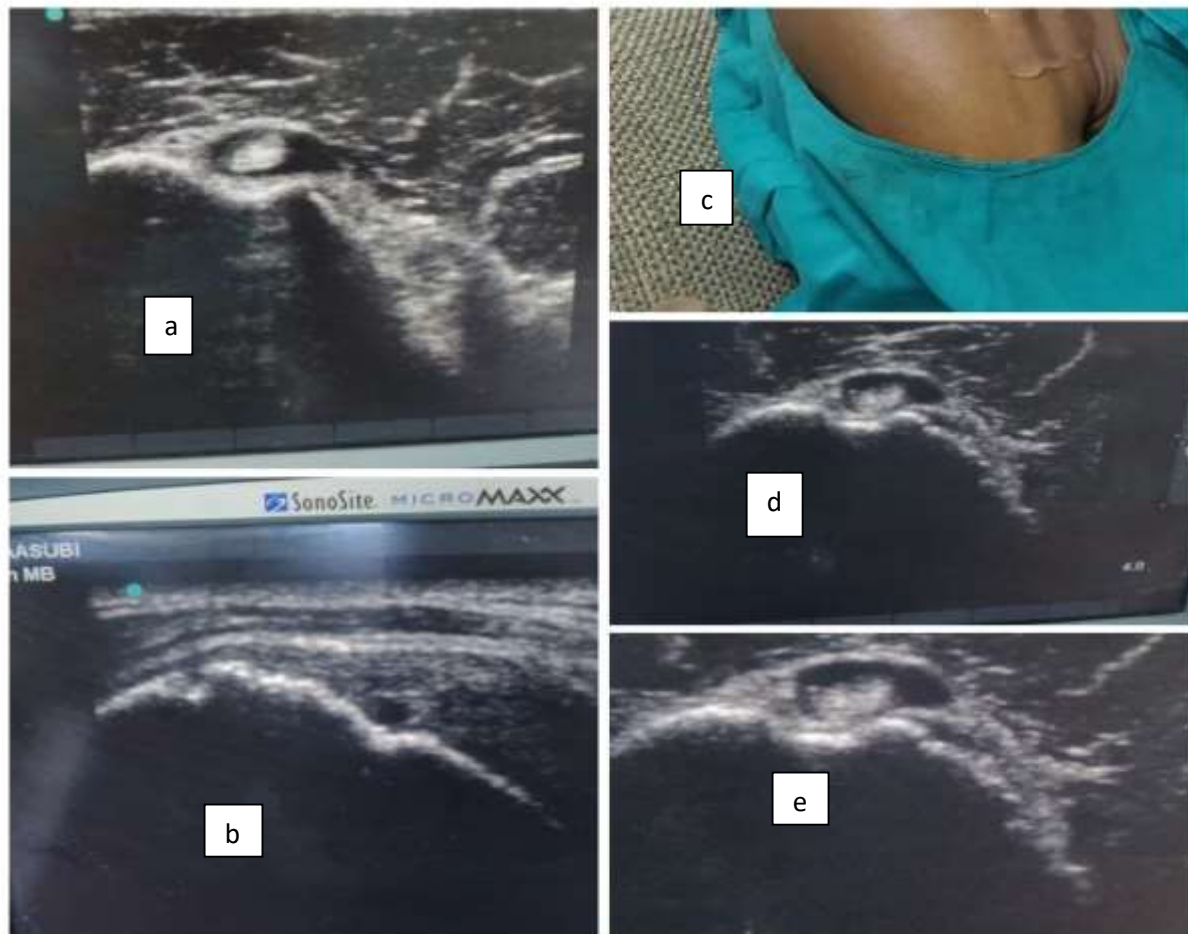


Fig 1

Ultrasound examination of Biceps tendon.

Large collection is seen around biceps tendon sheath in (a, d and e).

Peribursal sagging sign is seen suggestive of FTT of supraspinatus as seen in (b).

## Case 2

### Supraspinatus tear and subacromial pain

A 40 year female patient presents with acute traumatic shoulder pain following a fall on outstretched hand. Her pain score was 7 on NRS at rest and she was reporting severe pain on overhead abduction.

On Ultrasound examination of shoulder she was found to have supraspinatus tear on articular side.

Patient was given ultrasound guided sub acromial sub deltoid (SASD) injection of Local anesthetic and steroid for immediate pain relief. On follow up visits patient had good pain relief. She was given platelet rich plasma (PRP) injection under ultrasound guidance after 6 weeks of steroid injection. On further follow up patient had complete pain relief and functional restoration.

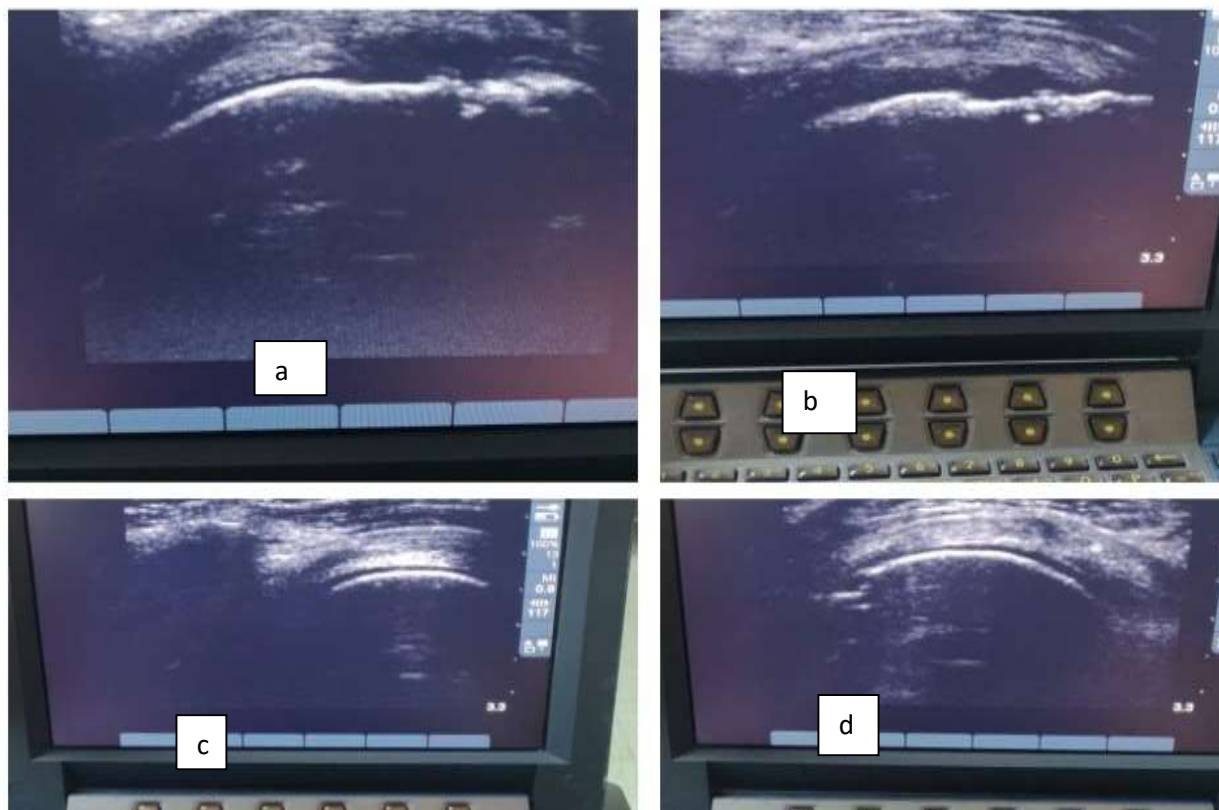


Fig 2

Longitudinal ultrasound image showing articular side tear of supraspinatus muscle. Cortical irregularity of greater tuberosity is an indirect sign of tear in (a and b)

Transverse scan of supraspinatus is showing intact infraspinatus muscle in (c and d).

### Case 3

#### Subscapularis tear along with Acromio-clavicular joint pathology and subacromial pain

A young patient 20 year male, wrestler by profession complaints of shoulder pain on overhead abduction after an injury.

On examination internal rotation lag sign and lift off test were positive.

There was tenderness over AC joint and horizontal body adduction test was positive.

On Ultrasound examination Subscapularis tendon tear with subluxation of biceps tendon was visualized along with AC joint effusion.

Ultrasound guided AC joint injection was given followed by supervised physiotherapy.

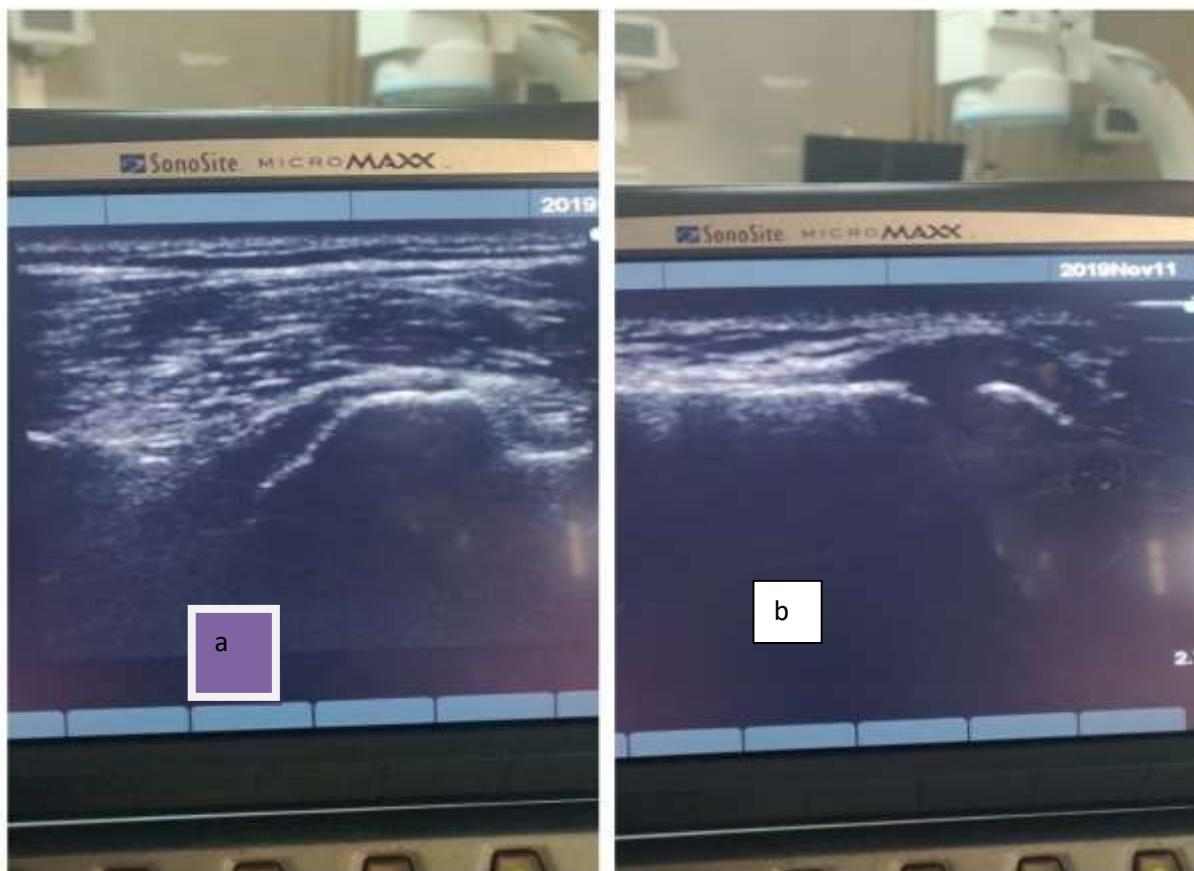
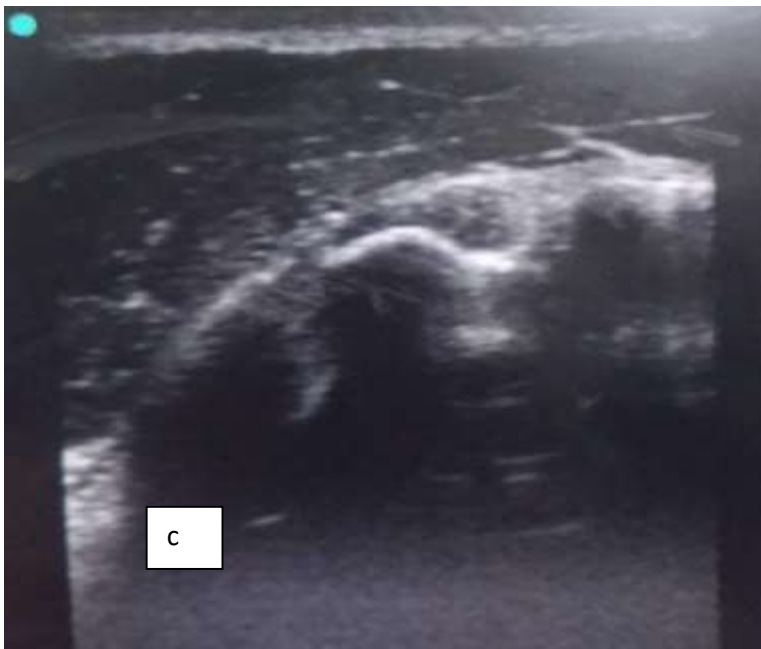

Fig 3

subscapularis tear in (a) and AC joint effusion (b)



Subluxation of biceps tendon in subscapularis tear

#### Case 4

##### **Supraspinatus tendinosis and subacromial pain**

A 23 year female patient teacher by profession complained of pain while writing on black board. She had severe pain and not able to join the job because of her functional limitation.

On clinical examination tests for supraspinatus and subacromial pathology were positive. Patient was managed with suprascapular nerve injection with local anaesthetic and steroid for pain relief.

On follow up visits patient was pain free and had joined her job.

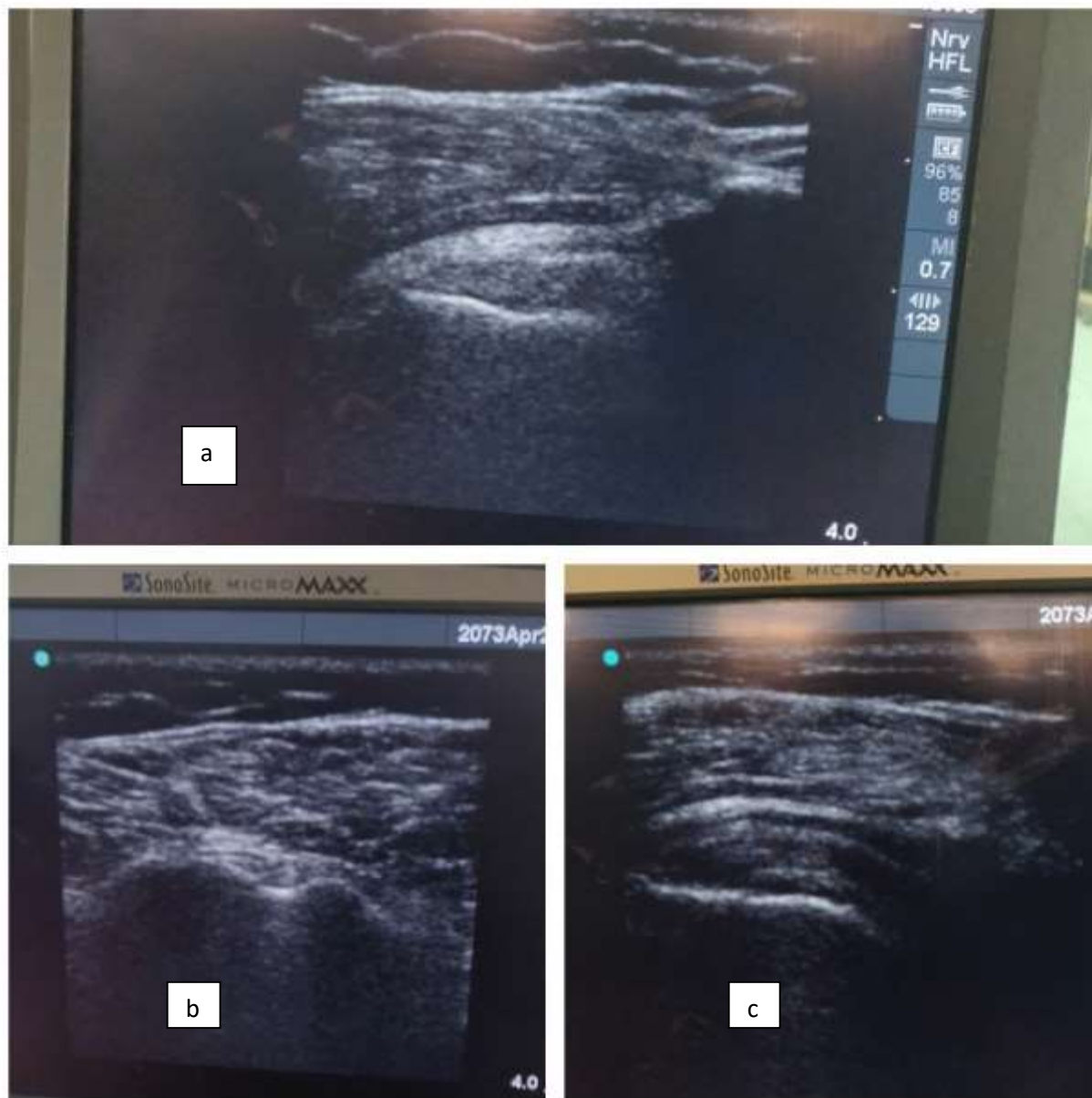

Fig 4

Ultrasound appearance of supraspinatus tendinosis showing thickened and heterogeneous tendon with no local defect in (a) and (c) along with small SASD collection.

SASD subacromial subdeltoid collection

## Case5

### Full thickness Rotator cuff tear, SASD effusion and subacromial pain

65 year male patient presents with weakness and pain in right shoulder. He complains of pain from last 3 months and not able to sleep on affected side. On examination painful arc and weakness in external rotation and abduction is seen. Jobe test and Drop arm tests are positive for rotator cuff tear.

USG examination was done to evaluate underlying pathology and treatment.

### Treatment

Patient was given USG guided SASD injection of LA and steroid for immediate pain relief followed by physiotherapy. For complete evaluation of full thickness Rotator cuff tear for surgical repair, patient was advised MRI shoulder.

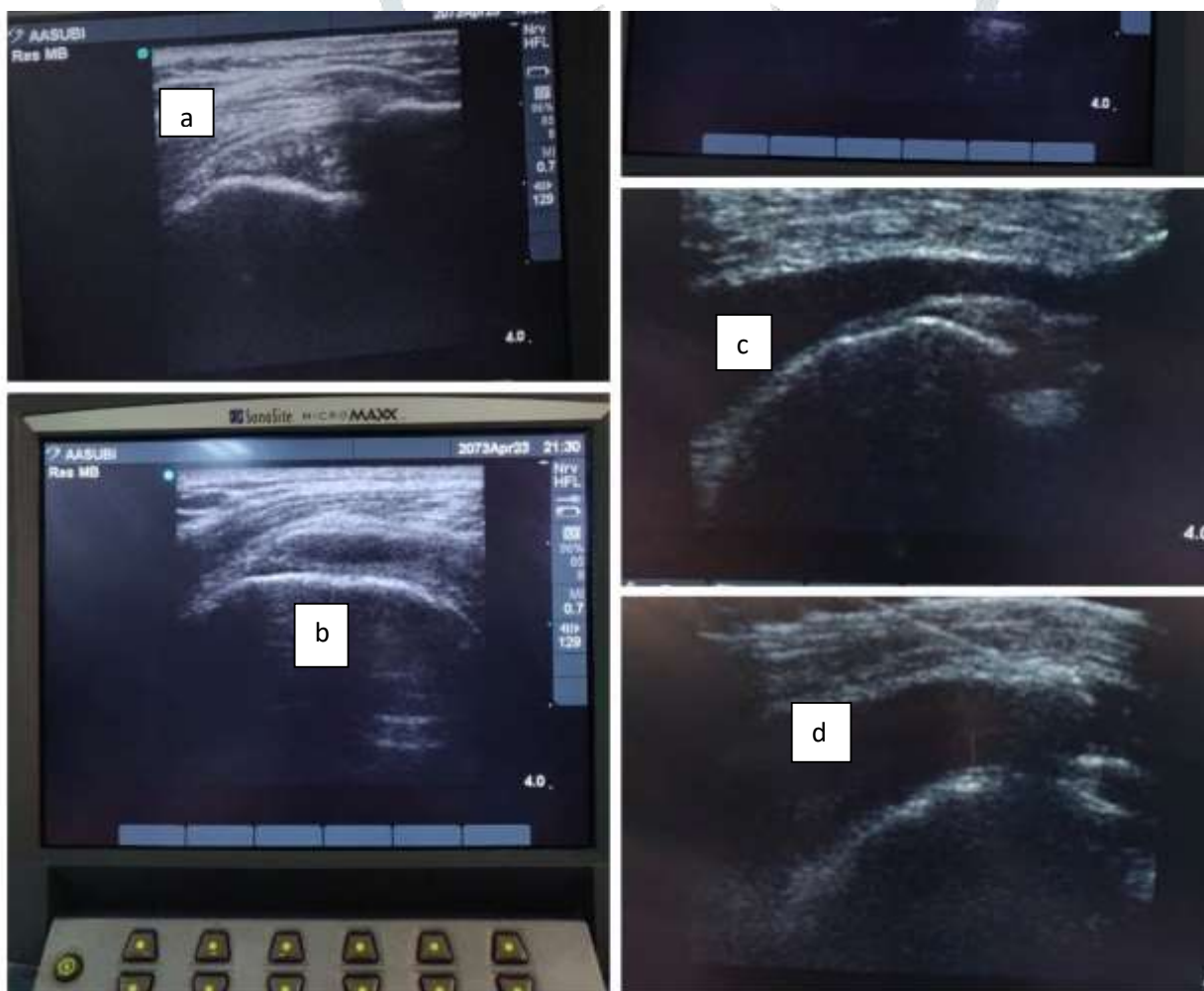


Fig 5

Normal contralateral shoulder scan for comparison (a)

USG picture showing large SASD collection along with full thickness RC tear as suggested by loss of convex rim of muscle above humerus c.

Ultrasound guided subacromial subdeltoid injection (d)

## ***Discussion***

Subacromial Impingement syndrome (SAIS) is defined as usually unilateral, shoulder problems that cause pain, localized around the acromion, often worsening during or subsequent to lifting of the arm. The different clinical and/or radiological names, such as bursitis, tendinosis calcarea, supraspinatus tendinopathy, partial tear of the rotator cuff, biceps tendinitis, or tendon cuff degeneration are all part of SAIS.

We in our institution followed an algorithm for management of SAIS with combination of clinical tests along with ultrasound evaluation of shoulder. Instead of directly jumping to MRI or putting the patient on long term conservative treatment on the basis of clinical diagnosis and blind interventions. Notable feature of this case series is to help us to understand the concept of allocation of health care resources according to health care needs. Ultrasound shall be used for initial diagnosis and management of subacromial shoulder pain patients and MRI can be advised on the basis of USG findings or non responsive cases.

### **1 *Clinical examination including specific clinical test***

To determine SAIS, a combination of the Neer's test, Hawkins-Kennedy test, the painful arc test were performed initially, followed by specific diagnostic clinical test for individual muscle evaluation. The specific clinical diagnostic test done in our patients are listed below <sup>2</sup>

#### **For subsapularis**

- Lift off test : More accurate for inferior portion of subscapularis.
- Belly press test : More accurate for superior portion of subscapularis.
- Internal rotation lag sign: This test is most sensitive and specific for subscapularis pathology.

#### **Tests for supraspinatus**

- Jobe sign For supraspinatus muscle strength
- Drop arm sign For supraspinatus tear



**Tests for infraspinatus** External rotation lag sign

**Test for Teres Minor** Horn Blowers sign

### Tests for AC joint

- AC joint tenderness
- Cross body adduction test

## 2 Ultrasound examination of shoulder

All patients were examined with commercially available real time equipment (Sonosite Micromax portable ultrasound machine ) using a 7.5 MHz linear phased array transducer. Transverse and longitudinal planes from the biceps tendon groove, rotator cuff, and subacromial-subdeltoid bursa and transverse planes from the posterior glenohumeral recess and glenoid labrum were scanned. In all patients, comparable images of the opposite shoulder were obtained in order to compare US findings.

Table 1 lists the US diagnostic criteria for shoulder abnormalities, which are based on those widely described in the literature <sup>(3-8)</sup> The study of Naredo *et al.* <sup>(9)</sup> showed that with the clinical tests performed in the study an exact diagnosis of the underlying shoulder pathology could not be made. Iagnocco *et al.* found in his study<sup>(10)</sup> that the sonographic examination has a higher sensitivity and specificity than the clinical examination.

Table 1

**Table 1** Ultrasonographic diagnostic criteria of shoulder abnormalities

Shoulder abnormality	Diagnostic criteria
Biceps sheath effusion	Thickness of the hypochoic halo of fluid surrounding the biceps tendon greater than 2 mm
Biceps tendinitis	Increased fluid within the synovial sheath and tendon hypochoogenicity and/or thickening
Biceps tendon rupture	Partial or complete interruption of the tendon fibres, separation of the ends and hypochoic fluid filling the defect
Biceps tendon subluxation	Empty bicipital groove and identification of the displaced tendon
Biceps tendon degeneration	Tendon hypochoogenicity and tendon thinning
Rotator cuff tendinitis	Tendon hypochoogenicity or tendon thickening with or without internal hypo or hyperechoic foci
Subscapularis full thickness tear	Non-visualisation of tendon or complete fibres discontinuity
Subscapularis partial thickness tear	Partial fibre discontinuity
Supraspinatus and infraspinatus full thickness tear	Non-visualisation of tendon or fibre discontinuity from the humeral head to the subacromial-subdeltoid bursa or superior convexity instead of concavity
Supraspinatus and infraspinatus partial thickness tear	Hypochoic fibre discontinuity involving the bursal or articular surface or intrasubstance hypochoic defect or focal tendon thinning
Subacromial-subdeltoid bursitis	Hypochoic fluid filled bursa greater than 2 mm thick
Acromioclavicular degenerative changes	Cortical irregularities or osteophytes, usually accompanied by intra-articular hypochoic fluid displacing joint capsule
Glenohumeral effusion	Distance from the posterior labrum to the posterior infraspinatus tendon greater than 2 mm
Rotator cuff calcifications	Hyperreflective foci or lines with acoustic shadowing
Rotator cuff impingement	A buckling of the cuff/rippling effect as the cuff passes beneath the coracoacromial arch or fluid distending the subacromial-subdeltoid bursa or thickened bursa in front of the acromion while the arm is abducted

### Advantage of using ultrasound

Easy accessibility, low cost, portability and dynamic evaluation of structure are some of the advantages of ultrasound which makes it promising imaging modality for diagnosis of shoulder pathologies.<sup>(11-16)</sup> Furthermore, US can be used as a guide in performing periarticular and intra-articular fluid aspirations, infiltrations, and biopsies, making these procedures more accurate than when carried out blind.

### Disadvantage of US

Disadvantages of US include lack of visualisation of the posterior aspect of the supraspinatus and infraspinatus tendons and a limited assessment of the glenohumeral joint. Furthermore, US is considered to be the most operator dependent imaging technique. However, the results of any imaging technique depend on the skill of the examiner.

### Conclusion

Ultrasound shall be used to obtain an exact diagnosis of the different periarticular shoulder lesions in order to evaluate their prognosis and their response to various conservative

treatment options. The availability of US in pain practice offers the possibility of establishing a more accurate diagnosis of the painful shoulder and therefore improving the treatment of this common disorder.

Further studies can be done for assessing the usefulness of ultrasound for follow up treatment of patients.

## Financial support and sponsorship

Nil.

## Conflicts of interest

There are no conflicts of interest.

## References

- 1 Moosmayer S, Heir S, Smith HJ. Sonography of the rotator cuff in painful shoulders performed without knowledge of clinical information: results from 58 sonographic examinations with surgical correlation. *J Clin Ultrasound*. 2007 Jan;35(1):20-6. doi: 10.1002/jcu.20286. PMID: 17149764
- 2 Naredo E, Aguado P, De Miguel E, Uson J, Mayordomo L, Gijon-Baños J, Martin-Mola E. Painful shoulder: comparison of physical examination and ultrasonographic findings. *Ann Rheum Dis*. 2002 Feb;61(2):132-6. doi: 10.1136/ard.61.2.132. PMID: 11796399; PMCID: PMC1754006.
- 3 Naredo E, Aguado P, De Miguel E, Uson J, Mayordomo L, Gijon-Baños J, Martin-Mola E. Painful shoulder: comparison of physical examination and ultrasonographic findings. *Ann Rheum Dis*. 2002 Feb;61(2):132-6. doi: 10.1136/ard.61.2.132. PMID: 11796399; PMCID: PMC1754006.
- 4 Middleton WD, Reinus WR, Totty WG, Melson CL, Murphy WA. Ultrasonographic evaluation of the rotator cuff and biceps tendon. *J Bone Surg [Am]* 1986;68:440–50.
- 5 Van Holsbeeck M, Introcaso JH. Sonography of the shoulder. In: Van Holsbeeck M, and Introcaso JH, eds. *Musculoskeletal ultrasound*. Chicago: Mosby Year Book, 1991:265–84
- 6 Bretzke CA, Crass JR, Craig EV, Feinberg SB. Ultrasonography of the rotator cuff. Normal and pathologic anatomy. *Invest Radiol* 1985;20:311–15.
- 7 Mack LA, Matsen FA, Kilcoyne RF, Davies PK, Sickler ME. US Evaluation of the rotator cuff. *Radiology* 1985;157:205–9.
- 8 Van Holsbeeck M, Kolowich PA, Eyler WR, Craig JG, Shirazi KK, Habra GK, et al. Ultrasound detection of partial-thickness tear of the rotator cuff. *Radiology* 1995;197:443–6

- 9 Naredo E, Aguado P, De Miguel E, Uson J, Mayordomo L, Gijon-Baños J, et al. Painful shoulder: comparison of physical examination and ultrasonographic findings. *Ann Rheum Dis*. 2002;61:132–136.
- 10 Iagnocco A, Coari G, Leone A, Valesini G. Sonographic study of painful shoulder. *Clin Exp Rheumatol*. 2003;21:355–358.
- 11 Fornage BD, Rifkin MD. Ultrasound examination of tendons. *Radiol Clin North Am* 1988;26:87–107. 39 Grassi W, Tittarelli E, Blasetti P, Pirani O, Cervini C. Finger tendon involvement in rheumatoid arthritis. Evaluation with high-frequency sonography. *Arthritis Rheum* 1995;38:786–94.
- 12 Chhem RK, Kaplan PA, Dussault RG. Ultrasonography of the musculoskeletal system. *Radiol Clin North Am* 1994;32:275–89.
- 13 Van Holsbeeck M, Introcaso JH. Sonography of bursae. In: Van Holsbeeck M, Introcaso JH, eds. *Musculoskeletal ultrasound*. Chicago: Mosby Year Book, 1991:91–122.
- 14 Van Holsbeeck M, Introcaso JH. Sonography of muscle. In: Van Holsbeeck M, Introcaso JH, eds. *Musculoskeletal ultrasound*. Chicago: Mosby Year Book, 1991:13–56.
- 15 Fornage BD, Touche DH, Segal P. Ultrasonography in the evaluation of muscular trauma. *J Ultrasound Med* 1983;2:549–54.
- 16 Alanen AM, Falck B, Kalimo H, Komu E, Sonninen VH. Ultrasound, computed tomography and magnetic resonance imaging in myopathies: correlations with electromyography and histopathology. *Acta Neurol Scand* 1994;89:336–46

