

# Detection of Diabetic Retinopathy Using Image Processing

**Darshan Kapadia,**

**Osama Ansari,**

**Prathamesh Gangurde,**

**Akhilesh Dhiman,**

*Department of Electronics and Telecommunication,  
Rizvi College of Engineering,  
Bandra (W), Mumbai-50  
University of Mumbai, India*

*Guided by:*

**Prof. Anuja Kamat**

*Rizvi College of Engineering,  
Bandra (W), Mumbai-50  
University of Mumbai, India*

*H.O.D*

**Prof. Junaid Mandviwala**

*Rizvi College of Engineering,  
Bandra (W), Mumbai-50  
University of Mumbai, India*

**Abstract:** Diabetic Retinopathy is a major disease that has affected over 290 million people globally and 69.2 million people in India, rate of people getting affected will increase exponentially in the coming years. Diabetic Retinopathy is an ailment linked to fundus of eye and have adverse effects on the patient, if at all left undiagnosed respectively.

Despite years of clinical and laboratory investigation, diabetic Retinopathy remains the leading cause of vision disability and blindness among working-age adults, yet the fundamental causes remains uncertain. Retinal photo-coagulation to reduce neovascularization and macular edema was developed in the 1950s and is still the standard of care. The number of people worldwide at risk of developing vision loss from diabetes is predicted to double over next 30 years, so it is vital to develop better means to identify, prevent, and treat Retinopathy in its earliest stages rather than wait for onset of vision-threatening lesions. Progress in these areas requires new perspective on problem that includes roles of the neural retina, diminished insulin action, and inflammation. In this way, established neurobiological principles can inform us how diabetes weaken vision, and knowledge of metabolism, inflammation, and renewal medicine may lead to new treatments.

Diabetic Retinopathy affects up to 80 percent of those who have had diabetes for 20 years or more. At least 90% of new cases could be reduced with proper treatment and observing of the eyes. The longer person has diabetes, higher his or her chances of developing Diabetic Retinopathy. Each year in the United States, diabetic Retinopathy accounts for 12% of all new cases of blindness. It is also leading cause of blindness in people aged 18 to 64.

Our project aims to construct a graphical user interface that can integrate image processing techniques together in order to predict whether input fundus/retinal image collected from patient is affected with Diabetic Retinopathy or not; if affected, the graphical user interface (GUI) will display the severity along with the required action needed to be undertaken by patient. This essentially reduces processing time involved in the process of detecting the disease and also the ophthalmologists can also have our graphical user interface as a backup that can be used for validating in detecting the disease

**Keywords :** Diabetic Retinopathy, Fundus, Exudate.

## Introduction:

Image Processing is widely used to diagnose the eye diseases in easy and efficient way. It also supports Ophthalmologists to screen their patients and to do clinical study as well. Major eye related diseases that cause blindness worldwide are Diabetic Retinopathy, Glaucoma, and age-related macular deterioration. In America, almost 950,000 people became blind in 2002 and 2.5 million people have visionary problems due to these diseases. The structure of blood vessels in eye retina gives the information about changes followed by these retina related eye diseases. Some of eye features, i.e..., vascular blood vessels, fovea, and optic disc are used to identify diabetic Retinopathy and other eye related diseases. Many screening tools are available to diagnose Diabetic Retinopathy. Digital fundus cameras are used to take retinal vessel images; therefore, unnecessary brightness, environment, and process of acquisition of fundus image degrade the image quality to some extent. Hence image enhancement is always required to improve quality of desired image.



**Fig 1:** Normal Vision



**Fig 2:** Same view with Diabetic Retinopathy

Certain methods are proposed by researchers to enhance the quality of the retinal images. Some of the image processing techniques used by researchers in order to diagnose eye diseases including Image Enhancement, Registration, Fusion, Segmentation, Feature Extraction, Morphology, and Classification. Image registration is used in order to detect the changes in medical images. Different images captured from different angles are aligned in single co-ordinate system in order to get submitted successfully. Image fusion is used to integrate various type of information from different

images into single image. Segmentation is used to divide an image into multiple regions on the basis of color, intensity, and objects. Image Classification is used to label group of pixels on basis of grey values or other parameters. Image analysis is used to make content of image easy to understand. Diabetic Retinopathy is one of most common eye diseases and a reason of blindness in the world. People in developed countries are mostly become victim of Diabetic Retinopathy due to lack of treatment and required resources. People with Diabetes are 25% more likely

the victim of Diabetic Retinopathy. Blood vessels, exudes, haemorrhages, Microaneurysms, and textures are the features used. These features grow when glucose level reaches to maximum limit and destroys capillaries which then leak blood in retina.

### What is Diabetes

Diabetes is a disease that occurs when your blood glucose is very high. This blood glucose is the main source of energy and comes from the food we eat. Insulin is a hormone which is made by the pancreas which helps glucose from food get into our cells which are further used for energy. Sometimes our body does not make enough insulin or doesn't use insulin well. Due to this glucose stays in our blood and does not reach our cells.

With time, having too much glucose/sugar in our blood can cause health issues. We can take steps to manage diabetes and stay healthy.

### What are the different types of diabetes?

Most familiar types of diabetes are type 1, type 2, and gestational diabetes.

#### Type 1 diabetes

If a person has type 1 diabetes, his/her body does not make insulin. As a result of this our immune system attacks and destroys the cells in our pancreas that make insulin. Type 1 diabetes is usually found in children and young adults, although it can appear at any age. People with type 1 diabetes should take insulin every day to stay alive.

### Type 2 diabetes

If a person has type 2 diabetes, his/her body does not make or use insulin well. As a result they can develop type 2 diabetes at any age, even during childhood. Nevertheless, this type of diabetes occurs most often in middle-aged and older people. This is the most common type of diabetes.

### Gestational diabetes

This diabetes develops in some women when they are pregnant. In most cases, this type of diabetes vanishes after the baby is born. But, if you've had gestational diabetes, you have a greater chance of developing type 2 diabetes later in life. Often diabetes diagnosed during pregnancy is actually type 2 diabetes.

### Other types of diabetes

Other common types include monogenic diabetes, which is an inherited form of diabetes, and cystic fibrosis-related diabetes External link.

### How common is diabetes?

Diabetes is a very common disease and it can happen to anyone. Let's take example of USA. In USA 9.4 % of the population is affected by diabetes. More than 25% of them didn't know they had the disease. Diabetes affects 25% people over the age of 65. About 90 percent of cases in adults are type 2 diabetes.

### Who is more prone to type 2 diabetes?

A person more than the age of 45 or are overweight person is more likely to develop this type of diabetes. Laziness, race, and certain health problems such as high blood pressure also affect your chance of developing type 2 diabetes. You are also more likely to develop type 2 diabetes if you had gestational diabetes when you were pregnant.

### What health problems can people with diabetes develop?

With time, high blood glucose leads to problems such as

- heart disease
- stroke
- kidney disease

- eye problems
- dental disease
- nerve damage
- foot problems

### Human Eye

Human eye is a complex and small organ that enables us to see the things around us. However, damage to this organ can put our sight in jeopardy.

Most common cause of blindness among people in the world is a condition called Retinopathy, which is caused by damage to the retina.

### About the eyes

Our eye consists of the following:

- **The iris** – the pigmented part of the eye
- **The pupil** – the black circular opening in the iris that lets light in
- **The lens** – the part behind the iris that helps to focus light on the back of the eye
- **The cornea** – a clear dome over the iris
- **The conjunctiva** – an invisible, clear layer of tissue covering the front of the eye, except the cornea
- **The retina** – delicate light-sensitive tissue at the back of your eye

### How your eye works

When we look at something, a number of processes take place before we are able to actually see that object. Firstly, light passes through

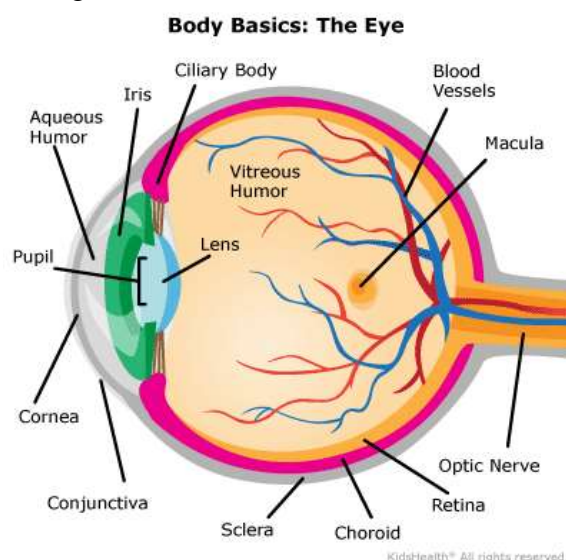


Fig 3: Human Eye

the pupil and then cornea and lens focuses this light onto the retina.

Then retina converts the light into electrical signals which are then carried to the brain via the optic nerve. Then brain interprets these signals to produce the images that you see.

Macula is another important part of human eye. It is a small, sensitive area within the retina that provides our central vision, i.e. allows us to focus for activities such as writing and reading, and to recognize colours. It is also essential for clear, detailed vision.

### Diabetic Retinopathy and its Types

Diabetic Retinopathy is a diabetes complication that affects eyes. It's caused by damage to the blood vessels of the light-sensitive tissue at the back of the eye called retina.

Initially, diabetic Retinopathy may cause no symptoms or only mild vision problems. Eventually, it can cause blindness.

The condition can be developed in anyone who has type 1 or type 2 diabetes. For more period of time you have diabetes and the less you keep in control of your blood sugar is, the more likely you are to develop this eye complication and DR.

Diabetes is the main cause which can lead to the development of a number of eye conditions, which can affect your sight.

These include: Diabetic Retinopathy [DR] – Retinopathy is a common disease or complication of diabetes and the most serious of all diabetes-related mostly affects eye conditions. It occurs when persistent high levels of blood glucose is maintain by you without treating it then it cause leaks in the capillaries that provide the retina with a constant supply of blood for functioning. This may lead to damage in the retina and stops it from working, thus affecting your vision. If left untreated without treatment of it, it can lead to total loss of sight.

Temporary blurring is the result of DR – the abnormal changes in blood sugar levels caused by diabetes can affect the lens inside the eye, which can lead to short spells of Fergus throughout the day.

Cataracts – a cataract is an eye condition that is more commonly associated with older diabetics.

It appears when the lens becomes cloudy, which causes vision to become blurred or dim because light struggles to pass through to the back of the eye.

### Symptoms

You might not have symptoms in the early stages of diabetic Retinopathy. As the condition progresses, diabetic Retinopathy symptoms may include:

- Spots or dark strings floating in your vision (floaters)
- Blurred vision
- Fluctuating vision
- Impaired color vision
- Dark or empty areas in your vision
- Vision loss

There are two main types of diabetic Retinopathy:

#### Early diabetic Retinopathy

The more common form — called non proliferative diabetic Retinopathy (NPDR) — new blood vessels aren't growing (proliferating).

When the blood vessel are not growing that means you have NPDR, which means the walls of the blood vessels in your retina weaken. Tiny bulges in your retina protrude from the vessel walls of the smaller vessels, sometimes it may result into leaking fluid and blood into the retina. Retinal vessels which are larger in size can begin to dilate and become irregular in diameter, as well. Non proliferative diabetic Retinopathy can progress from mild to severe, as more blood vessels are blocked.

In the retina the nerve fibers may begin to swell. Many times the central part of the retina (macula) which is know as macular edema begins to swell (macular edema), a condition that requires treatment.

#### Advance diabetic Retinopathy.

Diabetic Retinopathy can progress to this more severe type, known as proliferative diabetic Retinopathy. This is the type in which damaged blood vessels close off, which leads to the growth of new, abnormal blood vessels in the retina,

which may leak into the vitreous, jelly-like substance that fills the center of your eye (vitreous). Eventually, scar tissue stimulated by the growth of new blood vessels in the retina may lead to detachment from the back of your eye. The new blood vessels interfere with the normal flow of fluid out of the eye this causes the pressure to build up in the eyeball. This results in damaging the nerve that carries images from your eye to your brain which is the optic nerve, resulting in glaucoma.

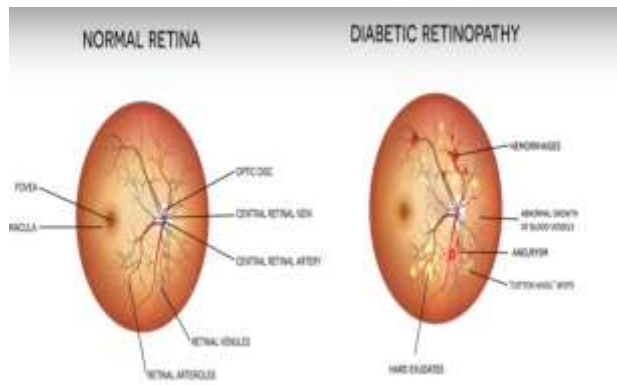


Fig 4: Difference Between Normal eye and Diabetic Retinopathic eye

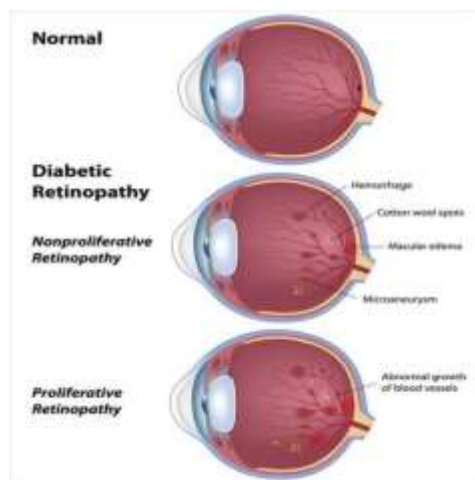


Fig 5: Types of Diabetic Retinopathy

**Literature Survey:**

The result of the paper review indicates that diabetic retinopathy affects approximately two-fifth of the population who identify themselves as having DR. Harding first detected diabetic retinopathy by screening the eye, the structure of normal and diabetic eye of the patient using an ophthalmoscope screening tool. The specificity and sensitivity obtained were 97 and 73 percent respectively. Normal features of the fundus images which included the optic disc, fovea and blood vessels. The main abnormal features of diabetic retinopathy included exudates and blot hemorrhages. Three strategies which were employed namely as thresholding, edge

detection, and classification for exudate detection. Local and global thresholding values are used to segment exudates lesions. The sensitivity and specificity calculated were 100% and 71%, respectively. There are many significant pros found out for single-field fundus photography to explain the trained readers is its potential to detect retinopathy. The sensitivity for it varies from 61% to 90% and specificity falls in the range between 85 to 97 percent. Optical disk boundary is extracted using the green and the red channel. The location methodology succeeded in 99% of cases. Segmentation algorithm rendered automated segmentations and true OD regions of 86%. Ravishankar *et al.* proposed a new methodology for optic disk detection where they first identified the major blood vessels and used the bifurcation of these to find the approximate location of the optic disk. Many classifiers have been tested including Fuzzy C-means clustering, SVM, Neural Networks, PCA, and simple Bayesian classification. GG Gardner used a back propagation neural network. Feature which re selected for the detection were exudates area, blood vessel area, hemorrhages area, and edema area. This was all performed by analyzing images of one hundred forty-seven patients with Diabetic Retinopathy and it was founded that out thirty normal retinal images with exudates, retina with hemorrhages, retinal images without blood vessels and retinal images containing blood vessels.

Previous work has been done in using machine learning and various models for automated DR screening. For development of our method and result analysis, we have conducted a literature survey describing the features of DR and past work done to detect Diabetic Retinopathy [DR].

**Giri Babu Kandeet** represented Segmentation of Vessels in Fundus Images using Spatially Weighted Fuzzy c-Means Clustering an algorithm for the extraction of Blood Vessels from Fundus images. They used a set of linear filters sensitive to vessels of different thickness and orientation. A vessel detection methods recently reported in the literature is simple and an experimental evaluation demonstrates excellent performance over global. Their algorithm were expected to be applicable to a variety of other applications due to its simplicity and general in the rule of nature because of the simplicity.

**Bob Zhang** described a method for Detecting Diabetes Mellitus and Nonproliferative Diabetic Retinopathy. In their method, the Geometry Features, Color and Texture utilized for detection are truly helpful in the extraction. The image is captured and preprocessed. Then color features are extracted from pre-processed image. To represent they had to extract the texture feature, the image is separated into eight blocks. To the surface for compute texture features we use the 2-D Gabor filter. Then the geometry features such as distances, areas are extracted from foreground image. To separate NPDR(non proliferative) samples from healthy sample, the support vector machine classifier is used. However, it only achieves 80.52% accuracy.

**Yuji Hatanaka** had presented the improvement of automatic hemorrhages detection methods using brightness correction of the fundus images. This indicated the importance of developing several automated models for finding out the abnormalities in fundus images. Purpose of this paper was to improve their automated hemorrhage detection model to diagnose [DR]diabetic retinopathy. This paper represents a new method for preprocessing and false positive elimination. They removed false positives by using a 45-feature analysis. For verifying their new method, they examined 126 fundus images, including 36 images with hemorrhages and 90 normal images. And found the sensitivity and specificity for the detection of abnormal cases was were 80% and 88%, respectively. These gave the verification results has indicated that their new method may effectively improve the performance of their diagnosis system for hemorrhages.

**Vujosevic** build a binary classifier on a dataset of 65 patients by explicitly forming single lesion features. The scope of this study is limited in the dataset.

**Wang** used a CNN(LeNet-5 architecture) as a feature extractor for addressing blood vessel segmentation. Model which he use had three heads at different layers of the convnet which then feed into three random forests. Final classifier essembled the random forests for a final prediction achieving an accuracy and AUC on 0.97/0.94 using a standard dataset for comparing models addressing vessel segmentation

**Lim** was the author who represenedt building a convolucional neural network for lesion-level classification and then use the learned feature representations for image-level classification. The only

drawback of the study is restricted therein the dataset which contains 200 images .

The authors in [13] introduced mdrawback of the study is restricted therein the dataset which contains 200 images .orphological image processing techniques to extract vessel, microaneurysm, exudate, and hemorrhage features then train an SVM on a knowledge set of 331 images achieving sensitivity 82% and specificity 86%.

P. Bhat S. Acharya et al. [14] reported sensitivity of 90% and accuracy of 90% with a dataset of 140 images using image processing techniques for extracting the world of blood vessels, area of exudates, and texture features which are then fed into alittle Neural Network.

**Report on this Investigation Complications** Diabetic Retinopathy involves the abnormal growth of blood vessels within the retina. Complications can cause serious vision problems:

- Vitreous hemorrhage. The new blood vessels may bleed into the clear, jelly-like substance that fills the middle of your eye. If the amount of bleeding is little, you'd possibly see only a couple of of dark spots (floaters). In more-severe cases, blood can fill the cavity and block your vision.
- Vitreous hemorrhages by itself don't cause permanent vision loss. The blood often clears from the attention within a couple of of weeks or months. if your retina is broken, your vision may return to its previous clarity.
- Retinal detachment. The abnormal blood vessels related to diabetic Retinopathy stimulate the expansion of tissue, which may pull the retina faraway from the rear of the

attention. this might cause spots floating in your vision, flashes of sunshine or severe vision loss.

- **Glaucoma.** New blood vessels may grow within the front an area of your eye and interfere with the traditional flow of fluid out of the attention, causing pressure within the eye to form up (glaucoma). This pressure can damage the nerve that carries images from eye to your brain (optic nerve).
- **Blindness.** Eventually, diabetic Retinopathy, glaucoma or both can cause complete vision loss.

**Data Set**

The National Eye Institute provides a standardized description of the severity class of DR patients (which are the classes that our classifier predicts). There are four severity classes, the first three describe non-proliferative DR (NPDR) and the last proliferative

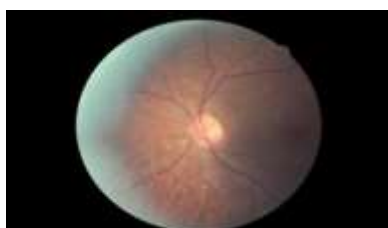DR (PDR). The severity scales are characterized through a progression of four stages.

- **Mild NPDR** - Lesions of micro-aneurysms, small areas of balloon-like swelling in the retinas blood vessels.
- **Moderate NPDR** - Swelling and distortion of blood vessels, extensive micro-aneurysm, retinal hemorrhage, and hard exudates.
- **Severe NPDR** -Various abnormalities, large blot hemorrhages, cotton wool spots and many blood vessels are blocked, which causes abnormal growth factor secretion
- **PDR** - Growth factors induce proliferation of new blood vessels inside surface of retina, the new vessels are fragile and may leak or bleed, scar tissue from these can cause retinal detachment.

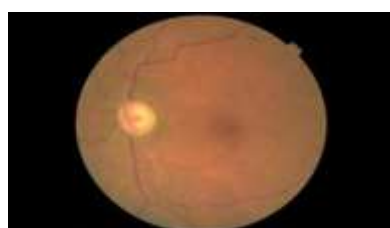This is an ongoing problem on kaggle which tries to develop a model for DR detection. Dataset is taken from the challenge-data part. Data set consists of high resolution eye images and graded by professionals in 5 classes(0-4) which is according to the table and figure given.

Class name	Meaning
Class 0	Normal Eye
Class 1	Mild DR eye
Class 2	Moderate DR eye
Class 3	Severe DR eye
Class 4	Proliferative DR eye

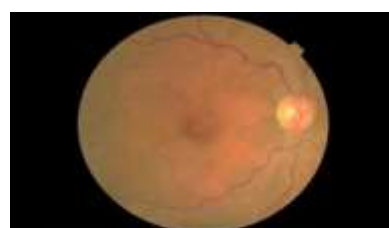**Table 1:** Class Name Descriptions




(a) Normal eye



(b) Mild DR eye



(c) Moderate DR eye



(d) Severe DR eye

(e) Proliferative DR eye

**Fig 6:** Classes (0-4) of DR affected eye

## Methodolog

### ➤ Pre-Processing

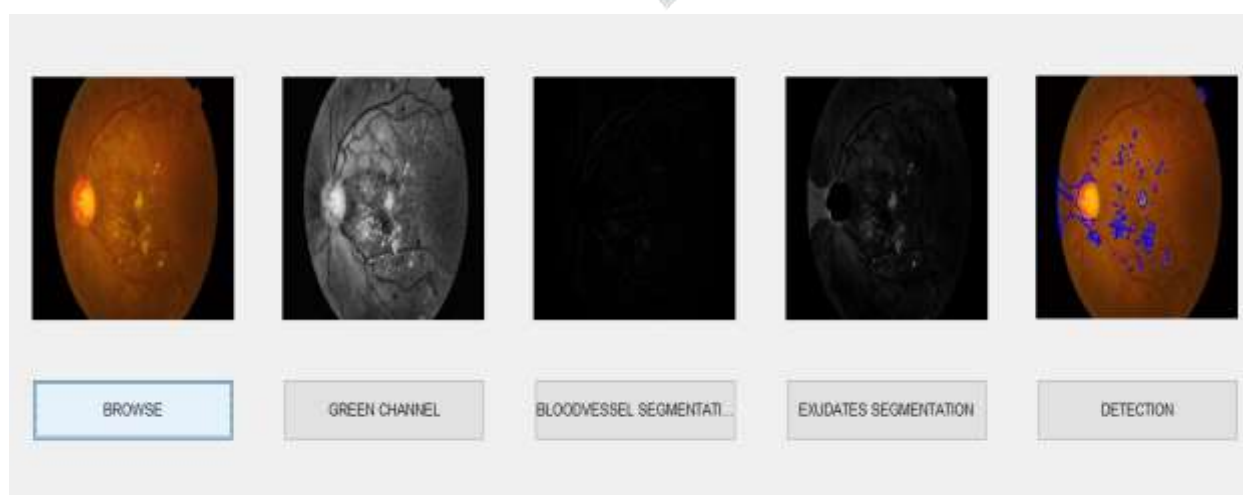
To detect the presence of diabetic retinopathy, the steps followed are preprocessing, segmentation and have ranking. Preprocessing is required to make sure that the dataset is consistent and displays only relevant features. This step is important to simplify the workload of the subsequent processes. Next, the pictures are segmented to differentiate between the traditional and abnormal substances.

### ➤ Exudates Detection

➤ Exudates Detection The method we've applied to detect exudates on human retina. Since the info set is of completely different characteristic as we've changed in various sides. that's why we are going to describe every step and therefore the reason behind taking it. Here we'd like to say that we've implemented some library provided. we've also used MATLAB version 2018a for this project and this detection consists of the subsequent steps:

➤ Preprocessing the image. Detection of blind spot and other artifacts. Detection of exudates in terms of blind spot and artifacts. within the preprocessing step first we extract intensity constituents from a picture. Here we are getting to work with gray-scale images because exudates are mostly visible in such images. And apply

Histogram Equalization to reinforce contrast and brightness. The resulting image helps us to detect blind spot and accordingly exudates. This works as input image. Exudates are high intensity values also as blind spot. Therefore so as to travel for exudates detection we'd like to seek out blind spot then we'd like to differentiate between blind spot and exudates near and inside the blind spot area. to try to to this we consider that blind spot is that the largest and most circular part in brightest portion of the image. then we've applied the morphological method of bottom hat and dress hat to extract exudates. within the last stage we plotted the difference of bottom hat and dress hat on to the first image.

**Fig 7:** Representation of Output Images



## Results and Discussions

### Results

By using eye images as dataset we get the result. Here we get the results satisfactory accordingly to our analysis. The test process takes around 15-20 seconds to run over the image with the processor Intel(R) Core (TM) i5-6200U CPU @ 2.30GHz 2.40 GHz ,installed memory (RAM) 4.00 GB (3.90 usable) and 64-bit Operating System, x64-based processor .

We are satisfied by our results although they provide slightly inaccurate findings as they provide a pretty good approach based on Image detection methods.

### Future Work

- In future in order to improve efficiently and better results I would like to employ below modifications in the project
- To use better Image processing techniques and analysis algorithms to get clearer features.
- In place of direct image features may try to use gradient of RGB layers.

### Conclusion

The Diabetic Retinopathy is regarded as the predominant optic disease that leads to blindness. Diagnosis and detection at early stage is vital for the patients. But the identification of retinal identification is really challenging for the ophthalmologists. Several image processing based techniques are employed for the DR detection. In this work, an identification technique was developed on the basis of digital image processing to obtain the fundus image from the affected retina.

A MATLAB based Image processing of the fundus into Exudates, Optical Disk was done.

### References

[1] Ryo Kawasaki et al Joanne Yau, Sophie Rogers.Diabetes Care

<http://care.diabetesjournals.org/content/35/3/556.full.pdf>, 2012.

[2] Hykin PG Fraser-Bell S, Kaines A. Update on treatments for diabetic macular edema. *Current Opinion in Ophthalmology*, 2008.

[3] Sopharak A., Uyyanonvara B., Barmanb S., Williamson TH., 2008, Automatic detection of diabetic retinopathy exudates from non-dilated retina image using mathematical morphology methods, *Computerized Medical Imaging and Graphics*, 32, 720-727

[4] SzymonNakoneczny, Mart Gerrits,Diabetic RetinopathyDetection.

[5] kaggle Challenge Diabetic Retinopathy Detection. <https://www.kaggle.com/c/diabetic-retinopathy-detection>.

[6] Mohit Singh Solanki,Dr. Amitabhamohitss, Diabetic RetinopathyDetection Using Eye Images, April 18, 2015

[7] <https://github.com/snakoneczny/diabetic-retinopathy>

[8] <https://www.ncbi.nlm.nih.gov/pmc/articles/PMC2881172/>