



LUNG DISEASE DETECTION USING X RAYS IN COVID-19 VICTIMS

¹Ritu Gill, ²Archana Rohilla, ³Yash Dhankhar

¹M.tech.deptt of computer science and engineering ,DPG institute of technology and management

Maharishi Dayanand University Rohtak, India

^{2,3}Faculty, deptt of computer science and engineering institute of technology and management, Maharishi Dayanand university, Rohtak, India

Abstract- The purpose of this project is to create a completely automated system for diagnosing lung illnesses through chest x-rays. Users and professional diagnostic centres will be able to submit chest radiographs (x-rays) and get precise predictions based on them. Chest radiography is critical for illness diagnosis. "Chest X-ray (CXR) radiography may be utilised as a first-line triage procedure for patients with pneumonia who do not have COVID-19." However, the similarity between the characteristics of COVID-19 CXR pictures and pneumonia caused by other diseases complicates radiologists' differential diagnosis. We predicted that machine learning-based classifiers could consistently discriminate COVID-19 patients' CXR pictures from those with other types of pneumonia. We utilised a dimensionality reduction technique to create a collection of optimum features from CXR pictures in order to develop an efficient machine learning classifier capable of accurately and sensitively

discriminating COVID-19 instances from non-COVID-19 cases. We successfully built our classifier using a very modest dataset of CXR pictures by using global characteristics from the whole set of CXR images. We suggest that our COVID-Classifier, in combination with other tests, be utilised to optimise hospital resource allocation via fast triage of non-COVID-19 patients.

Keywords- Lung, Disease, Xray Image, covid 19

Introduction

Numerous illnesses afflicting the global population are lung-related. As a result, research in the area of pulmonology is critical for public health studies, with a particular emphasis on infiltration, atelectasis, cardiomegaly, effusion, mass, nodule, pneumonia, and pneumothorax.

The World Health Organization (WHO) estimates that 300 million people worldwide suffer from

asthma and that the illness claims about 250 thousand lives each year (Campos and Lemos, 2009). Furthermore, the WHO estimates that 210 million individuals suffer from cardiomegaly. In 2005, the illness claimed almost 300,000 lives (Gold Cardiomegaly, 2008). Recent research indicate that CARDIOMEGALY occurs in people aged 20 to 45, despite the fact that it is often associated with those over the age of 50. According to WHO projections, the number of fatalities attributable to CARDIOMEGALY would rise 30% by 2015, and will become the third leading cause of death globally by 2030 (World..., 2014).

Early and accurate identification of any lung illness is critical for prompt treatment and prevention of future mortality in the public health system. Clinically, diagnostic assistance tools and systems are critical for the specialist and therefore for the public's health. [1-4]

The lungs' X RAY pictures show a slice of the ribcage, which contains a vast variety of structures, including blood vessels, arteries, respiratory vessels, pulmonary pleura, and parenchyma, each of which has unique information. Thus, segmenting lung structures is essential for pulmonary disease investigation and diagnosis. It's worth mentioning that segmentation is a critical stage in imaging systems for accurately diagnosing lung diseases, since it delimits lung components in X RAY pictures. Indeed, if the lung area is properly captured, image processing methods may aid in computer diagnosis. [5-6]

Following segmentation, an automated method is used to identify potential illnesses in lung X RAY pictures, assisting the radiologist with diagnosis.

According to Trindade (2009), several studies have demonstrated promising disease detection results by utilising texture descriptors extracted from the grey level concurrence matrix (GLCM) (Haralick et al., 1973) to describe three disease patterns (nodule, emphysema, and frosted glass) and a normal pattern. Shimo et al. (2010) also use GLCM texture descriptors to assess the health of the lungs. Additionally, many studies discuss the identification of particular illnesses, such as nodules (Ayres et al., 2010; Silva and Oliveira, 2010), and emphysema (Silva and Oliveira, 2010). (Felix et al., 2007, 2011). [7-10]

Methods based on machine learning (ML) have shown remarkable success in the accurate interpretation of medical pictures. Scalable, automated, and simple to deploy in clinical settings, machine learning-based methods are advantageous.

Classification of pictures with substantially comparable characteristics is a frequent application of machine learning-based image analysis. This technique is focused on segmenting the picture region of interest, identifying useful image characteristics derived from the segmented area in the spatial or frequency domain, and developing an appropriate machine learning-based classification algorithm for correctly classifying image samples.

[11-14] Several machine learning-based techniques for diagnosing COVID-19 medical pictures have been suggested recently. Wang et al. used a pre-trained deep learning network named DenseNet 121 to categorise COVID-19 imaging tests as positive or negative, achieving an accuracy of 81.24 percent. Additionally, Roy et al. investigated the use of deep learning models for

the analysis of COVID-19 infections in a limited dataset of lung ultrasonography (LUS) pictures (only 11 patients).

Zhang et al. suggested the use of a ResNet-18 classifier model to segment lung lesions in CT images for three groups of COVID-19, pneumonia, and normal, achieving a 92.49 percent accuracy. [15]

Proposed work

The system architecture is composed of cascaded modules, allowing for the implementation of alternative image analysis paths followed by late stage decision fusion. At the moment, each picture is analysed for automated lung area localization. The image characteristics are retrieved from inside the localised lung border, resulting in a two-class classification of the input CXR picture as normal or abnormal. Additionally, we are investigating other methods for identifying abnormalities in the CXR without precisely defining the lung border. " Additionally, the technique employs edge detection to identify false contours that may be suggestive of illness. Initial findings indicate that the technique is both rapid and very effective at identifying certain types of diseases.

A CAD system is typically comprised of four steps: algorithm preprocessing, ROI area extraction, ROI feature extraction, and illness classification based on the ROI features and ROI features. Methods of enhancement and segmentation are important in the development of algorithms and the extraction of return on investment (ROI). "In most cases, there are a variety of techniques for highlighting lesions and suppressing noise." The deformable model and the deep learning technique perform the best in

segmentation, while the rule-based methods perform poorly, and they are often used in conjunction with other methods to enhance segmentation performance. However, eliminating the rib and clavicle that are blocking lung anomalies may enhance the system's function. Although bone suppression methods are less often mentioned in the literature, they are effective. Regarding feature extraction, the features extracted by conventional machine learning algorithms include geometric and texture characteristics as well as form features, which are often treated to decrease the dimensionality of the data owing to feature redundancy, among other things. Hand-crafted features, on the other hand, may include mistakes that have an impact on classification performance and are progressively being replaced by deep learning techniques. Although the performance of support vector machines and random forests in traditional algorithms may be superior in terms of classifier selection, the excellent performance of deep learning methods in image classification has led to the gradual adoption of deep learning methods as the standard method for image classification. It was shown that a range of cutting-edge models and cutting-edge techniques for detecting, classifying, and evaluating various chest abnormalities were provided. The lack of large, high-quality datasets seems to be the most important impediment to reaching superhuman levels of performance in machine learning. However, the future seems promising: with larger, better-annotated datasets and new models specialised to dealing with medical images, deep learning is expected to improve the efficiency of radiologists' workflows as well as the quality of

radiological diagnoses across the world in the near future.

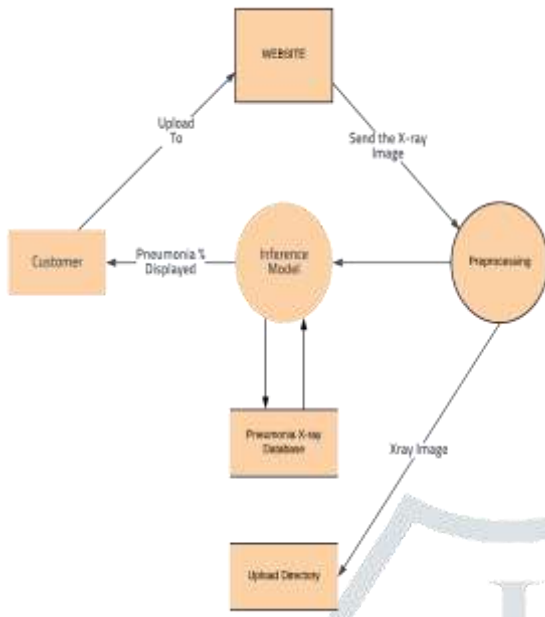


Figure 1: Design Diagram

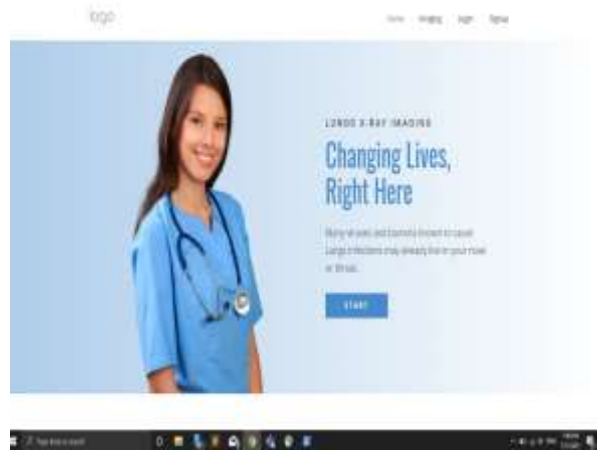

Figure 2- Demo Image

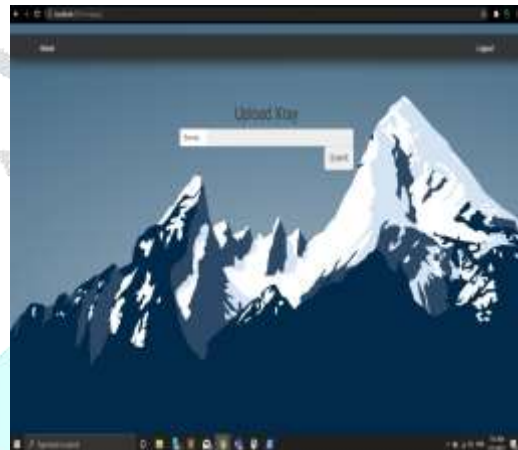


Figure 3 – uploading screen

Result:

The figure 2 to 5 shows the result screens.

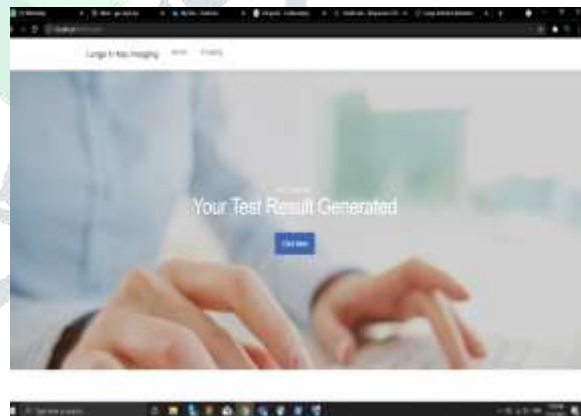
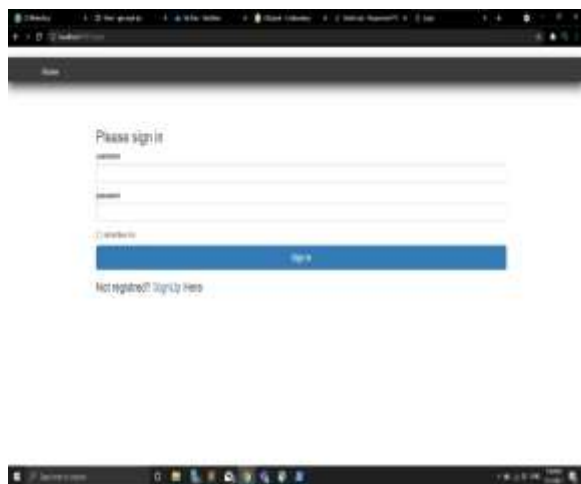
Figure 4 – test screen

Figure 1: Screenshot for gui

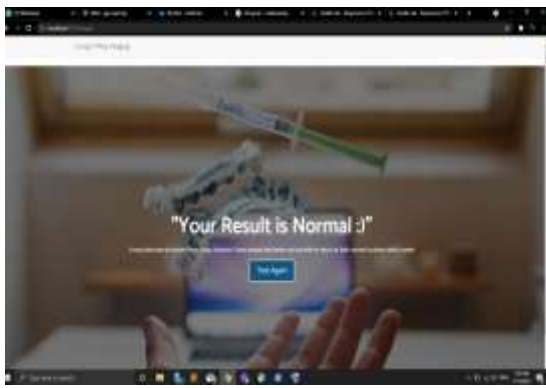

Figure 5 – Result screen

Conclusion

In a developing nation like India, it is difficult for the government to keep continuous monitoring of road conditions, and as a consequence, tiny potholes sometimes result in major accidents, sometimes resulting in fatalities. That is where our idea comes in; by marking not just the potholes on the road, but also the road conditions, we can protect users from serious accidents while also alerting the authorities to these potholes. The government may then take swift action to fix the potholes. " We look forward to continuing to develop and extend our project over time. On the basis of chest pictures, deep and machine learning techniques are very accurate in differentiating COVID-19 from non-COVID-19 pneumonia. These methods have made it possible to evaluate these pictures automatically. However, deep learning techniques lack transparency and interpretability, since the precise image feature used to create the result cannot be identified." As no one method is capable of distinguishing all pulmonary diseases solely based on the imaging appearance on chest CT scans, interdisciplinary approaches are recommended for overcoming diagnostic challenges.

References

- [1] World Health Org., Global Tuberculosis Report 2014.
- [2] World Health Organization. Tuberculosis Prevalence Surveys: A Handbook. 2011.
- [3] Stop TB Partnership, World Health Organization. The Global Plan to Stop TB 2011–2015.
- [4] Leung C. Reexamining the role of radiography in tuberculosis case finding. *Int. J. Tuberculosis Lung Disease*, 15(10):1279, 2011.
- [5] Folio, L., *Chest Imaging: An Algorithmic Approach to Learning*, Springer, 2012
- [6] Candemir, S., Jaeger, S., Palaniappan, K., Musco, J. P., Singh, R. K., Xue, Z., Karargyris A., Antani S., Thoma G., McDonald, C. J. Lung segmentation in chest radiographs using anatomical atlases with nonrigid registration. *Medical Imaging, IEEE Transactions on*, 33(2), 577-590, 2014.
- [7] Jaeger S, Karargyris A, Candemir S, Folio L, Siegelman J, Callaghan FM, Xue Z, Palaniappan K, Singh RK, Antani S, Thoma G, Wang Y, Lu P, McDonald C. Automatic tuberculosis screening using chest radiographs. *IEEE Trans. Med. Imaging*, 33(2):233–45, 2014.
- [8] Daley C, Gotway M, Jasmer R. Radiographic manifestations of tuberculosis. *A Primer for Clinicians*. San Francisco, CA: Curry International Tuberculosis Center, 2009.
- [9] Folio LR. Robochest Web Teaching Tool. Available online: www.robochest.com (last accessed 10 April 2013)
- [10] Lee KS, Song KS, Lim TH, et al. Adult-onset pulmonary tuberculosis: findings on chest radiographs and CT scans. *AJR Am J Roentgenol*. 160:753-8, 1993.

- [11] van Ginneken B, Hogeweg L, Prokop M. Computer-aided diagnosis in chest radiography: Beyond nodules. *Eur. J. Radiol.*, 72(2):226–30, 2009.
- [12] Lodwick GS. Computer-aided diagnosis in radiology: A research plan. *Investigative Radiology*, 1(1):72, 1966.
- [13] Lodwick G, Keats T, Dorst J. The coding of Roentgen images for computer analysis as applied to lung cancer. *Radiology*, 81(2):185, 1963.
- [14] Sakai S, Soeda H, Takahashi N, Okafuji T, Yoshitake T, Yabuuchi H, Yoshino I, Yamamoto K, Honda H, Doi K. Computer-aided nodule detection on digital chest radiography: Validation test on consecutive T1 cases of resectable lung cancer. *J. Digital Imaging*, 19(4):376–82, 2006.
- [15] Shiraishi J, Abe H, Li F, Engelmann R, MacMahon H, Doi K. Computer-aided diagnosis for the detection and classification of lung cancers on chest radiographs: ROC analysis of radiologists' performance. *Acad. Radiol.*, 13(8):995–1003, 2006.

