



# STUDY OF INTESTINAL HISTOPATHOLOGIES DUE TO INFESTATION OF *Caryophyllaeus laticeps* (Pallas, 1781) IN THE EXOTIC CARP, *Hypophthalmichthys molitrix* (Valenciennes, 1844)

Ganga Prasad Thakur

University Department of Zoology, LN Mithila University, Darbhanga, Bihar, India

Email: got121dbg@gmail.com

## Abstract

The current investigation was undertaken to study the intestine histopathologies due to infestation of helminth parasite cestode, *Caryophyllaeus laticeps* (Pallas, 1781) in the *Hypophthalmichthys molitrix* (Valenciennes, 1844). Only symptomatic samples of diseased fishes comprised of juvenile and adults of silver carp were collected and were brought to the laboratory for the patho-anatomical examinations. The main histopathological changes were seen in the intestine where the scolices attached, the vacuolization of the epithelial cells and rupture of the brush border and severe edema. Hyperplasia of the goblet cells and infiltration of inflammatory cells in lamina propria and its epithelium was desquamated in the infested silver carp. No changes were noticed in other organs of the affected fishes. In severe infestations the fishes showed growth retardation and mortality. Thus, it is clear that the endoparasites inhabiting intestine of *H. molitrix* produced pronounced pathological changes in host tissue, all denoting impairment of intestinal physiology.

**Key words:** *Caryophyllaeus laticeps*, histopathology, cestode, endoparasite, *Hypophthalmichthys molitrix*.

## INTRODUCTION:

In most of the fish farms, it was observed that among all fish pathogens, parasitic infestation has been the major cause of concern because of high morbidity and slow growth rate. These parasites were difficult to be removed from the culture system, causing significant setback to freshwater aquaculture. Under poor water quality conditions or stressful environment, these parasites multiply rapidly there by affecting fishes with high morbidity (Mishra, *et al.* 2017). The success and objectives of the fishery development programmes greatly depend on parasitological research and control of parasites by improving water quality since the improvement or increase in fish production/ fish yield can mainly be achieved from healthy fish stock (Thakur, 2021).

The monozoic tapeworm *Caryophyllaens laticeps* (Pallas, 1781) is a common parasite of cyprinids. The population biology of *C. laticeps* has been investigated by several authors (Kennedy 1971; Anderson 1974; Pojmanska 1984) and the morphology and fine structure has been described by Richards & Arme (1982). A light microscopical description exists of the host parasite interface of *C. laticeps* (Mackiewicz, *et al.* 1972) and the ultra structure with electron microscope by Karanis and Taraschewsk (1993).

So, the objectives of the current investigation was undertaken to study the intestine histopathologies due to infestation of helminth parasite cestode, *Caryophyllaeus laticeps* (Pallas, 1781) in the *Hypophthalmichthys molitrix* (Valenciennes, 1844).

## MATERIALS & METHODS:

Frequent incidences of naturally occurring *Caryophyllaeus laticeps* infestation was recorded in the cultivated ponds/tanks/hatcheries in Darbhanga, Bihar during the period of observation (2018-2019). Collected samples were comprised of juveniles and adults of silver carp in most of the occasions. Only symptomatic and moribund samples of diseased fishes were collected and were brought to the laboratory for patho-morphological and patho-anatomical examinations. The specimens of *C. laticeps* were counted and measured with a binocular microscope as living worms under slight coverslip pressure. After that small bits of tissues (3-4 mm thick) from the intestine etc. of moribund or freshly killed diseased fish (silver carp) samples were collected and fixed in ten percent Neutral Buffered Formalin for 18-24 hours. It was prepared by dissolving 4 gm of sodium dihydrogen phosphate and 6.5 gm of Disodium hydrogen phosphate in 900 ml of distilled water. 100 ml of formaldehyde was then added and the fixative was ready for use. Fixed tissue samples were then processed and paraffin embedded blocks of all the tissues were prepared using the standard histological methods (Luna, 1968). Calcified tissues like skin and gills were decalcified in ten percent Nitric Acid which helped in getting perfect and unbroken serial sections of these tissues during microtomy. Tissue blocks were cut into serial sections (5-7 thick) by a rotary microtome. For routine staining of the histological sections, Ehrlich's Haematoxylin (H.) and alcoholic

Eosin (E.) stains were prepared and used according to Luna (1968). Photomicrographs of the most characteristic regions of histopathological lesions in the stained tissues of diseased fish samples were taken.

## RESULT:

This disease has been found to occur predominantly in the juvenile in the fish culture ponds. The disease is caused by a cestode, *Caryophyllaeus laticeps* which attracted particularly the intestine of the fishes.

**Fish Species affected:** juveniles and adults of exotic carp, *Hypophthalmichthys molitrix* has been found to be affected by this disease.

**Clinical Symptoms and Gross pathology:** Highly affected fishes showed growth retardation, weight loss, lethargic swimming behaviour, loss of appetite and tendency to take shelter near pond margin.

## Histopathology:

The normal intestine sections of the host fish *Hypophthalmichthys molitrix* showed ordered architecture and cellular organization of the cells constituting atypical teleostean intestine (Figure-1.). Exhibited well ordered arrangement of the usual four layers i.e., serosa, muscularis, submucosa and mucosa. The mucosa is formed of columnar epithelial cells thrown into a number of folds or villi. The nuclei occupied basal position. The submucosa, constituted of loose connective tissue, forms the central core of the villi known as lamina propria. The submucosal cells are granular, richly vascular and eosinophilic in nature. The muscularis is composed of outer thin longitudinal muscles and inner thick circular muscles. The outer most thin vascular covering is the serosa shows distinct mucus secreting and brush border cells (Figure-1.).

The intestinal epithelium of the infected host fish was found to be locally compressed by the pressure of scolices. Besides, at the site where scolices attached, the aculization of the epithelial cells and rupture of the brush border were quite prominent and severe edema was also apparent (Figure-2.). Besides, infiltration of eosinophilic granulocytes formed an important pathological changes due to infestation of *Caryophyllaeus laticeps*. Macroscopically, excess mucus secretion and shedding of host tissues were clearly apparent. Again cellular infiltration, particularly of fibroblasts, was also noted at the site of attachment (Figure-3). Further, there was infiltration of inflammatory cells in lamina propria and its epithelium was desquamated. Besides, hyperplasia of goblet cells was also obvious (Figure-4). Other vital organs of the affected samples did not show any histopathological changes.



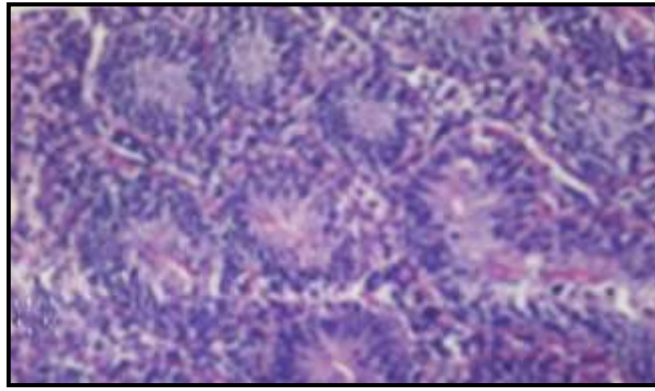


Figure-1.: T. Section of normal intestine of *Hypophthalmichthys molitrix* showing normal cellular organization H. & E., X 400.

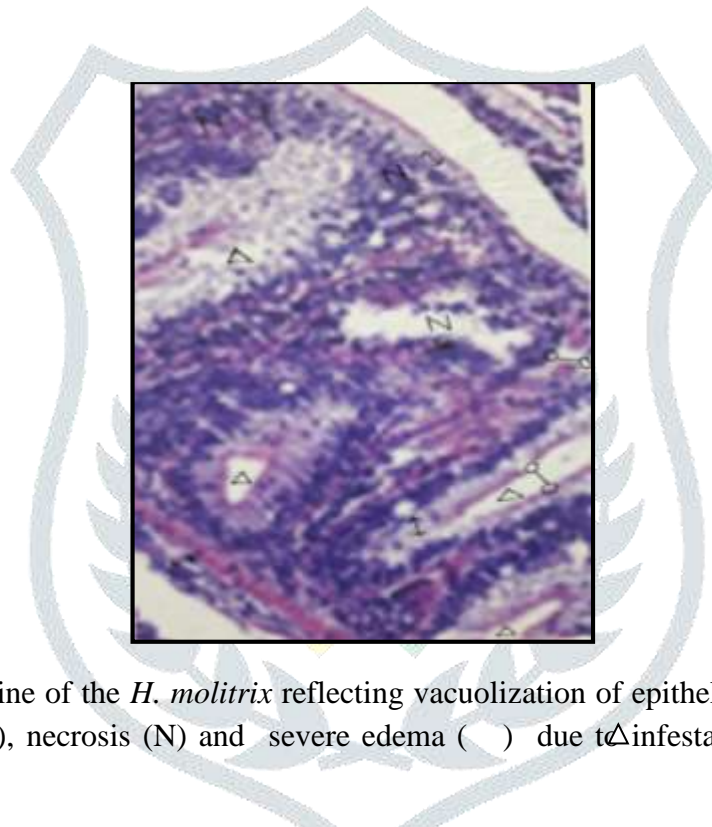


Figure- 2.: T.S. of intestine of the *H. molitrix* reflecting vacuolization of epithelial cells (  $\triangle$  ) rupture of brush border cells (o-o), necrosis (N) and severe edema ( ) due to infestation of *Caryophyllaeus laticeps*. H. & E., X 400.

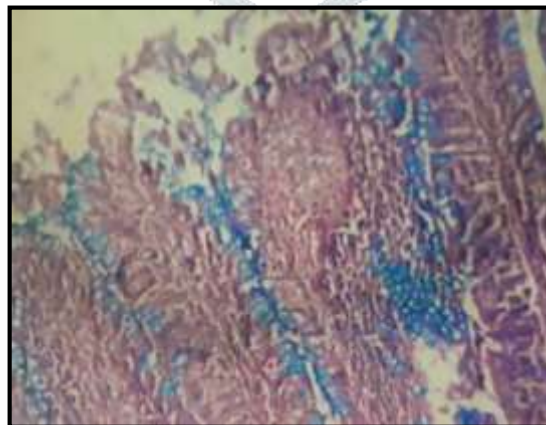


Figure- 3.: Infiltration of inflammatory cells in lamina propria in intestine of *H. molitrix* due to infestation of *Caryophyllaeus laticeps*. H. & E., X 400.

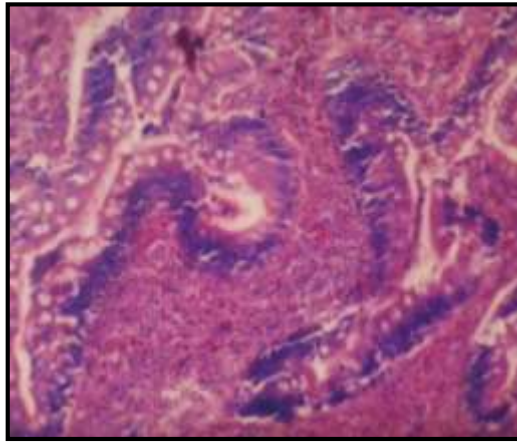


Figure- 4.: *Caryophyllaeus laticeps* induced hyperplasia of goblet cell and desquamated epithelial cells in intestine of *H. molitrix*. H. & E., X 400.

## DISCUSSION:

The present study describes the histopathologies due to the infestation of *Caryophyllaeus laticeps* (Pallas, 1781) in the silver carp, *Hypophthalmichthys molitrix*. *C. laticeps* is a monozoic tapeworm of class cestoda under the family caryophyllidae. It was found to parasitize large numbers of cyprinid fishes (Gibson, 2013) of European countries, North Africa and West Asia (Hanzelova *et al.*, 2015) but now has almost worldwide distribution.

The host-parasite interface shows much of the tissue alteration caused by *C. laticeps* seems to be related to its mode of attachment. Like other members of family this caryophyllid has no specific organs of attachment such as loculi, acetabula or bothria. Thus, in absent of such organs, it apparently effects attachment by gripping numerous small portions of the intestinal epithelium of host ensuring a very tight host-parasite interface. Resulted, the epithelial cells undergo heavily compressed, and eventually degenerate. The intermediate layer between the scolex and the epithelial brush border called the 'mucoïd layer' might have an adhesive function in addition to mechanical attachment (Mackiewicz *et al.* 1972; Hayunga 1979). In the present investigation similarity found, it is shown that the parasite as well as the host contributes to this layer.

The intestine of the *Hypophthalmichthys molitrix* infected with *C. laticeps* revealed vacuolization in the epithelial cells, ruptured brush borders, infiltration of eosinophilic granulocytes and fibroblasts at the site of attachment, hyperplasia of goblet cells and hyper secretion mucus observed in present study resemble those of Wali *et al.* (2016).

In the present investigation, the hosts' cellular defense reaction against the worms, such as the accumulation of eosinophilic granulocytes, is a normal reaction of fish against a parasite (Rowley and Mainwaring 1988; Karanis and Taraschewsk 1993).

## CONCLUSION:

The findings accomplished that infestation by cestode, *Caryophyllaeus laticeps* was observed predominantly in the rearing/ stocking ponds. Juveniles and adults silver carp was found susceptible to this disease. The intestinal histopathologies of the *H. molitrix* infected with *C. laticeps* revealed vacuolization in the epithelial cells, ruptured brush borders, infiltration of eosinophilic granulocytes and fibroblasts at the site of attachment, hyperplasia of goblet cells and hyper secretion mucus observed.

## ACKNOWLEDGEMENT:

The authors are thankful to the University Department of Zoology, LN Mithila University, Darbhanga, Bihar, India, for the provision of laboratory facilities used in this study.

## REFERENCES:

- Anderson R. M. 1974: Population dynamics of the cestode *Caryophyllaeus laticeps* (Pallas 1781) in bream (*Abramis brama*, L.). *Journal of Animal Ecology* 43, 305 — 321.
- Gibson, D.I. 2013: Fauna Europea: Caryophyllidea, *Caryophyllaeus laticeps*. Fauna Europea Version 2.6.2, [www.faunaeur.org](http://www.faunaeur.org).
- Hanzelova, V., Oros, M., Barcak, D., Miklisova, D., Kirin, D. and Scholz, T. 2015: Morphological polymorphism in tapeworms : Redescription of *Caryophyllaeus laticeps* (Pallas, 1781) (Cestoda: caryophyllidea) and characterization of its morphotypes from different fish hosts. *Systematic parasitology*, 90:177-190.
- Hayunga E. G. 1979: Observations on the intestinal pathology caused by three caryophyllid tapeworms of the white sucker *Cotostomus commersoni* Lacepede. *Journal of Fish Diseases* 2, 239-248.
- Karanis P. and Taraschewsk, H., 1993: Host-parasite interface of *Caryophyllaeus laticeps* (Eucestoda: Caryophyllidae) in three species of fish. *Journal of Fish Diseases* 1993, 16, 371-379.
- Kennedy C. R. 1971: The effect of temperature upon establishment and survival of the cestode *Caryophyllaeus laticeps* in orfc, *Leuciscus idus*. *Parasitology* 63, 59—66.
- Luna, G. 1968 : Manual of histologic staining methods of the Amerd Forces Institute of Pathology, 3<sup>rd</sup> Edition , McGraw–Hill Book Company, New York.
- Mackiewicz S. J., Cosgrove E. G. & Grude D. W. 1972: Relationship of pathology to scolex morphology among caryophyllid cestodes. *Zeitschrift fur Parasitenkunde* 39. 233-246.
- Mishra SS, Das R, Choudhary P, Debbarma J, Sahoo SN, *et al.* 2017 : Prevalence of Fish and Shrimp Diseases and Use of Various Drugs and Chemicals in Indian Aquaculture for Disease Management. *J Fish Aqua Dev: JFAD-129*. DOI: 10.29011/JFAD-129. 100029.

- Pojmanska T. 1984: An analysis of seasonality of incidence and maturation of some fish parasites, with regard to thermal factor. II. *Caryophyllaeus laticeps* (Pallas, 1781). *Acta Parasitologica Polonica* 26, 229-239.
- Richards K. S. & Arme C. 1982: The microarchitecture of the structured bodies in the tegument of *C. laliceps*. *Parasitology* 68. 425-432.
- Rowley A. F., Hunt T. C , Page M. & Mainwaring G. 1988: Fish. In: *Vertebrate Blood Cells* (ed. by A. F. Rowley & N. A. Ratcliffe). pp. 19-129. Cambridge University Press. Cambridge.
- Thakur, G. P. 2021: Studies on Helminth Parasites In Some Exotic Major Carps Of Darbhanga Region. Ph.D. Thesis, LNMU, Darbhanga.
- Wali, A., Balkhi, M. H., Maqbool, R., Sah, F.A., F.A., Darzi, M. M., Kumar, A. and Bhat, B.A. 2016: Histopathological alterations and distribution of *Pomphorhynchus kushmirensis* in intestine and their seasonal rate of infestation in three freshwater fishes of Kashmir. *Jour. Of Entom. & Zool. St.* 4: 22-28.

