



FORMULATION AND EVALUATION OF MEDICATED NAIL LACQUER OF *C. QUADRANGULARIS* FOR TREATMENT OF ONYCHOMYCOSIS.

¹Walunj Shubhangi Bhausahab, ²Kute Navnath Baban, ³Bhand Mayur Babasaheb, ⁴Khade Alka Balu, ⁵Paimode Prajka Balu.

¹UG Scholar, ²UG Scholar, ³UG Scholar, ⁴UG Scholar, ⁵Assistant Professor
Matoshri Miratai Aher college of Pharmacy, Karjule Harya, Tal- Parner, Dist- Ahmednagar,
Maharashtra.

ABSTRACT: To cure onychomycosis, an attempt was undertaken to make a transparent nail lacquer containing a natural antifungal ingredient extracted from the complete plant of *Cissus quadrangularis*. Onychomycosis (also known as dermatophytic onychomycosis or *Tinea unguis*) is a fungal infection of the nail. The causative pathogens of onychomycosis include dermatophytes, *Candida*, and nondermatophytic molds. In the present work, a medicated antifungal nail lacquer of *C. quadrangularis* has been developed. The objective of the study was to deliver a sustained release of antifungal extract over extended period of time up to 48 hours, and hence reduce the frequency of administration. This was expected to improve clinical efficacy and also improve the patient compliance. The nail lacquer formulations were prepared by simple mixing and analyzed for non-volatile content, gloss, smoothness to flow, drug diffusion studies, drug content estimation, anti-microbial studies. Among all formulations, nail lacquer prepared with *C. quadrangularis*, nitrocellulose, ethyl cellulose, salicylic acid, propylene glycol and dibutyl phthalate exhibited good non-volatile content, drug release, drug content estimation and zone of inhibition. *C. quadrangularis* extract was tested for antifungal activity against *Candida albicans*. Minimum inhibitory concentration of extract against *Candida albicans* was performed to get the amount of extract to be loaded in the nail lacquer. The extract was also subjected to a phytochemical analysis, which included test for steroids, glycosides, and flavonoids. With constant stirring, nail lacquer was made from nitrocellulose, ethyl cellulose, ethyl acetate, salicylic acid, dibutyl phthalate, *C. quadrangularis* extract, and acetone. Fluconazole nail lacquer was made and compared to the formulation. Drying time, gloss, non-volatile content, water resistance, viscosity, and flow smoothness were all examined in nail lacquer formulations. A goat nail was used to conduct an in-vitro transungual permeation research. Results: The extract contained phytoconstituents such as flavonoid and quinine. The antifungal activity of nail lacquer and fluconazole formulations against *Candida albicans* was found to be satisfactory (zones of inhibition of 202mm at 50mg/ml and 161mm at 40mg/ml, respectively). The formulation dried in 62-70 seconds, and the glossiness of the formulation was visible. The nail lacquer formulation demonstrated good non-volatile content, water resistance, and viscosity with smooth flow. In-vitro permeation of the F7 formulation revealed 90.9 percent penetration within 24 hours.

Key Words: *Cissus quadrangularis*, onychomycosis, Nitrocellulose, Ethyl cellulose, *Candida Albicans*, Nail Lacquer, etc.

INTRODUCTION

Onychomycosis may be a contagious infection of the fingernails and toenails that affects just about nineteen of the world's population.¹ This infection principally affects diabetics and also the older. Dermatophytes, non-dermatophytes, moulds, and yeast, notably candida, square measure the foremost common causes.² Onychomycosis affects concerning eightieth of cases, primarily toenails.³ Onychomycosis is a lot of common in polygenic disease patients than in non-diabetic patients. The patient's unhealthy nail has broad, sharp edges that infect the encompassing skin tissue, inflicting erosion of the nail bed four.⁴

Over the last decades the treatment of un wellness has been accomplished by administrating medication to frame via numerous routes particularly oral, parental, topical, inhalation etc. each medical condition demands associate degree correct and applicable treatment. As a matter of truth, the thought of partitioning the patient's sickness with least damage done to the patient's health is claimed to be the fundamental goal of any medical aid. what is more a decent treatment technique necessitates thorough data of materia medica and pharmacodynamics of the supposed drug. thus we have a tendency to struggle day to day unrelentingly to analysis and higher our techniques and technology to develop with the most effective mode of treatment guaranteeing quick recovery moreover as reassuring safety of the patient. Human nails don't have solely protecting and ornamental role, however may be thought of as an alternate pathway for drug delivery, particularly in nail diseases like onychomycosis or skin disease. These nail diseases square measure wide unfold within the population, notably among older and immune-compromised patients. though the design and composition of the nail plate severely limits penetration of medication and additionally to it solely a fraction of topical drug penetrates across the nail, oral therapies square measure among general facet effects and drug interactions. For the fortunate treatment of nail sickness the applied active drug should permeate through the dense keratinized nail plate and reach deeper layers, the nail bed and also the nail matrix.⁵

The inadequate analysis and data concerning the properties of keratinized nail plate, the nail bed and also the nail matrix caused a lesser specialize in horny structure system. bodily structure nail plate is accountable for penetration of drug across it. because it is tough} enough the penetration becomes difficult, solely a fraction of topical drug penetrates across it. thus the effective therapeutic concentration isn't achieved. The nail plate might seem abnormal as a results of attenuated glow. it's because of the involvement of nail bed, reduction of blood provide, physical or chemical options of nail bed. As a result, form of diseases happens. These diseases may be cured by achieving desired therapeutic concentration of drug by nail drug delivery system.⁶

Major challenges of drug delivery to the nail (ungual drug delivery), with the shortage of understanding of each the barrier properties of the nail and formulations to attain increased horny structure delivery proscribing the potency of topical treatments for nail disorders. And additionally suffer from low patient compliance because of the long treatment periods (up to 4-8 months) that square measure needed. However, existing oral formulations generally contain massive doses of active ingredients and additionally need long treatment, making the potential for general toxicity particularly within the liver. Thus, developing simpler ways for nail drug delivery is a crucial objective for the pharmaceutical trade.⁷

1.1 STRUCTURE OF THE HUMAN NAIL ⁸

The human nail consists of

Nail matrix or the root of the nail

Nail bed

Eponychium or cuticle

Paronychium

Hyponychium

Nail plate

Lunula⁹

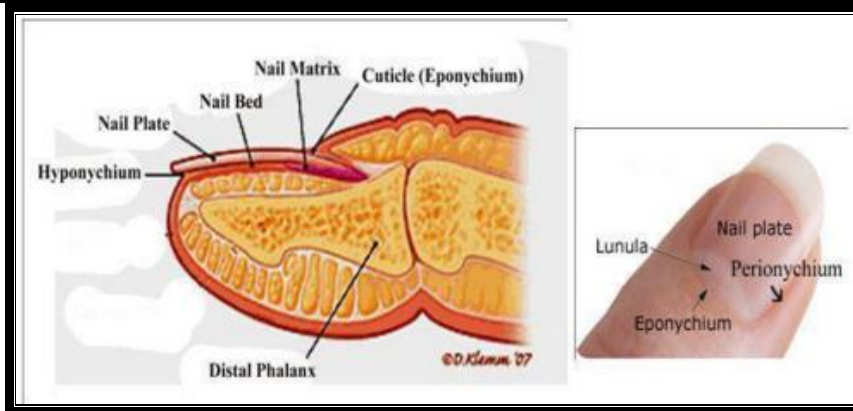


Fig. no. 1 Structure of human nail

1.2 Nail Diseases:

A) congenital deformity, skin illness involving the nail bed, systematic disease, reduced blood flow, local trauma, tumours of the nail fold or nail bed, infection of the nail fold, infection of the nail plate can all cause the nail plate to appear aberrant. There are a variety of nail ailments, including Green-nail syndrome is an infection caused by *Pseudomonas aeruginosa*.¹¹

(B) Paronychia :

1) Acute paronychia: A bacterial infection, such as *S. aureus* or Group A streptococci, causes erythema, edoema, and throbbing pain in the nail fold.

2) Chronic paronychia: Most people with chronic paronychia have their hands in water all of the time, with frequent small trauma injuring the cuticle, allowing irritants to further destroy the nail fold. Infection is a commonly becomes infected especially with *C. albicans* or *Pseudomonas* spp. (produces a green or black discoloration)¹²

C) Parakeratosis pustulosa: Showing subungual hyperkeratosis and onycholysis^{13,14}

D) Nail Psoriasis: Scaly skin, the nail plate becomes pitted, dry and often crumbles and also appears red, orange or brown, with red spots in the lunula.

E) Yellow nail syndrome: A rare condition characterized by yellow nails with lack of cuticle, grows slowly, and is loose or detached associated with onycholysis in one or more nails .

F) Onychomycosis:^{6,7} Onychomycosis accounts for one third of integumentary fungal infections and one half of all nail disease. *Tinea unguium* is more than a cosmetic problem, although persons with this infection are often embarrassed about their nail disfigurement. Because it can sometimes limit mobility, onychomycosis may indirectly decrease peripheral circulation, thereby worsening conditions such as venous stasis and diabetic foot ulcers. Fungal infections of the nails can also spread to other areas of the body and, perhaps, to other persons.^{16,18}

1.3 ETIOLOGY¹⁷

The contributing pathogens of onychomycosis embrace dermatophytes, *Candida*, and nondermatophytic molds. Dermatophytes are the fungi most ordinarily liable for onychomycosis within the temperate western countries, whereas fungus and nondermatophytic molds are a lot of oft concerned within the tropics and semitropics with hot and wet climate.

Dermatophytes:

Trichophyton rubrum is that the commonest dermatophyte concerned in onychomycosis. different dermatophytes which will be concerned are unit genus *Trichophyton interdigitale*, *Epidermophyton floccosum*, genus *Trichophyton violaceum*, *Mycosporum gypseum*, *tonsurans* and *Trichophyton soudanense*.

Other pathogens

Other contributing pathogens embrace fungus and non dermatophytic molds, particularly members of the mould generation *Scytalidium* (name recently modified to *Neoscytalidium*), *Scopulariopsis*. fungus in the main causes nail onychomycosis in folks whose hands are unit usually submerged in water. *Scytalidium* in the main effects folks within the tropics, although it persists if they later move to areas of temperate climate.

Risk factors:

Risk factors for Onychomycosis embrace case history, increasing age, poor health, previous trauma, heat climate, participation in fitness activities, immunological disorder (e.g., HIV, drug induced), communal bathing, and occlusive footwear.

1.4 CLASSIFICATION OF ONYCHOMYCOSIS ^{6,8}

A. Distal Subungual Onychomycosis- the foremost common style of ringworm is distal subungual. Distal subungual onychomycosis could develop within the toenails, fingernails or each. The infection is typically caused by genus *Trichophyton rubrum*, that invades the nail bed and also the face of the nail plate, starting at the hyponychium so migrating proximally through the underlying nail matrix. status to distal superficial onychomycosis could occur in Associate in Nursing chromosome dominant pattern among families.**5A**

B. White Superficial Onychomycosis - White superficial onychomycosis accounts for less than ten % of onychomycosis cases. White superficial onychomycosis is caused by sure fungi that directly invade the superficial layers of the nail plate and kind well-delineated opaque “white islands” on the plate. because the unwellness progresses, these patches coalesce to involve the whole nail plate. The nail becomes rough, soft and breakable. the foremost common contributing agent is genus *Trichophyton mentagrophytes*. this kind of onychomycosis will be treated with topical antifungal medication alone.**5B**

C. Proximal Subungual Onychomycosis - Proximal subungual onychomycosis happens once the infecting organism, usually *T. rubrum*, invades the nail unit through the proximal nail fold, penetrates the freshly shaped nail plate so migrates distally. Fingernails and toenails area unit equally affected. this way of onychomycosis typically happens in immune compromised persons and is taken into account a clinical marker of human immunological disorder viral infection. proximal subungual Date 2022-06-18 Words 960 Characters 6886 Page 1 of 2 onychomycosis may arise secondary to native trauma.**5C**

D. Candidal Onychomycosis

(i) Infection beginning as a paronychia (infection of the structures surrounding the nail; also called a “whitlow”), the most common type of *Candida* onychomycosis.

(ii) Patients with chronic mucocutaneous candidiasis are at risk for the second type of *Candida* onychomycosis, called *Candida granuloma*, which accounts for less than 1% of onychomycosis. This condition is seen in immune compromised patients and involves direct invasion of the nail plate. (ii) *Candida* onycholysis can occur when the nail plate has separated from the nail bed. Distal subungual hyperkeratosis can be seen as a yellowish gray mass lifts off the nail plate.

E. Total Dystrophic Onychomycosis Total dystrophic onychomycosis may be the end result of any of the four main forms of onychomycosis.**5D**

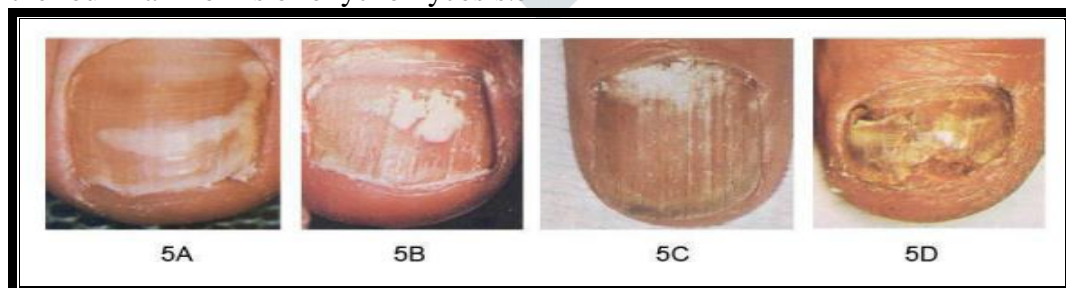

Fig. no. 2 Classification of Onychomycosis

1.5 CLINICAL FEATURES ¹⁷: The nail plate will have a thickened, yellow or cloudy look. The nails will become rough and breakable, or will break away the nail bed. there's typically no pain or different bodily symptoms, unless the unwellness is severe. Dermatophytids area unit plant-free skin lesions that typically kind as a results of a fungus infection in another a part of the body. this might take the shape of a rash or itch in a vicinity of the body that's not infected with the plant. Dermatophytids will be thought of as Associate in Nursing hypersensitivity to the plant. folks with onychomycosis could expertise vital psychosocial issues because of the looks of the nail. this is often notably augmented once fingernails area unit affected.

1.6 DIAGNOSIS OF ONYCHOMYCOSIS: standard strategies for distinguishing flora organisms within the nail plate of patients with onychomycosis (OM) embrace direct research (after caustic potash answer incubation), flora culture, and histopathology (using oxyacid Schiff [PAS] stain). Surgical pathology testing (of the subungual nail bed and/or the nail plate) exploitation PAS stain is that the current gold customary (approaching 100% sensitivity) for the diagnosing of OM. Newer strategies for identification OM embrace enzyme chain reaction (which contains a terribly high specificity), optical coherence pictorial representation, confocal optical device scan research, matrix- aided optical device desorption/ionization time-of-flight mass spectrum analysis (MALDI-TOF MS), and section distinction arduous x-ray research. Confirmation of observations and handiness and value should be thought-about before these newer strategies for identification OM will be incorporated in clinical follow

1.7 TREATMENTS OF ONYCHOMYCOSIS ^{18,19,20} Several modalities can be used for the treatment of onychomycosis topical therapy, systemic therapy, combination therapy, and nail removal. Patients greater than 55 years of age may have a higher rate of relapce.

1.7.1 Nail removal, avulsion : Removal of diseased nails can be used as an adjunctive therapy but not as the sole therapy for onychomycosis. Surgical nail avulsion is rarely used to treat onychomycosis in diabetic patients because of their increased risk for secondary infections, gangrene, and poor wound healing. However, in severe or refractory cases, nail removal may be used. It may also be used when oral therapy is contraindicated or ineffective.

Demerits of surgical treatment

Surgical nail avulsion can bring severe pain and further trauma to the patient. Surgical removal of the nail plate (fingernail or toenail) is not effective treatment of onychomycosis without additional therapy. This procedure should be considered only an adjunctive treatment combined with oral medical therapy.

1.7.2 Oral therapy

Many studies have evaluated systemic treatments for onychomycosis in the general population. Oral agents are absorbed via the circulation through the nail bed and take nearly 7 days to reach minimal inhibitory concentration (MIC). Once administration of the drug is discontinued, it can remain active in the nail for up to 90 days, and the nail does not need to be completely clear before the medication is stopped. Griseofulvin was the standard oral therapy for onychomycosis for more than 30 years. However, it has a narrow therapeutic window and significant adverse reactions. It also has several interactions with other drugs and is active only against dermatophytes, with a cure rate of less than 40%. For these reasons, it is rarely used today to treat onychomycosis. The imidazole class of medications is active against most of the organisms that cause onychomycosis. Ketoconazole is slightly more efficacious than Griseofulvin but also has many adverse effects and drug interactions. It is rarely used to treat onychomycosis today. Fluconazole, 300mg once a week for 6 months, is more efficacious and has been shown to be safe. Itraconazole, a triazole antifungal, binds more specifically to fungal cytochrome P-450 than other azoles, reducing the incidence of side effects. It is active against dermatophytes *Candida* and *Aspergillus* but not *Scytalidium*, a mold. Because of the high cost of Itraconazole, a pulse regiment has been formulated and tested. Pulse treatment involves using 200 mg twice daily for 1 week during each of 2 months in fingernails and 3 months in toenails. Pulse therapy has been reported to be just as effective as continuous therapy with fewer adverse events and half the cost. Terbinafine, 250 mg once daily for 3 months, has been shown to achieve a mycological cure rate of 82% in toenail onychomycosis and 71% in fingernail onychomycosis.

Table No.1: Treatment and mycological cure rates

Treatment	Mycological cure rates
Terbinafine(continuous)	76 %(±4%)
Itraconazole(pulse-dose)	63 %(±7%)
Itraconazole(continuous)	59 %(±5%)
Griseofulvin	40 %(±6%)
Fluconazole	48 %(±5%)
Miconazole	53.4 %(±7%)

Disadvantages of oral therapy

Oral therapy is followed by some disadvantages such as drug interactions, contraindications, side effects, high cost of medication, and a long duration of treatment. Moreover, systemic use of azoles can be linked to hepatotoxicity, especially during prolonged use.

1.7.3 Topical therapy

There are three classes of topical antifungal creams: polyenes (e.g.Nystatin), imidazoles (e.g.Clotrimazole), and allylamines- benzylamines (e.g.Terbinafine).

All three are active against *Candida*, but only imidazoles and allylamines benzylamines are active against dermatophytes. In general, topical therapy is not adequate for clearing nail infections, probably because of inadequate penetration of the medication into the affected tissues and nail bed. The exception to this is superficial white onychomycosis, which is easily treated with a topical agent because the organism grows on the upper nail plate rather than in the nail bed.

Antifungal nail lacquers are available for treating onychomycosis and penetrate the nail better than creams and gels. One lacquer contains the active ingredient Amorolfine, which is in a new class of antifungals, the morpholines. Another lacquer contains Ciclopirox, which has a broader spectrum of activity. Nail lacquers are applied daily for 48 weeks and once-weekly removal with nail polish remover is required.

Demerits of topical therapy

- They should be reserved for mild distal disease in up to two nails, or for superficial white onychomycosis, or where there are contra-indications to systemic therapy.
- Treatment should be given daily for six months to one year
- Topical therapy often fails due to poor penetration through nail plate and provide less contact time.^{24,25}

Materials and Methods:

Fresh plant of *C.quadrangularis* were collected in the month of November 2021 from Khare - karjune district of Ahmednagar,India,It was authenticated through botanist and sample deposited in Herbarium of Balasaheb Jadhav Arts, Commers and science College,Ale.

Table no. 2 material used in formulation

SR.NO.	MATERIAL USED
1	<i>C. quadrangularis</i> extract(%)
2	Nitrocellulose
3	Ethyl cellulose
4	Salicylic acid
5	Ethyl Acetate
6	Dibutyl Pthalate
7	Acetone

METHODES:

Identification test of phytoconstituents: The extract was identified for phytoconstituent test such as steroids, phenols, flavonoids, quinones

- 1) The **steroids** test was performed by treating the extract with few drops of concentrated sulphuric acid to get red color.
- 2) To identify of **phenols**, extract was treated with 3-4 drops of ferric chloride solutions to get in bluish black color.
- 3) The **flavonoids** test was performed by treating extract with few drop of lead acetate to get yellow precipitate.
- 4) For the presence of **quinines**, extract was treated with concentrated HCl to get yellow precipitate.²⁰

Antifungal activity of *Cissus quadrangularis* extract:

Antifungal activity of CQE was determined against *Candida albicans* by cup plate method, evaluated. The sterilized sabouraud dextrose media was poured to the sterilized petri plates and allowed to set. *C. albicans* was inoculated on the media in aseptic condition. Wells were prepared aseptically with sterilized cork borer and filled with each 0.5ml solution of DMSO containing extract of CQE ranging from 10mg/ml to 50mg/ml. Plates were kept for pre-diffusion in refrigerator for 15 min. After normalized room temperature, all plated were incubated at 30°C for 48 hr and zone of inhibition (diameter in mm) was measured.^{23,25}

Formulation of nail lacquer :

Nitrocellulose and ethyl cellulose were dissolved in sufficient quantity of ethyl acetate to get clear solution. Salicylic acid was dissolved in above mixture and dibutyl phthalate was added. Then extract of *C. quadrangularis* and acetone were added with continuous stirring at 100 rpm on magnetic stirrer. The formulations were coded as F1 to F4. Finally, sufficient quantity of ethyl acetate was added to get proper consistency to nail lacquer (Figure 6).²⁶



Fig no. 3 nail lacquer

Table no. 4 Formulation of nail lacquer

Sr.no.	Ingredients	F1	F2	F3	F4	F5
1	<i>C. quadrangularis</i> extract	0.05	0.05	0.05	0.05	0.05
2	Nitrocellulose	2	2	2	2	2
3	Ethyl cellulose	1	1	1	1	1
4	Salicylic acid	0.35	0.40	0.50	0.60	0.70
5	Ethyl acetate	0.5	0.5	0.5	0.5	0.5
6	Dibutyl phthalate	0.2	0.2	0.2	0.2	0.2
7	Acetone	0.1	0.1	0.1	0.1	0.1

IV. EVALUATION PARAMETER

1) **Non-volatile content** - Non-volatile content of F1 to F5 was determined to get the weight of formulation that retained on nail plate after application. Nail lacquer (1 g) was taken in a glass petri dish of about 8 cm in diameter. Sample was spread equally using brush. The dish was put in an oven at 105°C for 1 hr, cooled and weighed. The difference in weight of sample before and after drying was the non-volatile content present in the nail lacquer.²³

2) **Lacquer film thickness** - One ml of formulation was spread equally with an applicator brush in 8 cm diameter petri dish and was allowed to dry at room temperature. After drying nail lacquer film was isolated from the petri dish. The film thickness was measured at three different places using a micrometer screw gauge and average was calculated.²⁴

3) **Drying time and gloss** - An area of 4×4.5 cm² was marked on glass petri dish to which a film of nail lacquer formulation and marketed product was applied with the help of brush. The time taken for the film to dry was noted using a stopwatch. The readings were obtained in triplicate.²⁵ Glossiness was determined by visual inspection and measured as follows: good (++) , very good (+++) and excellent (++++). It was compared with marketed cosmetic product.²⁶

4) **Smoothness of flow Formulations** (F1 to F5) were poured on a glass slide on an area of 1.5 inches. It was spread on a glass plate by making glass slide tilt. Smoothness of flow was determined by comparing with marketed nail lacquer.²⁷

5) **Water resistance test** - This test was performed to measure the resistance of nail lacquer towards water permeability of film. A continuous film was applied on the petri dish, dried and then water was poured on it to immerse the film. The weight of petri dish was taken before and after immersion and increase in weight was calculated.²⁸

6) **Antifungal study of formulations** - Antifungal activity of *C. quadrangularis* extract nail lacquer was evaluated by cup plate method against *Candida albicans*. The sterilized sabouraud dextrose media was poured to the sterilized petri plates and allowed to set. Bacterial culture was inoculated on the media in aseptic condition. Wells were prepared aseptically with sterilized cork borer.²¹ Wells were filled with each 0.8ml (50mg/ml) following solution in DMSO: A: *Cissus quadrangularis* extract loaded formulation (0.8ml). Plates were kept for pre-diffusion in refrigerator for 15 min. After normalized room temperature, all plates were incubated at 30°C for 48 hr. Zone of inhibition (diameter in mm) was measured.

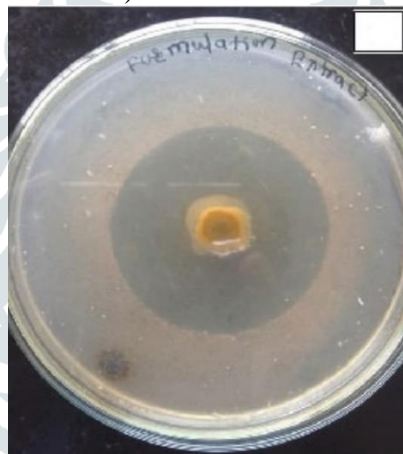

Fig. no. 4 zone of inhibition of extract

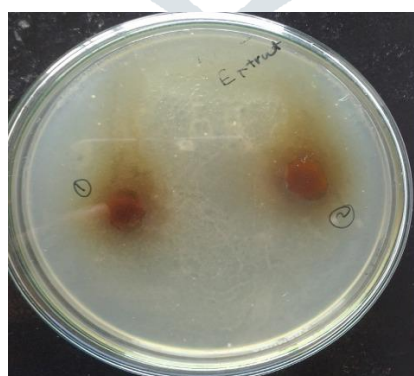


Fig. no. 5 zone of inhibition of Formulation

RESULT

Onychomycosis need targeted drug delivery. The treatment of onychomycosis is difficult because of barrier properties of nail plate. They can inhibit entrance of antifungal drugs in required concentration to treat fungal infection, beneath the nail plate. Therefore, selection of good

penetration enhancer was required to pass maximum more amount of active constituent through the nail plate.

Solubility: The result of solubility studies of pure *Cissus quadrangularis* nail lacquer are given below:

Table No.5: Solubility studies of *C. quadrangularis* powder

Solvents	Solubility (mg/ml)
Ethanol	0.78
Water	0.03
Acetone	0.36

Melting point was found to be $1610C \pm 0.577$ and as per the IP 2007 melting point of *Cissus quadrangularis* nail lacquer was within the range of 159-163 °C.

Formulation development of Nail Lacquer: The objective of the present study was to provide a formulation for inhibiting fungal growth on or underneath toe nails or finger nails so that the appearance of the nails are improved. Formulation includes a film former nitrocellulose, permeation enhancer such as Dibutyl phthalate, keratolytic agent like salicylic acid and an antifungal agent *C. quadrangularis* extract and ethanol as solvent. Formulation is prepared by simple mixing method. Miconazole nitrate nail lacquers were evaluated on the basis of their film formation, smoothness of flow, drying time, gloss, nonvolatile content, viscosity and water resistance properties.

Water resistance : This is the measure of the resistance towards water permeability of the films. This was done by applying a continuous film on a surface and immersing it in water. The weight before and after immersion was noted and increase in weight was calculated. Higher the increase in weight lowers the water resistance.

Identification test of phytoconstituents The extract turned red color, which indicated presence of steroids. For the presence of phenolic test, the extract turned into bluish black color, which confirmed the presence of phenol. For the flavonoids test, the extract turned into yellow precipitate, which confirmed presence of flavonoids. For the presence of quinones, extract turned into yellow precipitate that indicated the presence of quinones

Table no. 6 Test for phytoconstituents

SR.NO.	PHYTOCONSTITUENTS	RESULT
1	PHENOL	+++ Confirmed
2	FLAVONOID	+++ Confirmed
3	QUINONES	+++ Confirmed
4	STEROID	---- not present

Non-volatile content: The non- volatile content of all formulations has been reported in the Table No.18, given below

Drying Time: mentioned in table no. below

Smoothness and Gloss: Both these parameters was found to be satisfactory as can be observed from Fig. The nail lacquer poured onto the glass plate was found to spread and result in a uniform smooth film . The gloss of the applied lacquer was comparable with marketed cosmetic sample proving the cosmetic acceptance.

Anti microbial study: The zone of inhibition for the various formulations was determined, and it was found to range from 14-20mm, which is comparable with that of standard with 21mm. This indicates that all the formulations were sensitive to the microorganism *Candida albicans* .Results are reported in Table No.7 and Figure:6&7

Table no. 7 evaluation of nail lacquer

EVALUATION OF NAIL LACQUER				
BATCHES	NON-VOLATILE CONTENT (%)	FILM THICKNESS (mm)	DRYING TIME (sec)	ZONE OF INHIBITION (mm)
F1	33±0.5	0.17±0.2	62	18±1
F2	34±0.2	0.17±0.5	64	16±2
F3	35±0.4	0.18±0.1	62	14±1
F4	36±0.3	0.19±0.2	65	20±2
F5	37±0.2	0.19±0.3	65	16±2

CONCLUSION

The purpose of this investigation was to formulate and appraise the *C. quadrangularis* nail lacquer as associate horny structure drug delivery system for the treatment of onychomycosis.

C. quadrangularis was chosen as a seasoning drug, the formulations were ready with permeation enhancers Dibutyl Pthalate and keratolytic agent is hydroxy acid. Then, these lacquers were compared for drying time, nonvolatilizable content drug content, drug diffusion and opposed - microbial studies. From the FTIR studies, it absolutely was finished that the drug and also the excipients employed in the formulations were compatible with one another. .

All formulations showed smart film formation, drying time, sleek flow, and needed volatile content.

microorganism study results proven that the formulations square measure sensitive to the being *Monilia albicans*.

The soundness tests showed that the formulations were stable at four hundred c for one month.

From Invitro horny structure permeation study a decent invitro in vivo correlation may be expected.

The adhesive strength of F5 formulation compared with marketed sample and it possess adequate adhesive strength on applied nail surface

REFERENCES:

- Vipin KV, Sarath CC, Ann RA, Premaletha K, Kuriakose MR. Formulation and evaluation of an antifungal nail lacquer for onychomycosis. *British Biomedical Bulletin*. 2014;2(1):242-8.
- Shivakumar HN, Vaka SR, Madhav NS, Chandra H, Murthy SN. Bilayered nail lacquer of terbinafine hydrochloride for treatment of onychomycosis. *Journal of Pharmaceutical Sciences*. 2010;99(10):4267-76.
- Roberts DT, Taylor WD, Boyle J. Guidelines for treatment of onychomycosis. *British Journal of Dermatology*. 2003;148(3):402-10.
- Ameen M, Lear JT, Madan V, Mohd MMF, Richardson M. British Association of Dermatologists' guidelines for the management of onychomycosis. *British Journal of Dermatology*. 2014; 171(5):937-58.
- Gupchup GV, Zatz JL. Structural characteristics and permeability properties of the human nail: A review. *J Cosmet Sci* 1999; 50:363-385.
- Rajendra VB, Baro A, Kumari A, Dhamecha DL, Lahoti SR, Shelke SD. Transungual Drug Delivery: An Overview. *J Appl Pharm Sci* 2012;2(1):203-09
- Patel RP, Naik SA, Patel NA, Suthar AM. Drug delivery across human nail. *Int J Curr Pharm Res* Vol1Issue1 2009;01:01-7
- Suryavanshi KA, Basru PR, Katedeshmukh RG. Review on Nail Transungual Drug Delivery System. *Am. J. PharmTech Res*. 2012; 2(5):222-04.
- Sabreen J, Divyakumar B, Kiran B. Preungual drug delivery systems of terbinafine hydrochloride nail lacquer. *Asian J Pharm* 2008; 02:53-06.

10. Shirwaikar AA, Thomas TA, Lobo R, Prabhu KS. Treatment of Onychomycosis: An Update. *Ind J Pharm Sci* 2008 Nov-Dec;70(6):710-14.
11. Lalit SK, Panwar SA, Darwhaker G, Jain DK. Formulation and Evaluation of Fluconazole Amphiphilic Gel. *Der Pharmacia Lettre*, 2011; 3 (5):125-31
12. Kobayashi Y, Komastu T, Sumi M, Numajiri S, Miyamoto M, Kobayashi D, Sugibayashi K, Morimoto Y. In vitro permeation of several drugs through the human nail plate: Relationship between physicochemical properties and nail permeability of drugs. *Eur. J. Pharm. Sci.* 2004; 21:471-477.
13. Alam G, Singh MP, Singh A, Vishwakarma DK, Patel R, Srivastava SP. Transungual drug transport: advancement and challenges. *J Pharm Res* 2012;5(5):2574- 79.
14. Walters, K.A, Flynn, G.L, Marvel, J.R. Penetration of the human nail plate: the effects of vehicle pH on the permeation of miconazole. *J. Pharm. Pharmacol.* 1985; 37:498- 499.
15. Pravin DC, Shilpa PC, Pramod KK, Bothiraja C. Drug delivery through nail 2006 cited 2010 Nov 29. Available from: URL: <http://www.pharmainfo.net/reviews/drugdelivery-through-nail-review>
16. Boni E, Elewski, Onychomycosis: Pathogenesis, Diagnosis, and Management, *Clin. Microbiol. Rev.* July 1998 vol. 11 no. 3 415-429
17. Jason A. Winston, Jami L. Miller, Treatment of Onychomycosis in Diabetic Patients, *Clinical.diabetesjournals.org* 2008 Nov-Dec; 70(6): 710-714
18. Westerberg DP, Voyack MJ. Onychomycosis: current trends in diagnosis and treatment. *American family physician.* Dec 2013. 88 (11): 762-70
19. Weinberg JM, Koestenblatt EK, Tutrone WD, Tishler HR, Najarian L. Comparison of diagnostic methods in the evaluation of onychomycosis. *J. Am. Acad. Dermatol.* 2003. 49 (2): 193-7
20. Elewski, BE; Hay, RJ. Update on the management of onychomycosis: highlights of the Third Annual International Summit on Cutaneous Antifungal Therapy. *Clinical infectious diseases: an official publication of the Infectious Diseases Society of America.* August 1996. 23 (2): 305-13
21. Phillip R, And Bassler M, Treating Onychomycosis, University of Michigan Medical School, Ann Arbor, Michigan, *Am Fam Physician.* 2001 Feb 15;63(4):663- 673.
22. Cohen PR, Scher RK. Topical and surgical treatment of onychomycosis. *J. Am. Acad. Dermatol.* 1994; 31:S74-S77.
23. Gupta AK, Lynde CW, Jain HC, Sibbald RG, Elewski BE, Daniel CR, Wattlel GN, Summerbell RC. A higher prevalence of onychomycosis in psoriatics compared with non-psoriatics: A multicentre study. *The British journal of dermatology.* 1997. 136 (5): 786-789.
24. Shireesh KR, Chandra SB, Vishnu P, Prasad MVV. Ungual Drug Delivery System Of Ketoconazole Nail Lacquer. *Int J Appl Pharm* 2010;2(4):17-19.
25. Shivkumar HN, Vaka SR, Madhav NV, Chandra H, Murthy SN. Bilayered nail lacquer of terbinafine hydrochloride for treatment of onychomycosis, *J Pharm Sci*, 2010, 99(10): 4267-76.
26. Pati Nikunja Basini, Dey Biplab Kr., Das Sudip, Sahoo Subhas. Nail Drug Delivery System: A Review. *J. Adv. Pharm. Edu. R.* 2012;2(3):101-109
27. Xiaoying H, Thomas CKC, Sherry B, Christine L, Howard I, Ronald CW. Enhanced econazole penetration into human nail by 2-n-nonyl-1,3-dioxolane. *J Pharm Sci* 2002;92:142-8
28. Pati N B, Biplab D K, Sudip D, Subhas S. Nail Drug Delivery System: A Review, *Journal of Advanced Pharmacy Education & Research.* 2012. 2 (3) : 101-109.