



# ROLE OF HOMOEOPATHY IN THE TREATMENT OF CORNS

Dr. Zubair Ali Khan<sup>1</sup>, Dr. Devika Chaturvedi<sup>2</sup>, Dr. Ram Prasad Yadav<sup>3</sup>, Dr. Itti Mishra<sup>4</sup>,

Prof. (Dr.) Dileep Kumar Sonkar<sup>5</sup>

<sup>1,2,3,4</sup> – Post Graduate Scholar, State National Homoeopathic Medical College and Hospital, Lucknow

<sup>5</sup> – Principal, State National Homoeopathic Medical College, Lucknow (U.P.)

## ABSTRACT-

This is a case report of a male patient of 52 years old who came with hard and painful lesion on both feet in the outpatient department and was suffering from corn. He was also suffering from neck pain and flatulence. A proper case taking and repertorization was done and Sepia 30 CH was prescribed, after four follow ups there was marked relief which was analyzed by EQ-5D-5L score. After 3 months of treatment the EQ- VAS changes from 15 to 85. This shows the efficacy of homoeopathic medicine in the management of Corns.

**KEYWORDS-** Corn, heloma, callosities, clavus, homoeopathy

## ABBREVIATIONS-

EQ-VAS- European quality Visual analogue scale

EQ-5D-5L- European quality of life

## INTRODUCTION-

A corn represents a prominent, sharply demarcated area of traumatic hyperkeratosis. It has a visible translucent centre point which presses deeply into the dermis of the skin, causing pain and sometimes inflammation.<sup>1</sup>

Corns and calluses arise from hyperkeratosis, i.e. from chronic excessive pressure or friction on the skin. They may be caused by deformity in foot or from excessive irritation from unfit shoes.<sup>1</sup>

Higher prevalence of these disorders in females has been seen in various studies. The reasons of these hyperkeratotic conditions can be barefoot walking, religious practices, shoes removal etc. Mainly old age suffers a lot than young ones unless there is some deformity in extremities.<sup>2</sup>

It is also easier and simpler to diagnose corns by inspection and palpation because of their rough hyperkeratotic texture on the skin.<sup>2</sup>

Corns and calluses are recurrent and chronic issues, most of them gradually or spontaneously remit when the friction or pressure causes them to be removed. However, if corns do not resolve on their own or if they start causing severe pain then Surgery is widely opted but it fails due to its recurrency.

Homoeopathy has much to offer in the treatment of corn from relief in severe pains to permanent cures.

## **CASE REPORT-**

### **Chief Complaints-**

Mr. ABC, 52 years old presented to OPD of State National Homoeopathic Medical College and Hospital, Lucknow on 31 December 2022 with painful corns in both feet since 5 years which aggravates on pressure and touch. He also presented with pain in cervical region since 5 years which aggravates in winter, numbness in left leg, involuntary urination and flatulence since 6 months.

### **History of present illness:**

Patient was experiencing hard lesions which later become painful due to unfit shoes and later he start taking pain medications and corn caps to relieve it but no permanent relief.

### **Past History:**

- 1- Chickenpox during childhood
- 2- Recurrent Pharyngeal infection.
- 3- Ringworm 10 years ago treated with ointments.

**Family History:**

Paternal

F- Asthma

GF- Diabetes / Rheumatoid arthritis

GM- Asthma

Uncle- Urticaria

Maternal

M- Uterine fibroid

GF- NS

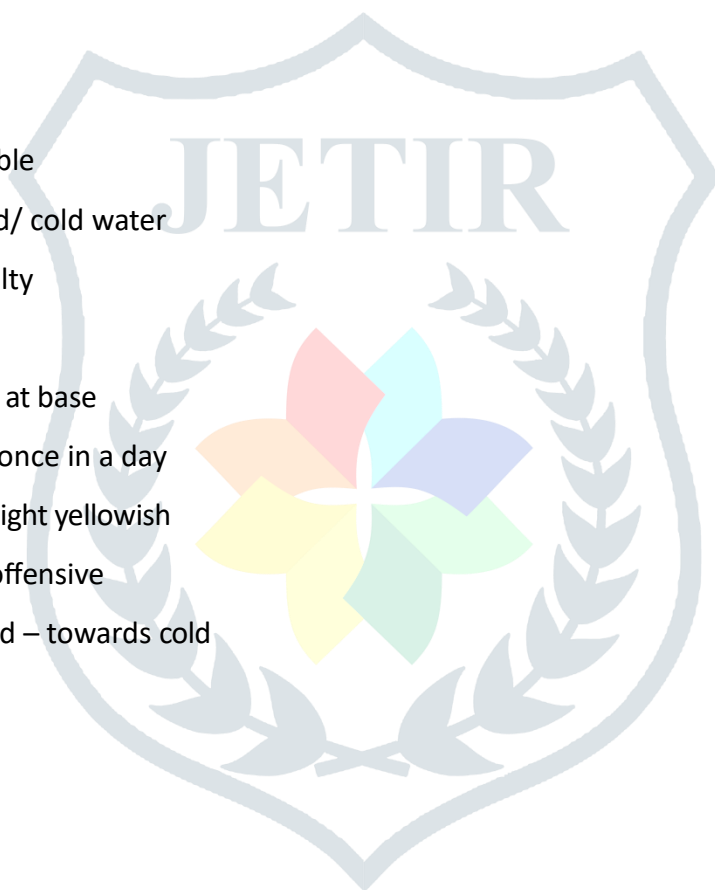GM- NS

**Personal History:**

- Addiction- tobacco chewing
- Food habit- vegetarian

**General Symptoms:****Physical Generals:**

- Appetite- good/tolerable
- Thirst- thirst decreased/ cold water
- Desire- spicy food+, salty
- Aversion- N.S.
- Tongue- Yellow coated at base
- Stool- unsatisfactory/ once in a day
- Urine- Incontinence/ slight yellowish
- Perspiration- scanty/ offensive
- Reaction to heat & cold – towards cold



- Sleep- unrefreshing/ 7 hrs a day
- Dreams- N/S

**Mental Generals:**

- Ardent nature.
- Dutiful and punctual.
- Oversensitive.
- Social and intellectual.

**Physical Examination:****General Examination:**

- Appearance- tall, flabby with dark complexion
- Build- average
- Anemia- absent, on examination – eyelids
- Haemoglobin- 15 gm% on CBC
- Cyanosis-no
- Jaundice- once at age of 16 years
- Clubbing- no
- Height- 182 cm
- Weight- 78 kgs
- Pulse-82/ min
- B.P.- 140/80 mm hg
- Teeth/ Gums- caries on lower right molars
- Temperature- 98.4
- Skin- greasy, oily, dark

**Systemic Examination:**

- Respiratory System- recurrent sore throat
- On chest examination- nothing abnormal detected
- Cardiovascular System- N.S.
- Gastrointestinal System- N.S.
- Genitourinary System-N.S.
- Locomotor System- On examination, reflexes were normal.
- Central Nervous System- N.S.

**Differential Diagnosis:**

- Plantar wart.

**Provisional Diagnosis:**

- Hard corn

**Confirmed Diagnosis:**

- Hard corn

**Analysis of symptoms:**

- Ardent nature
- Sense of duty
- Oversensitive
- Extroverted
- Pain in back of neck extending upward.
- Painful hard corns on both feet.
- Numbness of left leg.
- Heaviness of abdomen with flatulence.
- Involuntary urination
- Tongue coated yellow at base
- Hypertension

**Investigations (if any): NO**

**Evaluation of symptoms:**

- Mental- Dutiful
- Mental- Oversensitive
- Physicals 1-Yellow coated tongue at base
- 2-Involuntary urination.
- Particulars-
  - 1-Hard painful corn on both plantar aspects of foot.
  - 2-Numbness of left leg.
  - 3-Heaviness of abdomen with flatulence.
  - 4-Pain in back of neck extending upwards.

**Miasmatic diagnosis**

- Psoro-Sycotic Background

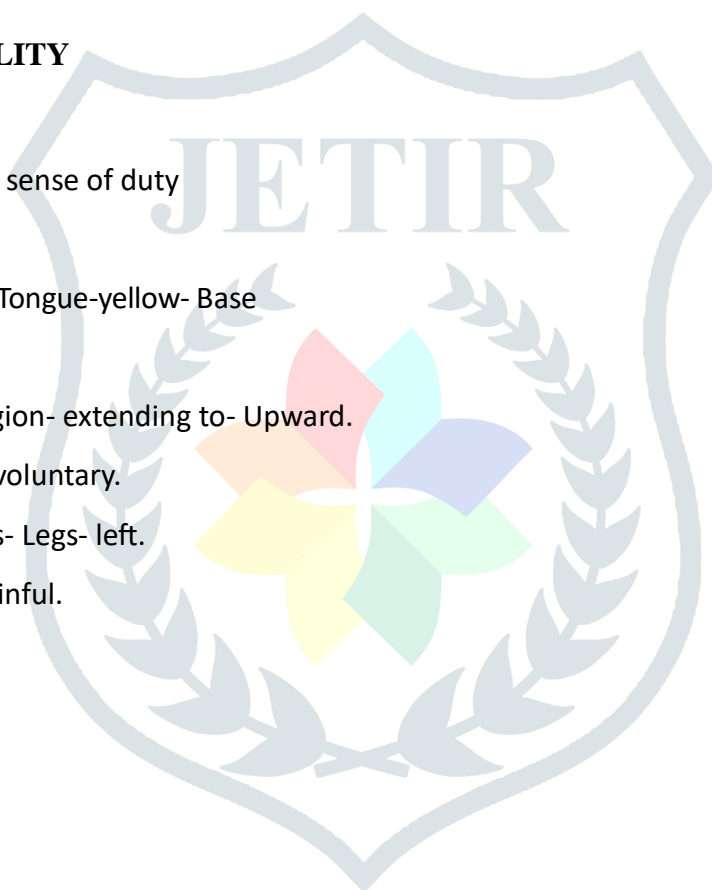**Totality of symptoms**

- Sense of duty
- Oversensitive
- Heaviness of abdomen.
- Yellow discoloration of tongue
- Painful hard lesion in both feet.
- Pain in back of neck extending upward.
- Involuntary urination.
- Numbness of left leg.

#### SELECTION OF REPERTORY- SYNTHESIS REPERTORY- BY FREDERIK SCHROYENS

#### REPERTORIAL TOTALITY

- Mind- Duty- too much sense of duty
- Mind- Sensitive.
- Mouth- discoloration- Tongue-yellow- Base
- Abdomen- Heaviness
- Back-Pain- Cervical region- extending to- Upward.
- Bladder- Urination- Involuntary.
- Extremities-Numbness- Legs- left.
- Extremities- Corns- Painful.



#### REPERTORIAL RESULT

*Sepia* 14/08

*Lycopodium* 13/06

*Phosphorus* 11/06

*Calc. Carb* 10/06

*Nux Vomica* 10/06

*Argentum Nitricum* 10/05

**ANALYSIS OF REPORTORIAL RESULT-**

There is only one medicine which covers all the symptoms and the final Prescription is based on Materia Medica which is *Sepia*.

**SELECTION OF MEDICINE-** *Sepia officinalis*

**PRESCRIPTION-**

Rx

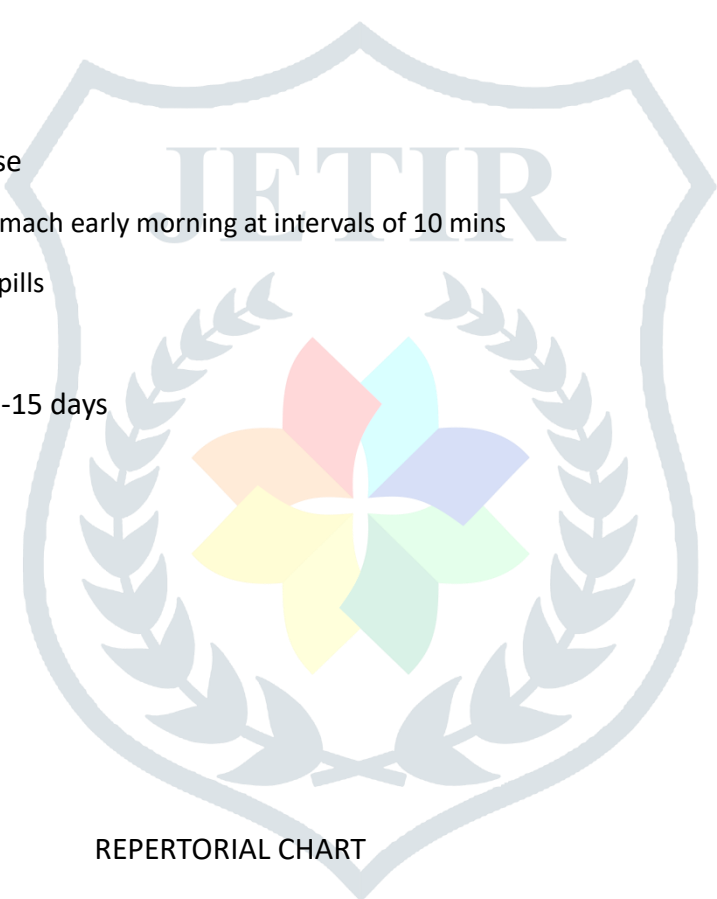
*Sepia* 30 / 3 dose

4 pills empty stomach early morning at intervals of 10 mins

Sac lac 30/ tds 4 pills

31/12/2022

-15 days



REPERTORIAL CHART

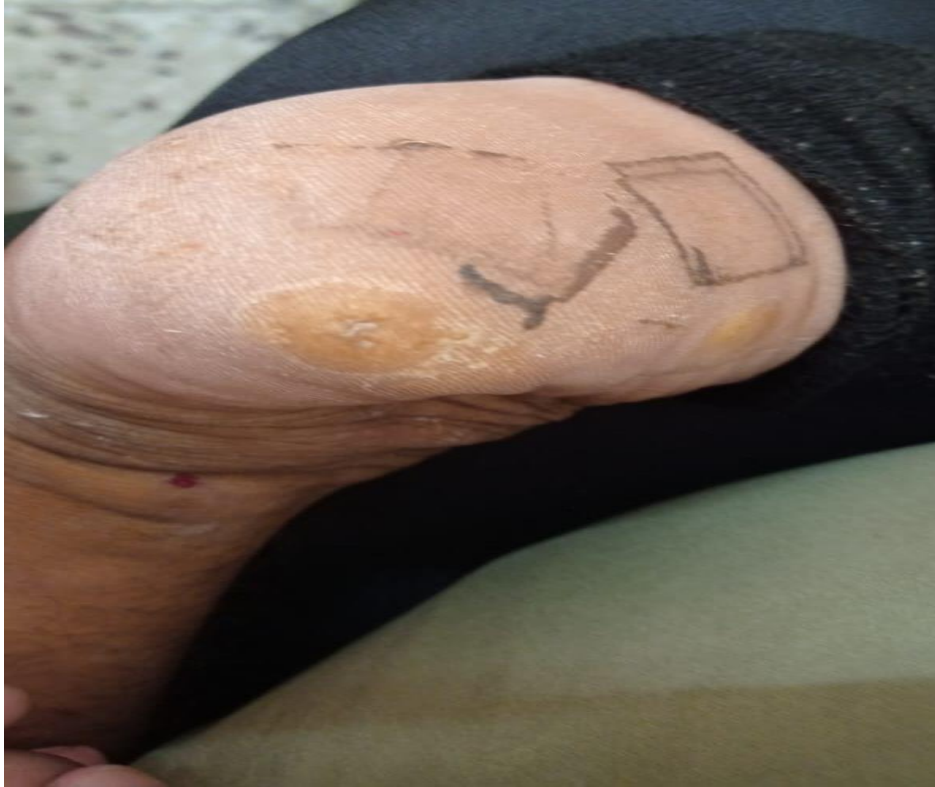



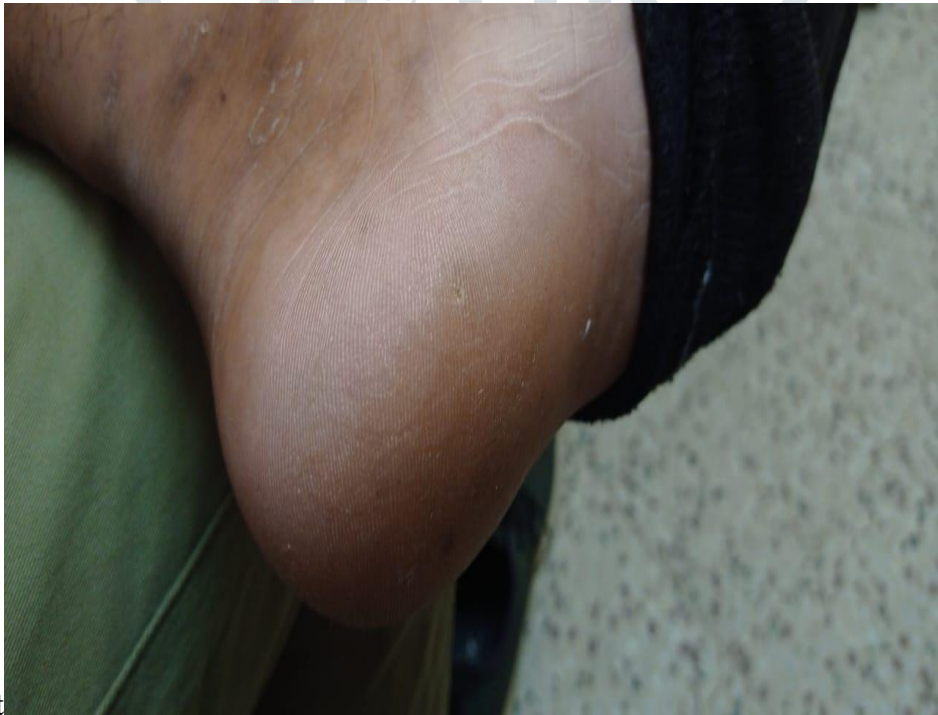1.	18/01/2023	Pain in corn slightly relieved, slight relief in cervical pain, other complaints as it is	Rubrum Met. 200/1 dose Sac lac 30/TDS 15 days
2.	30/01/2023	Pain in corn slightly relieved, slight relief in cervical pain, Abdominal heaviness slightly reduced, Numbness slightly relieved, Urine involuntary	Rubrum Met.200/1 dose Sac Lac 30/TDS 15 days
3.	16/02/2023	Pain in corn increased again, relief in cervical pain, abdomen heaviness increased, numbness relieved, urine involuntary.	Sepia 200/1 dose Sac Lac 30/TDS 15 days
4.	02/03/2023	Pain in Corn much reduced and size reduced about 70%, cervical pain better, no heaviness in abdomen, numbness in leg much relieved, urine incontinence slightly better.	Rubrum met. 30/1 dose Sac Lac 30/TDS 15 days
5.	29/03/2023	Corn is completely resolved with no pain at the site, cervical pain is 70% better, no heaviness in abdomen, numbness is completely relieved, urine incontinence much better.	Rubrum met 30/1 dose Sac Lac 30/TDS 15 days

#### Management:

- No use of corn caps or any surgical debridement.
- Do not press the part for long time.
- Use saline water to prevent pain or swelling if necessary.
- Wear proper footwears and maintain foot hygiene.
- Avoid walking barefoot or on uneven grounds.
- Avoid coffee or fragrances.

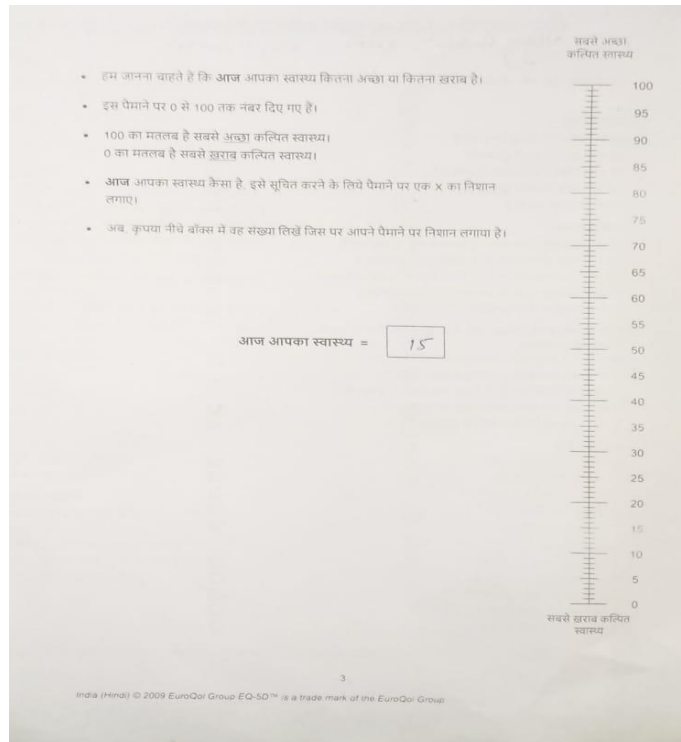


JETIR

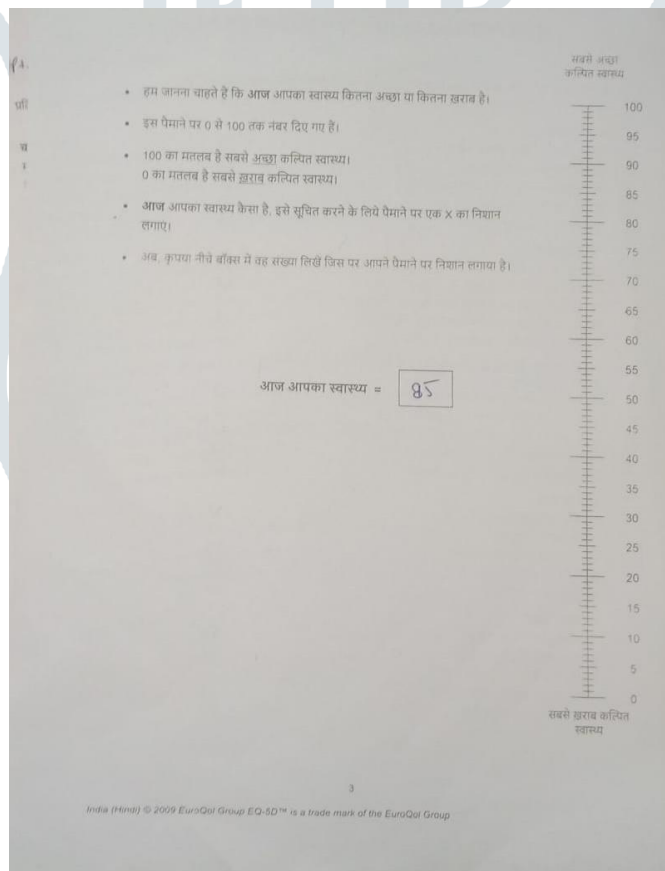


**Before treatment**

**After treatment**



### EQ- VAS before treatment



### EQ-VAS after treatment

**DISCUSSION-** Corns are very common foot ailments mainly found in elderly individuals. Hypertrophic keratosis leads to such painful lesions. In case of quantity of corns, many prefer surgical debridement and some prefer topical treatments.<sup>3</sup> Both are typical treatments with higher chances of recurrency in corns as well as leads to complications.

**CONCLUSION** - After proper case taking, the case was repertorized using Synthesis repertory as per the diversity of the symptoms and materia medica.<sup>4</sup> Sepia was prescribed to the patient which proved to be homoeopathic to the case. The Score of EQ-VAS was 15 on base line and after 3 months of treatment it was 85. Thus, it proves that Individualized homoeopathic medicine has significant role in treatment of corns.

- 1.
2. Singh D, Bentley G, Trevino SG. Callosities, corns and calluses. *BMJ* 1996;312:1403-6.
3. Elwell R. The management and treatment of hyperkeratosis. *Br J Nurs*. 2017 Apr 27;26(8):468-470. [PubMed]
4. MENDELSON SA. Arthroplasty of fifth toe for removal of heloma durum. *J Natl Assoc Chiropr*. 1957 Feb;47(2):81-2. [PubMed]
5. Schroyens frederik –Augmented clinical synthesis .9.1 ed. New Delhi : B.Jain Publisher (P) Ltd; 2011

