

# Predicting Mass using Infrared Image

<sup>1</sup>R.Vinoth, <sup>2</sup>M.Balaji, <sup>3</sup>S.Shobana, <sup>4</sup>R.Nivethitha, <sup>5</sup>D.Vinoth

<sup>1,2,3,4,5</sup>Assistant Professor,

<sup>1,2,3,4</sup>Department of Electronics and Communication Engineering,

<sup>5</sup>Department of Electrical and Electronics Engineering,

<sup>1,2,3,4,5</sup>Muthayammal College of Engineering, Rasipuram

**Abstract :** Medical imaging techniques plays vital role in the detection of the Cancer Cells .Survival of the Cancer patients is minimized as it affects the entire population. Especially the breast Cancer survival patients is very low comparatively and in the metastasis stage after the removal of the Cancer Cell also the survival rate of the Cancer patients are very less. Many imaging techniques viz Mammography, PET, SPECT, CT are available but in case of Dense tissue the imaging performance may be very low. To overcome this effect Cone beam Technology is used. In this Proposal the slides of the images are reconstructed using Analytical reconstruction and iterative reconstruction and Analytical reconstruction is efficient during Computation and Iteration reconstruction can improve the quality of the images .The step and Shoot cone beam refers the trajectory forming a single circle. Iterative technique is also known to be algebraic reconstruction is inverting the images. The reconstructed images are extended for the volumetric tomosynthesis .The volumetric images of the images are converted into 3D volumetric using DoS .The complete images are converted into 3D volumetric images .These images when they are normally produced in CT it may not be visible perfectly. Instead using Infrared image the cold region and the Hot region can be identified without affecting the images. From these volumetric images low resolution images can be converted into high resolution images .Infrared Images are highly active between visible and microwaves .Malignant cells utilizes more oxygen than the normal cells .These Malignant cells aids the blood circulation in the cells there by high concentration of heat is around the cell of the Tissue . The conventional method of imaging involves the single volume is construction. The Near IR when used could be given pseudo color wherein the colors differentiate the hot region and the cold region. The Region of Interest can be identified from the reconstructed images. These images are not projected images but reconstructed 3D images. From these 3 D images the exact location of the lesion can be located and the Region of Interest would be Volume of Interest .The Volumetric of Interest will be the weight of the location and weight of the lesion. Feature can be extracted from the dense tissue.

**Key Words:-** Mammography, Malignant cells, ULTRASOUND, Magnetic Resonant Imaging.

## I. INTRODUCTION

Breast cancer as such is one of the major health disorders. It can cause death when it is not treated According to statistics a total of 1,660,290 new cancer cases and 580,350 cancer deaths are projected to occur in the United States in 2013.About 234,580 cancer are detected as in Cancer Journal for Clinicians .The survival rate Breast cancer patient can be increased when the early-stage disease is treated using current therapies. The most effective screening technique of the time.

The easiest and most effective screening and diagnosis is mammography .The sensitivity of Mammography for breast cancer detection is moderate (75%) and even reduced in women with dense breasts is 62 %.X- mammography has a 22 % false positive rate in women under 50. The mammography cannot identify whether the cancer is malignant tumors.

Magnetic resonance imaging (MRI) and ultrasound are one of the new technology methods of detecting the breast cancer but it has limitations such as high cost , low throughput ,limited specificity (MRI) and low sensitivity (Ultra sound). Though there are many detective methods the solution for the treatment of breast cancer are still in the experimental stage at the earlier stage .

Newer methods are being used in the Clinical detection .The newer methods are elastography ,tomosynthesis,dedicated computer tomography(CT) and positron emission tomography(PET),photo acoustic (or optoacoustic)imaging ,and optical imaging.

Since the breast cancer is regenerative disease the effective eradication of the disease is not possible as it reappear in lungs, uterus e.t.c.

### (a) IMAGING OF BREAST CANCER

Imaging the Breast is important aspect for detection of cancer in diagnosis, and Clinical observation of breast cancer.The mostly used imaging modalities are mammography ,magnetic resonance imaging (MRI),scintimammography, single photon emission computed tomography (SPECT)and positron emission tomography(PET).

**(b) ULTRASOUND (SONOGRAM)**

Ultrasound or sonogram is widely used to define the difference between types of lumps, such as liquid –filled cysts and solid masses. As the ultrasound is applied on the patient size, shape, texture and density of a breast lump can be found. Colour Doppler effect can also be used for analysing the breast .Ultrasound is one of the useful tool to use with mammograms as it is widely available ,noninvasive and has least cost than other methods.

**(c) MAGNETIC RESONANCE IMAGING**

Dynamic contrast enhanced MRI is used to detect ,diagnosis and also used in clinical management of the breast cancer. But it requires intravenous injection of Gadolinium –contrast agent.Breast MRI is frequently used in the management of breast cancer ,especially to determine disease extent in the breast .Another technique in detecting of breast cancer is the proton magnetic resonance spectroscopy (1H-MRS).

A Magnetic resonance imaging utilises a magnet and radio waves to form an image of the breast .Further it detects cancers in dense breasts that is not viewed on mammogram.MRI is also used for detecting if breast implant has leaked or ruptured.In this technique quantitative characterization of total or composite choline concentration .

**(d) RADIONUCLIDE IMAGING**

Radionuclide-based imaging techniques such as scintimammography ,single –photon emission computed tomography (SPECT) ,positron emission mammography (PEM), and positron emission tomography (PET) used for physiologic information.Scintimammography and SPECT normally use 99mTc-Sestamibi for breast cancer imaging incase of palpable lesions which are occult .PET is used in the advanced stage of breast cancer and also for monitoring response to therapy.

**II. OTHER TECHNIQUES****(a) VOLUMETRIC X-RAY IMAGING TECHNIQUES**

Stereoscopic Digital mammography (SDM),Digital breast tomosynthesis (DBT),and Dedicated breast computed tomography(BCT) are the three techniques used for investigation clinically.

**(b) STEREOSCOPIC DIGITAL MAMMOGRAPHY**

Two projection images with few degrees apart , are required with a digital mammography system.Orthogonal polarized images are viewed by the user using passive cross –polarized glasses , as each eye visualizes one image to provide depth perception .

**(c) OPTICAL IMAGING**

Optical imaging like diffuse optical tomography (DOT),diffuse optical imaging and diffuse optical spectroscopy are in the experimental stage for detecting breast cancer.

**(d) OPTICAL IMAGING**

Diaphanography was applied to shadows of breast tissue.Though diaphanography was large,highly vascular ,malignant lesions could be detected.Transillumination is inadequate for clinical use as it is too difficult to meparates the effects of absoption and scattering as two dimensional image is ill suited for image reconstruction.

Optical breast imaging uses near infra-red light to assess optical properties of the tissue in the breast cancer detection.When fluorescent probes are excited by NIR light, they emit photons which are the defined and detectable wave length as detected by an optical imaging system. Studies using the intrinsic optical properties of the breast to visualize lesions without the use of fluorescent contrast agents.

The optical imaging is used during the examination of the breast unlike PET and SPECT no radio active comp[onents are used for the detection of the cancer cells and also the sensitivity of the optical imaging is high compared to that of MRI . It is also inexpensive .

**(e) INFRA RED IMAGE**

Near infra-red penetrates into a significant depth which allows an optical therapeutic window in the range of 600 -1000 nm .This imaging technique could be used for the detection of the cancer cells.Considering the thermal infrared images , emphirical transformation is possible mapping the infrared and the original image.

This infra red technique reduces the false positive rate of the diagonis and increases chances of curing the disease and also for the surviaval of the patients .

**(f) THERMAL OF THE HUMAN BODY**

Hippocrates wrote in 400 B.C “ In whatever Part of the body excess of heat or cold is felt ,the disease is there to be disciovered .In ancient mythology Human body which was covered with mud and the area that dried more quickly indicating that the warmer region was considered the diseased tissue.

**(g) CANCER CELL**

Cancer cell is triggered by mutation by x rays , UV rays , etc .They divide aggressively and does not follow the normal path of the growth of the cells.The metabolism of the cancer cells are different from the normal cell activity.The consumption of Oxygen is lower than the normal cells but the utilization of the glucose is beyond higher rate than the normal cells around 5 -10 times of the normal cell and converts most of the glucose into lactate instead of pyruvate . The high metabolic rate of the cancer cells increases the temperature in around the cancerous cells as compared to the normal cell .The growth of the cancer cell is limited by the blood supply to that tissue .

**(h) OPTICAL IMAGING OF THE BREAST**

In Optical imaging light propogates through the tissue to assess its optical properties.Optical imaging devices transmit light through the breast ,it absorbs and scatters by the tissue components .Optical imaging uses commonly used monochromatic and in the near –infrared (NIR) permitting imaging up to several centimeters deep in tissue.After passing through the breast, the remaining light is paased through detectors .

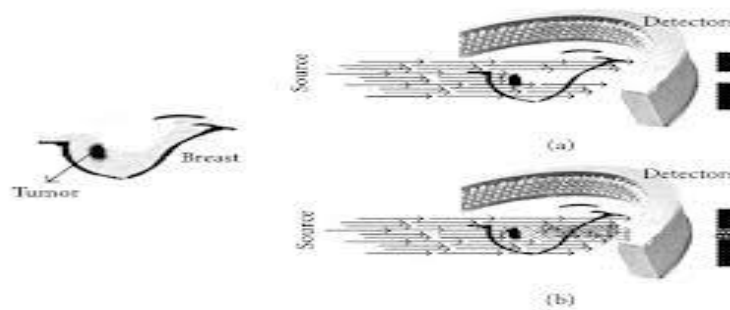


Figure1: Tumor Image

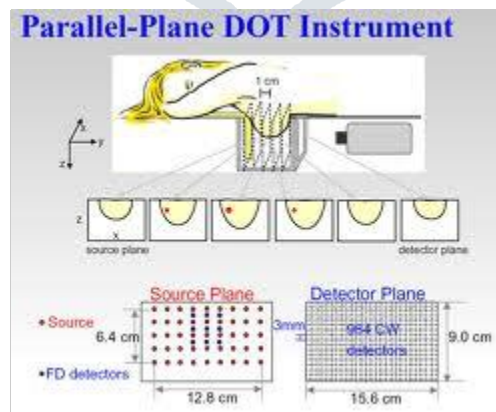


Figure 2 : Infrared Detector

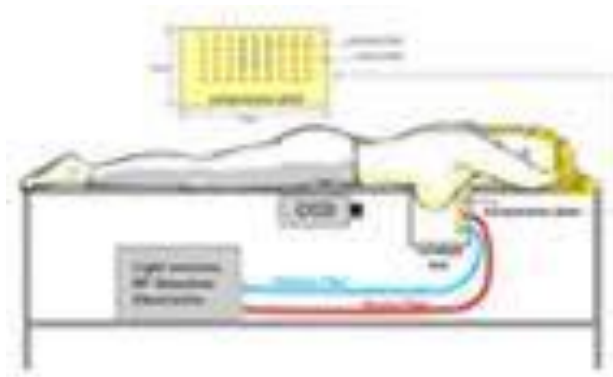


Figure 3: Imaging using Infrared

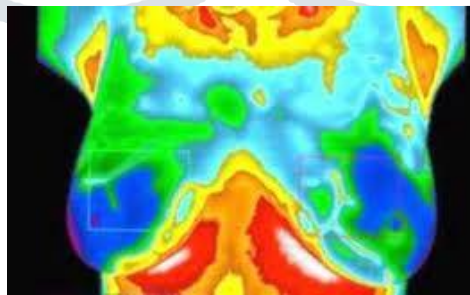


Figure 4: Infra Red Image

#### (i) OPTICAL BREAST IMAGING –BASICS

Optical imaging is propagated via tissue by using the light sources and the optical properties. When the light source is transmitted in the tissue of the breast, the light source is absorbed and it is dispersed by the tissue components present near by the tissues. The monochromatic light used in the optical imaging and the range of the optical imaging is near Infra red (NIR) which permits few centimeters deep in the tissue. Tissue are basically of different materials as when light is transmitted the scattering and absorption of the different tissue is of different characteristics. The range is normally of 600 -1000 nm which is enough for penetration into the soft tissue.

Optical imaging uses different methods for illumination Continuous wave (CW), Time-domain photon migration (TDPM), and Frequency –domain photon migration .

#### (j) CONTINUOUS –WAVE IMAGING

Continuous –wave emits the light at the frequency of (0.1 -100 K)Hz[33] with constant intensity . With these intensity the light focusses on the tissue ,surface and in the volume of the tissue .

#### (k) TIME –DOMAIN PHOTON MIGRATION IMAGING (TDPM)

TDPM uses 500-400 pico seconds pulses to exhibit the temporal distribution of photons [34] .The photons reach the tissue very early as the scattering increases with the flight distances. Due to the attenuation the photons could be used for detection in the tissues .

### III. CONCLUSION

The Process of Extracting the Images which is of Volumetric Of Interest would give the exact location of the weight of the image along with the location would be efficient in the imaging techniques of detection of Cancer .The images extracted can and can be used for various detection of the cancer.

### IV. REFERENCES

- [1.] M. Garcia, A. Jemal, E. M. Ward et al., *Global Cancer Facts & Figures 2007*, American Cancer Society, Atlanta, Ga, USA, 2007.
- [2.] American cancer Society, Statistics for 2004: Cancer facts & figures, 2004, <http://www.cancer.org/research/cancerfactsfigures/cancerfactsfigures/index>.

- [3.] S. A. Feig, "Decreased breast cancer mortality through mammographic screening: results of clinical trials," *Radiology*, vol. 167, no. 3, pp. 659–665, 1988.
- [4.] "Breast cancer. Early detection and prompt treatment are critical," *Mayo Clinic Health Letter*, supplement 1–8, 2001.
- [5.] S. L. Jacques, "Time resolved propagation of ultrashort laser pulses within turbid tissues," *Applied Optics*, vol. 28, no. 12, pp. 2223–2229, 1989.
- [6.] K. Kerlikowske, J. Barclay, D. Grady, E. A. Sickles, and V. Ernster, "Comparison of risk factors for ductal carcinoma in situ and invasive breast cancer," *Journal of the National Cancer Institute*, vol. 89, no. 1, pp. 77–82, 1997.
- [7.] M. J. Homer, "Breast imaging: pitfalls, controversies, and some practical thoughts," *Radiologic Clinics of North America*, vol. 23, no. 3, pp. 459–472, 1985.
- [8.] J. Wang, T. T. F. Shih, J. C. Y. Hsu, and Y. W. Li, "The evaluation of false negative mammography from malignant and benign breast lesions," *Clinical Imaging*, vol. 24, no. 2, pp. 96–103, 2000.
- [9.] S. Shapiro, P. Strax, and L. Venet, "Periodic breast cancer screening in reducing mortality from breast cancer," *Journal of the American Medical Association*, vol. 215, no. 11, pp. 1777–1785, 1971.
- [10.] E. L. Thurffjell and J. A. Lindgren, "Breast cancer survival rates with mammographic screening: similar favorable survival rates for women younger and those older than 50 years," *Radiology*, vol. 201, no. 2, pp. 421–426, 1996.
- [11.] R. E. Hendrick, R. A. Smith, J. H. Rutledge III, and C. R. Smart, "Benefit of screening mammography in women aged 40–49: a new meta-analysis of randomized controlled trials," *Journal of the National Cancer Institute Monographs*, no. 22, pp. 87–92, 1997.
- [12.] L. Tabar, B. Vitak, H. H. Chen, M. F. Yen, S. W. Duffy, and R. A. Smith, "Beyond randomized controlled trials: organized mammographic screening substantially reduces breast carcinoma mortality," *Cancer*, vol. 91, no. 9, pp. 1724–1731, 2001.
- [13.] J. M. Boone, "Normalized glandular dose (D<sub>gN</sub>) coefficients for arbitrary x-ray spectra in mammography: computer-fit values of Monte Carlo derived data," *Medical Physics*, vol. 29, no. 5, pp. 869–875, 2002.
- [14.] G. R. Hammsterstein, D. W. Miller, and D. R. White, "Absorbed radiation dose in mammography," *Radiology*, vol. 130, no. 2, pp. 485–491, 1979.
- [15.] T. M. Kolb, J. Lichy, and J. H. Newhouse, "Comparison of the performance of screening mammography, physical examination, and breast US and evaluation of factors that influence them: an analysis of 27,825 patient evaluations," *Radiology*, vol. 225, no. 1, pp. 165–175, 2002.
- [16.] FDA, US Public Health Advisory: Update on Magnetic Resonance Imaging (MRI) Contrast Agents Containing Gadolinium and Nephrogenic Fibrosing Dermopathy, 2006, [http://www.fda.gov/Cder/Drug/advisory/gadolinium\(agents\)2006-1222.htm](http://www.fda.gov/Cder/Drug/advisory/gadolinium(agents)2006-1222.htm).
- [17.] I. S. Gribbestad, B. Sitter, S. Lundgren, J. Krane, and D. Axelson, "Metabolite composition in breast tumors examined by proton nuclear magnetic resonance spectroscopy," *Anticancer Research*, vol. 19, no. 3, pp. 1737–1746, 1999.
- [18.] K. Yutani, E. Shiba, H. Kusuoka et al., "Comparison of FDGPET with MIBI-SPECT in the detection of breast cancer and axillary lymph node metastasis," *Journal of Computer Assisted Tomography*, vol. 24, no. 2, pp. 274–280, 2000.
- [19.] M. F. Smith, S. Majewski, A. G. Weisenberger, D. A. Kieper, R. R. Raylman, and T. G. Turkington, "Analysis of factors affecting positron emission mammography (PEM) image formation," *IEEE Transactions on Nuclear Science*, vol. 50, no. 1, pp. 53–59, 2003.
- [20.] C. J. Thompson, K. Murthy, I. N. Weinberg, and F. Mako, "Feasibility study for positron emission mammography," *Medical Physics*, vol. 21, no. 4, pp. 529–538, 1994.
- [21.] M. Cutler, "Transillumination of the breast," *Surgery, Gynecology & Obstetrics*, vol. 48, pp. 721–727, 1929.
- [22.] D. Floery, T. H. Helbich, C. C. Riedl et al., "Characterization of benign and malignant breast lesions with computed tomography laser mammography (CTLM): initial experience," *Investigative Radiology*, vol. 40, no. 6, pp. 328–335, 2005.