

# Treatment of skin warts caused by human papillomavirus (HPV) by sodium bicarbonate (NaHCO<sub>3</sub>).

Suhail Rashid Mir, Syed Tanveer

Department of Zoology, University of Kashmir, Hazratbal Srinagar-190006

**Abstract:** sodium bicarbonate-NaHCO<sub>3</sub> has many domestic, traditional, medical, and empirical uses; only little scientific documentation of its activity is available. In present study anti-wart activity of sodium bicarbonate was studied. The warts were spread over lower facial and upper neck area (fig 1.1-1.4). The warts were cut at the base and applied with a mixture of sodium bicarbonate and castor oil in 1:1 proportion (fig 1.5). After 24 hours of the procedure the treated area was completely clotted (fig 1.6). After 48 hours of the procedure the area showed recovery with wounds completely dried up (fig 1.7). After 60 hours of the procedure the area showed only small scars (fig 1.8). After one week, whole area was cleared of warts without any rudiment scar or black or brown spot (fig 1.9). No recurrence of the infection and any wart development were observed after a period of three months (fig 2.1).

The study revealed the anti-wart activity of sodium bicarbonate which may be due to alkalization of the infected area which makes it unfit for the human papillomavirus and HPV infected cells to sustain, grow, and divide. It may be also due to release of CO<sub>2</sub> by sodium bicarbonate and making the wart area oxygen deficient and killing the wart cells by anoxia and pH variation.

Treatment of warts by sodium bicarbonate could be a cheap, affordable and easily available remedy to patients. It may result as a relief to millions of people suffering from warts. It also suggest sodium bicarbonate a valuable anti-cancer agent, however only little scientific documentation of its activity is available. There is need to study these properties of sodium bicarbonate in controlled experiments.

**Key words:** Sodium bicarbonate, warts, scar, anoxia, human papillomavirus, alkalization.

**Abbreviations:** HPV for human papillomavirus.

## Introduction:

Warts are caused by epidermal infection of skin with human papillomavirus (HPV) (1). Skin warts exists in different forms including planter warts (*Verruca plantaris*), common warts (*Verruca vulgaris*), and flat warts (*Verruca plana*). Skin warts are estimated to occur in up to 10% of young adults and children, with the greatest incidence between 12 and 16 years of age (2). Warts occur more frequently in girls than in boys. Common warts represent 70% of skin warts and occur primarily in children, whereas planar and flat warts occur in a slightly older population (3). Homeopathic science believes that along with external virulence there is an internal propensity to diseases. This explains why some people are not affected by the virus, whereas others do (4).

No single treatment is 100% effective in case of warts and different types of treatment may be combined. Research into efficacy of diagnosis and treatment must take into account the possibility of spontaneous regression. It is a valid management option to leave warts untreated, however in immunosuppressed patients and in those with a long duration of infection warts are less likely to resolve spontaneously and are more recalcitrant to treatment ([5-7](#)).

Sodium bicarbonate has variety of medical properties. It is commonly called as baking soda and is used in treatment of itchy skin, canker sores, sun burns, heart burn, mouth wash, etc. Microbiological studies have shown that baking soda solutions have significant bactericidal activity against pathogens ([8,10](#)). Sodium bicarbonate, diuretic furosemide and carbicarb which are known to induce metabolic alkalosis in humans--may be useful in enhancing the efficacy of tumor treatment regimens in humans ([9](#)). Use of high concentrations of sodium bicarbonate in oral health care products could conceivably result in decreased levels of cariogenic *S* mutants in saliva and plaque ([10](#)). Sodium bicarbonate has antifungal activity on the most common agents of cutaneous fungal infection and onychomycosis ([11](#)).

There was found enough literary evidences in support of baking soda as antiseptic agent and thus present study was designed to evaluate the anti-wart activity of sodium bicarbonate.

### Material and methods:

Sodium bicarbonate alone or a tea spoon of sodium bicarbonate mixed with equal amount of castor oil in 1:1 ratio was prepared in a petridish. The area infected with warts was sterilized with disinfectant to eliminate any chance of secondary infection. Ice cold treatment to the wart infected area was given to reduce the circulation in order to minimize the blood loss and pain following a cut at the base of a wart. After the cut at the base of a wart, blood was cleaned and the above preparation was applied on the cut area with the help of a cotton swab. The wound was allowed to heal.

### Results:

The results are shown in fig 1.1-2.1. The warts were spread over lower facial and upper neck area (Fig 1.1-1.4). The warts were cut at the base and applied with a mixture of sodium bicarbonate and castor oil in 1:1 proportion (Fig 1.5). They were left undisturbed overnight. After 24 hours, the area was completely clotted (Fig 1.6). After 48 hours of the procedure the area showed recovery with wounds completely dried up (Fig 1.7). After 60 hours of the procedure the area showed only small scars (Fig 1.8). After one week whole area was cleared of warts without any rudiment scar or black spot left (Fig 1.9). No recurrence of infection by HPV and any wart development were observed after a period of three months (fig 2.1).

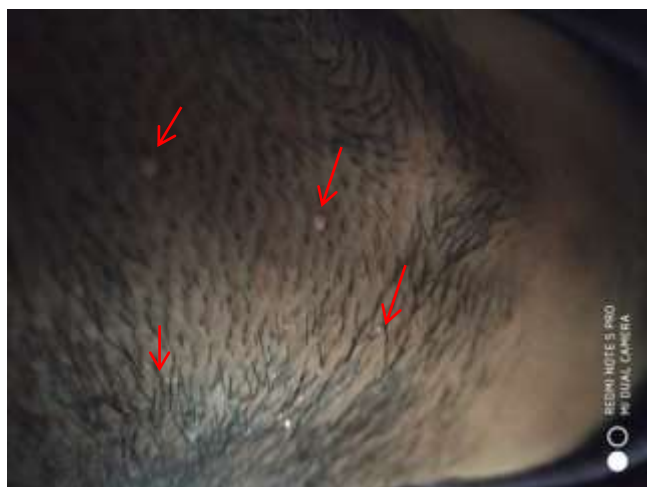

Fig. 1.1 Red arrows showing warts on neck region.

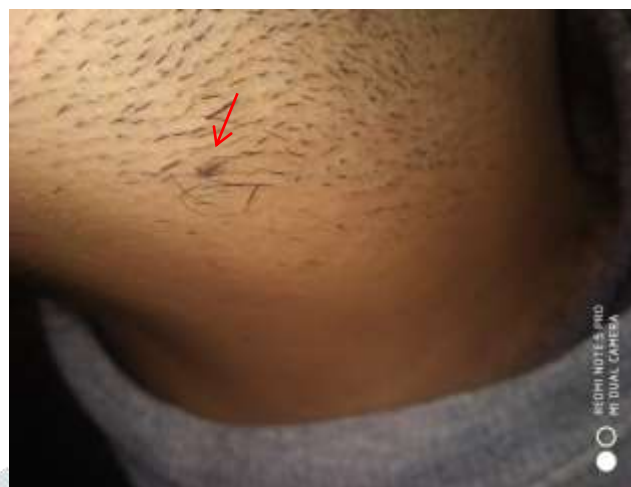

Fig. 1.2 Red arrow showing a large wart on neck region.

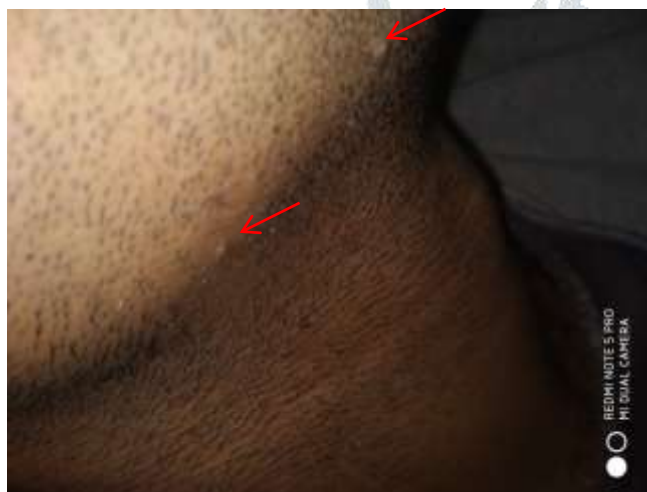

Fig. 1.3 Red arrows showing warts on chin region.

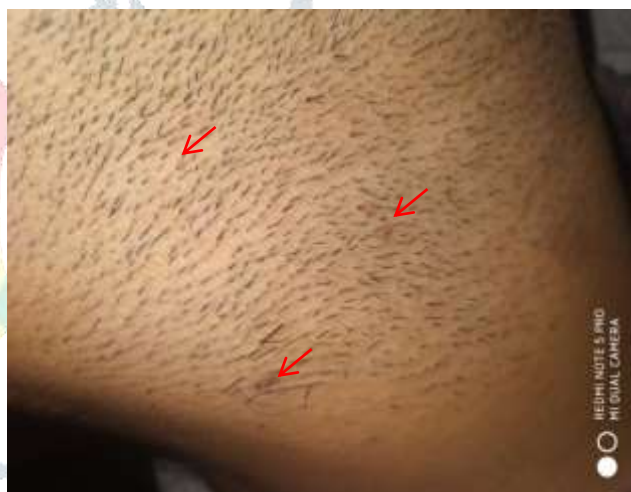

Fig. 1.4 Red arrows showing warts on neck region.

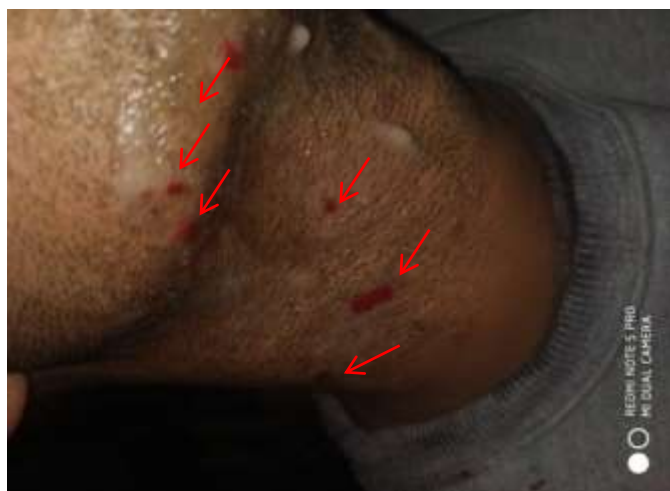

Fig. 1.5 Red arrows showing wounds of cut warts treated with mixture of baking soda and castor oil on chin and neck region.

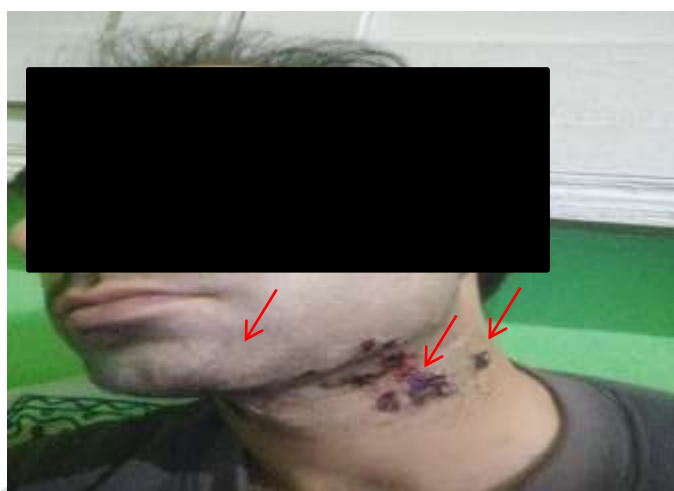

Fig. 1.6 Red arrows showing healing of wounds of cut warts treated with mixture of baking soda and castor oil on chin and neck region.

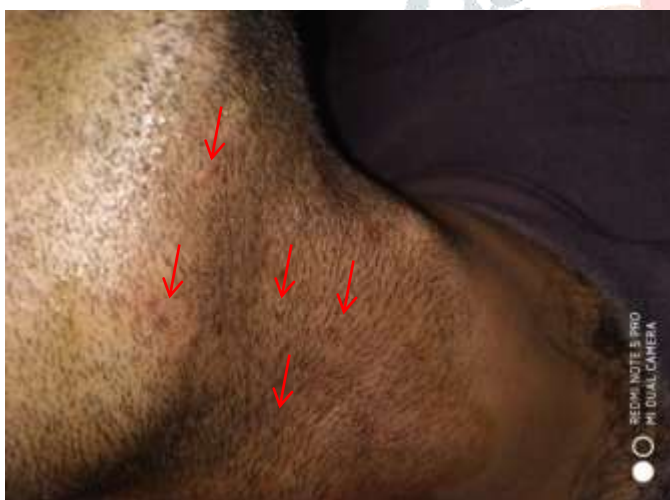

Fig. 1.7 Red arrows showing recovery of wounds treated with mixture of baking soda and castor oil on chin and neck region.

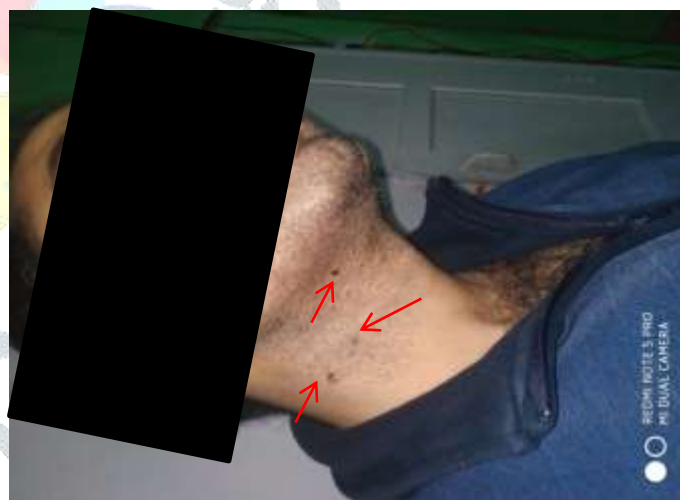

Fig. 1.8 Red arrows showing scars of wounds on chin and neck.



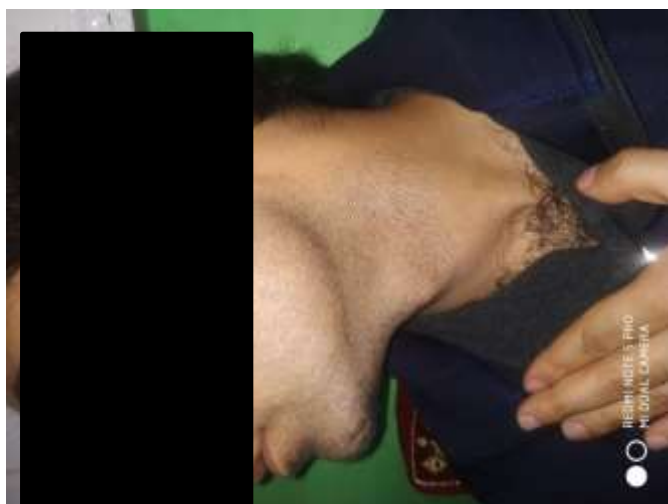


Fig. 1.9 Shows treated chin and neck region without any recurrent wart or rudimentary scar or spot.

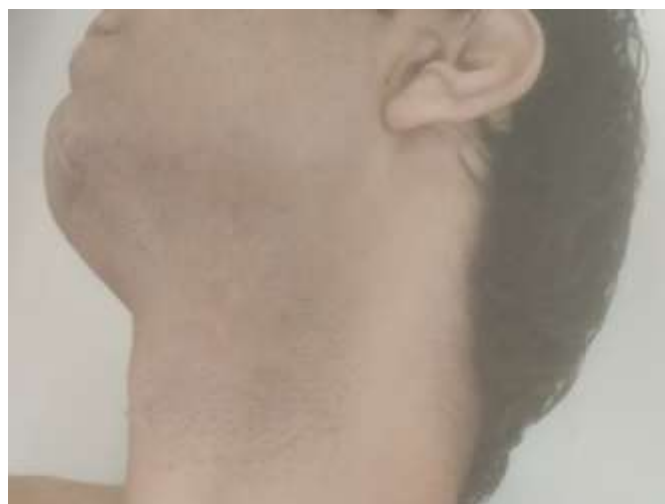

Fig. 2.1 Shows treated chin and neck region without any recurrent wart or rudimentary scar or spot three months post treatment.

### Discussion:

The treatment of warts poses a therapeutic challenge for physicians. No single therapy has been proven effective at achieving complete remission in every patient. As a result, many different approaches to wart therapy exist ([12](#)). Salicylic acid has been shown to produce clearance in 67% of patients with hand warts and 84% in those with plantar warts in 12 weeks ([5](#)). In Cryotherapy, liquid nitrogen (LN2, 2196 8C) is applied on warts and is the most commonly used agent([13](#)).

Surgical removal of warts is widely practiced, particularly by curettage or blunt dissection, followed by cautery with success rate of 65±85% ([14, 15](#)). Chemical cautery followed by daily use of silver nitrate stick can initiate adequate destruction to affect wart clearance, but pigmented scars may develop occasionally ([16](#)). The destruction caused by the CO2 laser has been used to treat viral warts with 64±71% success rate ([17, 18](#)). The use of the pulsed dye laser depends upon the energy absorption within the capillary loops of the wart and hence localized tissue necrosis. Uncontrolled studies have suggested a wart clearance rate of 70±90 % ([19, 20](#)) and a patient clearance rate of 48% ([21](#)). Photodynamic therapy produced a significant improvement in reduction or clearance of wart size after 4 months with irradiation and ALA ([22](#)).

During a study two hundred children with plantar warts were treated with 3% formaldehyde solution for 6±8 weeks and this produced clearance in 80% of wart ([23](#)). Like formaldehyde glutaraldehyde which is available as a 10% solution or gel hardens the skin and makes paring easier ([24](#)). But it has the disadvantage of staining the skin brown, also cutaneous necroses following the application of 20% glutaraldehyde have been reported ([25](#)). podophyllin, acts as a mitotic poison by binding to the spindle during mitosis and the agent is used extensively in the treatment of anogenital warts, but podophyllin is much less effective in the treatment of skin warts because of poor penetration of a thick stratum corneum. If applied under occlusion

after paring of the wart (see Keratolytics section), the treatment may be effective, but there is risk of sterile pustule formation, intense inflammation, and secondary infection ([26](#)).

Bleomycin response rates of between 31% and 100% have been reported but Pain both on application and afterwards is the main limiting factor ([27](#)). The resultant necrosis can cause pigmentary change, scarring, and nail damage [37](#) and cannot be used in pregnant women ([28](#)). Retinoids can reduce bulk of the wart by disrupting epidermal growth and differentiation. In a study a randomized controlled trial of 25 children treated with 0.05% tretinoin cream showed clearance rates of 85% of the children compared with 32% in 25 controls([29](#)).

The delayed hypersensitivity induction has been used as a treatment of warts. Dinitrochlorobenzene and squaric acid dibutylester ([30,31](#)) have been used but most studies have looked at the effect of diphencyprone. Two large open studies of diphencyprone have shown encouraging results. In one, diphencyprone was applied for 8 weeks on weekly basis in 134 patients and gave a response rate of 60% (complete clearance 44% of individuals at 4 months) ([32](#)). Cimetidine use to treat warts has been advocated due to its undefined immunomodulatory effects. Several open trials suggested efficacy, but a controlled trial showed no advantage over placebo([9](#)).

Many other treatments have been used to treat warts, although few have received adequate assessment. Folk remedies are still practiced but remain unevaluated ([33,34](#)). Homoeopathy (Strength of evidence: D, I), using a variety of remedies including sulphur, calcium, and sodium has shown no benefit over placebo ([8](#)) Hypnosis has been evaluated in a double-blind, placebo-controlled trial of 40 individuals treated over 6 weeks. The hypnosis-treated group lost more warts than individuals treated either with topical salicylic acid or with placebo ([35](#)). Local heat treatment has been tested in 13 patients, of 29 treated warts, 41% of placebo treated warts regressed while 86% cleared ([36](#)). In limited number of open trials Intra lesion interferon has shown some effect in cutaneous warts ([37](#)). Topical imiquimod applied in a 5% cream for 9±11 weeks has been used in a small number of patients, including immunosuppressed individuals, with encouraging results([38](#)).

In present study efficacy of sodium bicarbonate was studied in treating warts. It has leavening properties, meaning, it causes dough to rise by releasing CO<sub>2</sub> and has antiseptic properties ([39](#)). Sodium bicarbonate has anti tumour activity. This acid-outside plasmalemmal pH gradient acts to exclude weak base drugs such as the anthracyclines and vinca alkaloids, a behaviour that is predicted by the decrease in octanol-water partition coefficients of mitoxantrone and doxorubicin with decreasing solution pH. Sodium bicarbonate helps in reducing the acidic extracellular pH in tumours. This pH gradient can be reduced or eliminated in mouse models of breast cancer by systemic treatment with sodium bicarbonate. Intraperitoneal administration of NaHCO<sub>3</sub> to tumour-bearing C3H/Hen mice prior to treatment with mitoxantrone results in a greater-than 4.5-fold increase in cell-kill in the syngeneic C3H mammary tumour model. Tumour alkalinization following chronic ad libitum administration of NaHCO<sub>3</sub> and acute intraperitoneal administration of NaHCO<sub>3</sub> to tumour-bearing mice has been detected. Chronic treatment of tumour-bearing SCID mice with NaHCO<sub>3</sub> results in an enhancement in MCF-7 tumour xenograft response to doxorubicin. Most combination chemotherapy regimens include at least one weak base drug. The results of the study suggest that agents such as sodium bicarbonate, Carbicarb and the diuretic furosemide--which are known to induce metabolic alkalosis in humans--may be useful in enhancing the efficacy of these treatment regimens in humans ([9](#)).

Sodium bicarbonate has antibacterial activity. Multiple, brief exposures of sucrose-colonized *S* mutans to sodium dodecylsulfate and sodium bicarbonate caused statistically significant decreases in numbers of viable cells. Use of oral health care products with high concentrations of sodium bicarbonate could conceivably result in decreased levels of cariogenic *S* mutans in saliva and plaque (10). Sodium bicarbonate has antifungal activity. Injection of Sabouraud dextrose-chloramphenicol agar supplemented with 10 g/L of sodium bicarbonate has shown more antifungal activity as compared to Sabouraud dextrose-chloramphenicol agar without sodium bicarbonate (11)

In present study the anti-wart activity of sodium bicarbonate was evaluated. The results of the study revealed that sodium carbonate is a potent anti-wart agent. The anti-wart activity of sodium bicarbonate may be due to alkalization of the wart area which makes it unfits for the HPV and wart cells to sustain, grow, and divide. It may be also due to release of CO<sub>2</sub> by sodium bicarbonate and making the wart area oxygen deficient and killing the wart cells by anoxia and pH variation. Wart cells require higher levels of oxygen due to their increased rate of metabolism and cell division. Further it may be due to both of these factors along with other ones and the antimicrobial activity of castor oil which are to be determined by controlled studies.

In present study sodium bicarbonate was used with and without castor oil. However the anti-wart activity of sodium bicarbonate remained unaffected. Further no secondary infection was found which could be due to antibacterial and antifungal activity of sodium bicarbonate and castor oil. No staining of skin, any scar formation, skin itching, inflammation, pain, or cutaneous necrosis was observed which could be attributed to the antiseptic properties of sodium bicarbonate (39).

Although sodium bicarbonate has many domestic and medical, traditional and empirical uses, only little scientific documentation of its activity is available (11). In this direction there is need to conduct more research work to evaluate the efficacy of anti -wart activity of sodium bicarbonate.

## Conclusion

Treatment of warts by sodium bicarbonate could be a cheap, affordable and easily available remedy to patients. It may result as a relief to millions of people suffering from warts. It also suggest sodium bicarbonate a valuable anti-cancer agent, however only little scientific documentation of its activity is available. There is need to study these properties of sodium bicarbonate in controlled experiments.

**Ethics :** The study was undertaken with the consent of the patient and permission was taken from the local ethical committee. Further the images were taken and presented in the paper with permission of the patient concerned. Before conducting the study, the effects of sodium bicarbonate on the human skin was surveyed in the literature and evaluated.

**Disclaimer:** It needs further study on anti-wart activity of sodium bicarbonate and evaluation by scientific organizations. The study itself does not prescribe sodium bicarbonate as a treatment for skin warts.

## References

1. Davis, M.D., Gostout, B.S., Persing, D.H., Schut, R.L. and Pittelkow, M.R., 2000. Large plantar wart caused by human papillomavirus-66 and resolution by topical cidofovir therapy. *Journal of the American Academy of Dermatology*, 43(2), pp.340-343.
2. Porro, A.M., Alchorne, M.M.A., Mota, G.R., Michalany, N., Pignatari, A.C.C. and Souza, I.E., 2003. Detection and typing of human papillomavirus in cutaneous warts of patients infected with human immunodeficiency virus type 1. *British Journal of Dermatology*, 149(6), pp.1192-1199.
3. Plasencia, J.M., 2000. Cutaneous warts: diagnosis and treatment. *Primary Care: Clinics in Office Practice*, 27(2), pp.423-434.
4. Hahnemann S. Organon of Medicine. Reprint. 6th ed. New Delhi: B. Jain Publishers; 1983. p. 236.
5. Bunney MH, Nolan MW, Williams DA (1976) An assessment of methods of treating viral warts by comparative treatment trials based on a standard design. *British Journal of Dermatology*, 94: 667-679.
6. Larsen PØ, Laurberg G (1996) Cryotherapy of viral warts. *Journal of dermatological treatment* 7: 29-31.
7. Berth-Jones J, Hutchinson PE (1992) Modern treatment of warts: cure rates at 3 and 6 months. *British Journal of Dermatology* 127: 262-265.
8. Sabharwal, A. and Scannapieco, F.A., 2017. Baking soda dentifrice and periodontal health: A review of the literature. *The Journal of the American Dental Association*, 148(11), pp.S15-S19.
9. Raghunand N, Gillies RJ (2001) November. pH and chemotherapy. In Novartis Foundation Symposium (pp. 199-211). Chichester; New York; John Wiley; 1999.
10. Drake D (1996) Antibacterial activity of baking soda. *Compendium of continuing education in dentistry*. (Jamesburg, NJ: 1995). Supplement, 17: 17-21.
11. Letscher-Bru V, Obszynski CM, Samsoen M, Sabou M, Waller J, Candolfi E (2013) Antifungal activity of sodium bicarbonate against fungal agents causing superficial infections. *Mycopathologia* 175: 153-158.
12. Bacelieri, R. and Johnson, S.M., 2005. Cutaneous warts: an evidence-based approach to therapy. *American family physician*, 72(4), pp.647-652.
13. Gaspar ZS, Dawber RP (1997) An organic refrigerant for cryosurgery: Fact or fiction?. *Australasian journal of dermatology* 38: 71-72.
14. Vickers CFH (1961) Treatment of plantar warts in children. *British medical journal*, 2(5254), p.743.
15. Pringle WM, Helms DC (1973) Treatment of plantar warts by blunt dissection. *Archives of dermatology*, 108: 79-82.
16. Yazar Ş, Başaran E (1994) Efficacy of silver nitrate pencils in the treatment of common warts. *The Journal of dermatology* 21: 329-333.
17. Street ML, Roenigk RK (1990) Recalcitrant periungual verrucae: the role of carbon dioxide laser vaporization. *Journal of the American Academy of Dermatology*, 23: 115-120.
18. Sloan K, Haberman H, Lynde CW (1998) Carbon dioxide laser-treatment of resistant verrucae vulgaris: retrospective analysis. *Journal of cutaneous medicine and surgery* 2: 142-145.
19. Jain A, Storwick GS (1997) Effectiveness of the 585nm flashlamp-pulsed tunable dye laser (PTDL) for treatment of plantar verrucae. *Lasers in Surgery and Medicine: The Official Journal of the American Society for Laser Medicine and Surgery* 21: 500-505.
20. Kenton-Smith J, Tan ST (1999) Pulsed dye laser therapy for viral warts. *British journal of plastic surgery* 52: 554-558.
21. Ross BS, Levine VJ, Nehal K, Tse Y, Ashinoff R (1999) Pulsed dye laser treatment of warts: an update. *Dermatologic surgery* 25: 377-380.



22. Stender IM, Na R, Fogh H, Gluud C, Wulf HC (2000) Photodynamic therapy with 5-aminolaevulinic acid or placebo for recalcitrant foot and hand warts: randomised double-blind trial. *The Lancet* 355: 963-966.
23. Anderson I, Shirreffs E (1963) The treatment of plantar warts. *British Journal of Dermatology* 75: 29-32.
24. Hirose R, Hori M, Shukuwa T, Udono M, Yamada M, Koide T, Yoshida H (1994) Topical treatment of resistant warts with glutaraldehyde. *The Journal of dermatology*, 21: 248-253.
25. Prigent F, Iborra C, Meslay C (1996) Glutaraldehyde-induced cutaneous necrosis after topical treatment of a wart. In *Annales de dermatologie et de venerologie* (Vol. 123, No. 10, pp. 644-646). 120 BLVD Saint-Germain, 75280 Paris 06, France: Masson Editeur.
26. Duthie DA, McCallum DI (1951) Treatment of plantar warts with elastoplast and podophyllin. *British medical journal*, 2(4725), p.216.
27. James MP, Collier PM, Aherne W, Hardcastle A, Lovegrove S (1993) Histologic, pharmacologic, and immunocytochemical effects of injection of bleomycin into viral warts. *Journal of the American Academy of Dermatology* 28: 933-937
28. Hayes ME, O'Keefe EJ (1986) Reduced dose of bleomycin in the treatment of recalcitrant warts. *Journal of the American Academy of Dermatology* 15: 1002-1006.
29. Munn SE, Higgins E, Marshall M, Clement M (1996) A new method of intralesional bleomycin therapy in the treatment of recalcitrant warts. *British Journal of Dermatology* 135: 969-971.
30. Kubeyinje EP (1996) Evaluation of the efficacy and safety of 0.05% tretinoin cream in the treatment of plane warts in Arab children. *Journal of dermatological treatment* 7: 21-22.
31. Gelmetti C, Cerri D, Schiuma AA, Menni S (1987) Treatment of extensive warts with etretinate: a clinical trial in 20 children. *Pediatric dermatology* 4: 254-258.
32. Shah KC, Patel RM, Umrigar DD (1991) Dinitrochlorobenzene treatment of verrucae plana. *The Journal of dermatology* 18: 639-642.
33. Iijima S, Otsuka F (1993) Contact immunotherapy with squaric acid dibutylester for warts. *Dermatology*, 187: 115-118.
34. Rampen, F.H.J. and Steijlen, P.M., 1996. Diphencyprone in the management of refractory palmoplantar and periungual warts: an open study. *Dermatology*, 193(3), pp.236-238.
35. Spanos NP, Williams V, Gwynn MI (1990) Effects of hypnotic, placebo, and salicylic acid treatments on wart regression. *Psychosomatic Medicine* 52: 109-114.
36. Stern P, Levine N (1992) Controlled localized heat therapy in cutaneous warts. *Archives of dermatology* 128: 945-948.
37. Gibson JR, Harvey SG, Kemmett D, Salisbury J, Marks P (1986) Treatment of common and plantar viral warts with human lymphoblastoid interferon- $\alpha$ —pilot studies with intralesional, intramuscular and dermojet injections. *British Journal of Dermatology* 115: 76-79.
38. Hengge, U.R., Esser, S., Schultewolter, T., Behrendt, C., Meyer, T., Stockfleth, E. and Goos, M., 2000. Self-administered topical 5% imiquimod for the treatment of common warts and molluscum contagiosum. *British Journal of Dermatology*, 143(5), pp.1026-1031.
39. Kothiwale, S., Kella, M., Hombal, L. and Rathore, A., 2014. Evaluation of sodium bicarbonate as an adjunct to non surgical periodontal therapy and its effect on oxidative stress: A clinico-biochemical study. *J Dent Oral Disord Ther*, 2(2), p.5.