

Roll of Computed Tomography in Evaluation of NCCT Paranasal sinuses

Ms. Nisha Jhinkwan,⁽¹⁾ , Mr. Binoo parihar,⁽²⁾ Mr. Arshad alam khan,⁽³⁾ Ms. Ashita Jain,⁽⁴⁾ Ms. prachi Vishnoi,⁽⁵⁾ Mr. Pradeep Bansal⁽⁶⁾,

Assistant Professor (Paramedical Department)

Department of Radio Diagnosis, Imaging & Interventional Radiology.

Abstract:

Aim: this study aims to evaluate to accurate diagnose the diseases of paranasal sinuses.

Subjects and Methods:

All patients underwent Noncontrast CT (NCCT) of PNS on multi-detector CT Philips 128 multi-slice unit.

Result:

A Maximum number of patients were in the age group of 16-30 years. The predominant chief presenting complaint was headache, followed by nasal discharged. The most common CT diagnosis was chronic sinusitis, mucosal thickening. Minimum patient's diagnoses was polypoidal cyst and mass lesion.

Conclusion:

To conclude, this study proved good result of CT evaluation of diseases of paranasal sinuses.

Introduction:

Computed tomography (CT) of the sinuses uses special x-ray equipment to evaluate the paranasal sinus cavities – hollow, air-filled spaces within the bones of the face surrounding the nasal cavity. CT scanning is painless, noninvasive and accurate. It's also the most reliable imaging technique for determining if the sinuses are obstructed and the best imaging modality for sinusitis.

Computed tomography, more commonly known as a CT or CAT scan, is a diagnostic medical test that, like traditional x-rays, produces multiple images or pictures of the inside of the body.

The cross-sectional images generated during a CT scan can be reformatted in multiple planes, and can even generate three-dimensional images. These images can be viewed on a computer monitor, printed on film or transferred to a CD or DVD.

CT images of internal organs, bones, soft tissue and blood vessels provide greater detail than traditional x-rays, particularly of soft tissues and blood vessels.

A CT scan of the face produces images that also show a patient's paranasal sinus cavities. The paranasal sinuses are hollow, air-filled spaces located within the bones of the face and surrounding the nasal cavity, a system of air channels connecting the nose with the back of the throat. There are four pairs of sinuses, each connected to the nasal cavity by small openings.

CT of the sinuses is primarily used to:

- Help diagnose sinusitis.
- Evaluate sinuses that are filled with fluid or thickened sinus membranes.
- Detect the presence of inflammatory diseases.
- Provide additional information about tumors of the nasal cavity and sinuses.
- plan for surgery by defining anatomy.[1]

CAUSES OF INFECTION

Chronic sinusitis is a common condition in which the cavities around nasal passages (sinuses) become inflamed and swollen for at least 12 weeks, despite treatment attempts.

Also known as chronic rhino sinusitis, this condition interferes with drainage and causes mucus buildup. Breathing through your nose might be difficult. The area around your eyes and face might feel swollen, and you might have facial pain or tenderness.

Chronic sinusitis can be brought on by an infection, by growths in the sinuses (nasal polyps) or by a deviated nasal septum. The condition most commonly affects young and middle-aged adults, but it also can affect children.

Chronic sinusitis and acute sinusitis have similar signs and symptoms, but acute sinusitis is a temporary infection of the sinuses often associated with a cold. The signs and symptoms of chronic sinusitis last longer and often cause more fatigue. Fever isn't a common sign of chronic sinusitis, but you might have one with acute sinusitis. [2,3]

COMMON CAUSES OF CHRONIC SINUSITIS INCLUDE:

- Nasal polyps. These tissue growths can block the nasal passages or sinuses.
- Deviated nasal septum. A crooked septum — the wall between the nostrils — may restrict or block sinus passages.
- Other medical conditions. The complications of cystic fibrosis, gastro esophageal reflux, or HIV and other immune system-related diseases can result in nasal blockage.
- Respiratory tract infections. Infections in your respiratory tract — most commonly colds — can inflame and thicken your sinus membranes and block mucus drainage. These infections can be viral, bacterial or fungal.
- Allergies such as high fever. Inflammation that occurs with allergies can block your sinuses.[4,5]

SYMPTOMS

At least two of the four primary signs and symptoms of chronic sinusitis must be present with confirmation of nasal inflammation for a diagnosis of the condition. They are:

- Thick, discolored discharge from the nose or drainage down the back of the throat (postnasal drainage)
 - Nasal obstruction or congestion, causing difficulty breathing through your nose
 - Pain, tenderness and swelling around your eyes, cheeks, nose or forehead
 - Reduced sense of smell and taste in adults or cough in children.[6]
- You're at increased risk of getting chronic or recurrent sinusitis if you have:
- A nasal passage abnormality, such as a deviated nasal septum or nasal polyps
 - Asthma, which is highly connected to chronic sinusitis
 - Aspirin sensitivity that causes respiratory symptoms
 - An immune system disorder, such as HIV/AIDS or cystic fibrosis
 - High fever or another allergic condition that affects your sinuses
 - Regular exposure to pollutants such as cigarette smoke[7]

MATERIAL AND METHODS**DESIGN:**

Role of Computed Tomography in evaluation of Paranasal Sinuses.

TYPE OF STUDY:

Prospective study.

SETTING:

Department of Radio diagnosis, Imaging & Interventional Radiology N.S.C.B Subharti Medical College, CSS Hospital, Meerut.

PARTICIPANTS:

The source of data for this study are patients referred to Department of Radio diagnosis, Imaging and interventional radiology from OPD/IPD of C.S.S. Hospital, under the ageis of N.S.C.B Subharti Medical College, Meerut for a period of 2 years, from 1st Jan 2018 to 30 May 2018.

INCLUSION CRITERIA:

All the patients with clinically suspected nasal infection

EXCLUSION CRITERIA:

1. Patients in whom CT could not be performed.
2. Pregnancy

METHOD OF COLLECTION OF DATA:

After obtaining clinical history relevant clinical examination will be done.

CT examinations will be done on Phillips Ingenuity Core 128 slice CT.

SOURCE OF DATA:

CSSH-NSCBSMC – ChhatrapatiShivaji Subharti Hospital, N.S.C.B. Subharti Medical College
Swami Vivekanand Subharti University, Meerut U.P.

INCLUSION CRITERIA:

- All patients undergoes with clinically symptoms of headache nasal bleeding or nausea.
- Cases were included irrespective of age/sex.

EXCLUSION CRITERIA:

1. Pregnancy
2. Patient who did not give consent
3. All operated cases
4. Uncooperative patient

STATISTICAL ANALYSIS:

- Data are collected and performed in excel, after that all data is analyzed by using SPSS 19 version software.
- For all data frequencies, table graph are plotted and by applying chi-square test with p-value and sensitivity, specificity, PPV and NPV has been calculated.

CRITERIA FOR PATIENT'S SELECTION:

- The patients selected for the study were clinically suspected of headache, nasal bleeding etc.
- A detailed history was taken and clinical examination was done.
Materials used were CT scanner Philips ingenuity 128slice, Contrast media Non-ionic (Iohexol), and Emergency drugs like Inj. Avil, Dexamethasone, and Adrenalin, Syringes 5ml, 10ml and 20 ml.

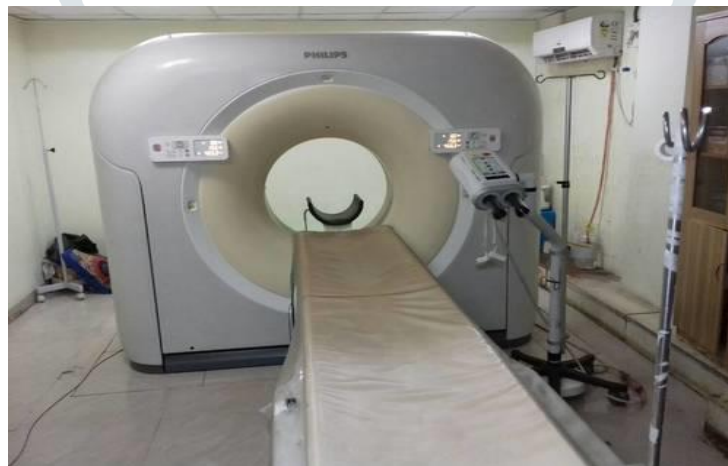

FIG: CT SCANNER PHILIPS INGUINITY 128 SLICE

INDICATION:

- Intermittent headache
- Nasal bleeding
- Nasal block
- Sinusitis
- Trauma
- Post op evaluation

FOR CONTRAST STUDY:

- Mass lesion
- Tumors
- Complicated sinusitis

CONTRAINDICATION:

Pregnancy

EQUIPMENT:**GANTRY**

- The major components of the imaging system are the X-ray tube and generator, collimators, filters, detectors and detector electronics.
- The X-ray tube and generator are responsible for X-ray production.
- The collimators help define the slice thickness and restrict the X-ray beam to the cross section of interest.
- The detectors capture the X-ray photon and convert them into electrical signal (Analog information); the detectors electronics, or data acquisition system (DAS) converts this information into digital data.
- The computer system receives the digital data from the DAS and processes it to reconstruct an image of the cross-sectional anatomy.

PATIENT TABLE

- The Patient couch, or patient table, provide a platform on which the patient lies during the examination.
- The couch should be strong and rigid to support the weight of the patient.
- Additionally it should provide for safety and comfort of the patient during the examination.

PATIENT PREPARATION:

- Before patient preparation, complete history should be checked. If indication is unclear, the referring physician should be contacted.
- A satisfactory written consent from must be taken from the patient before entering the scanner room.
- Ask the patient to remove all metallic objects including keys, coins, wallet, and cards with magnetic strips, jewelry, hearing aid and hairpins.
- Explain the procedure to the patient.
- The patient should be instructed to avoid coughing, wriggling or producing other large motion during or in between the scans.
- Ensure the IV line prior to the pre-contrast acquisition preferably with 20 or 22 Gauge IV cannula.

POSITION:

- Patient should lies on the CT table in supine position.
- Center the table height such that the external auditory meatus (EAM) is at the center of the gantry.
- To reduce or avoid ocular lens exposure, the scan angle should be parallel to a line created by the supraorbital ridge and the inner table of the posterior margin of the foramen magnum.
- This may be accomplished by either tilting the patient's chin toward the chest ("tucked" position) or tilting the gantry. While there may be some situations where this is not possible due to scanner or patient positioning limitations, it is considered good practice to perform one or both of these maneuvers whenever possible.

CT PROTOCOL AND TECHNIQUE:

PARAMETERS	
Patient position	Supine
Patient orientation	Head first
Centre	At glabella
Planning	frontal bone to bottom of maxilla
Field of View	350 mm
Mode of sequence	Inspiratory scan
Scan type	Axial/helical
Scan orientation	Caudo-cranial
Gantry Tilt	No
Slice thickness	5 mm
Filter	Standard
Pitch	1
Reconstruction	1.5 mm
KVp	120
mAs	240

Result:

The study was conducted from 1st Jan 2017 to 30 May 2018. This study included all the patients who were referred by the clinical departments of CSS hospital, N.S.C.B. Subharti Medical College Meerut, with clinically suspected to headache, nausea and other clinically indication of PNS. Detailed history and relevant examination was done and recorded. A total number of 50 cases were evaluated in our study. CT was done as requested by the clinical departments.

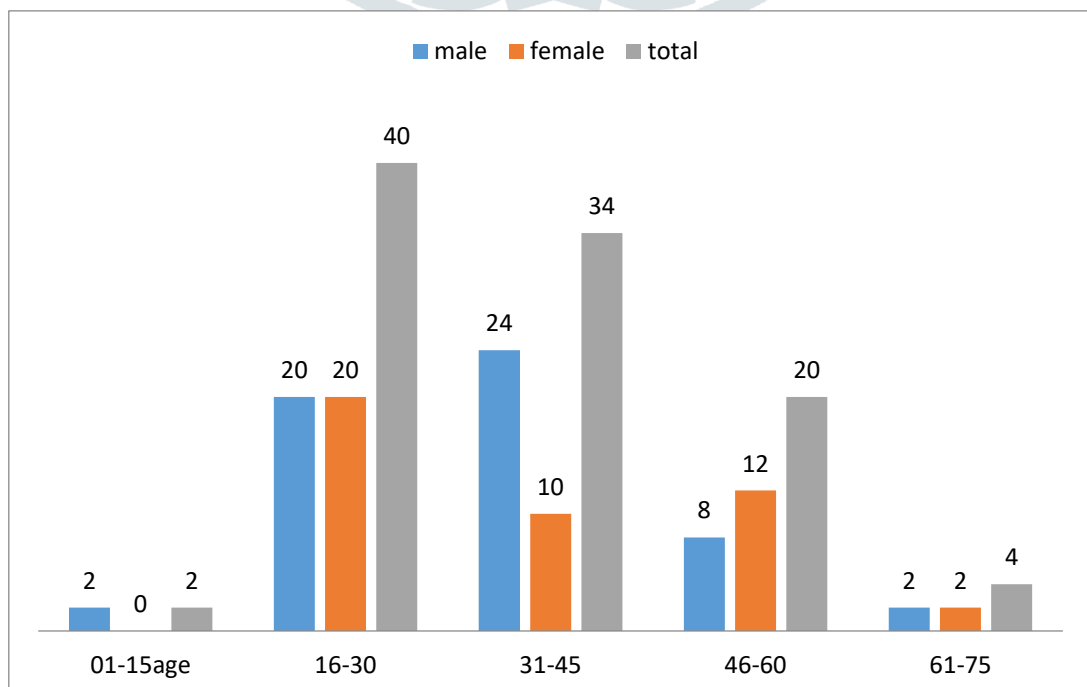
Patients were evaluated in the form of brief requisition (Annexure I) and then subjected to NCCT PNS as advised. On these scans, the imaging evaluation in the form of etiological factor for pathological condition, its location and characteristics was done.

DEMOGRAPHIC DISTRIBUTION

TABLE 1: AGE WISE DISTRIBUTION

AGE GROUP	MALE		FEMALE		TOTAL	
	FREQ	%	FREQ	%	FREQ	%(50)
0-15	01	2	0	0	1	2
16-30	10	20	10	20	20	40
31-45	12	24	05	10	17	34
46-60	04	8	06	12	10	20
61-75	01	2	01	2	2	4

GRAPH NO. 1: AGE WISE DISTRIBUTION

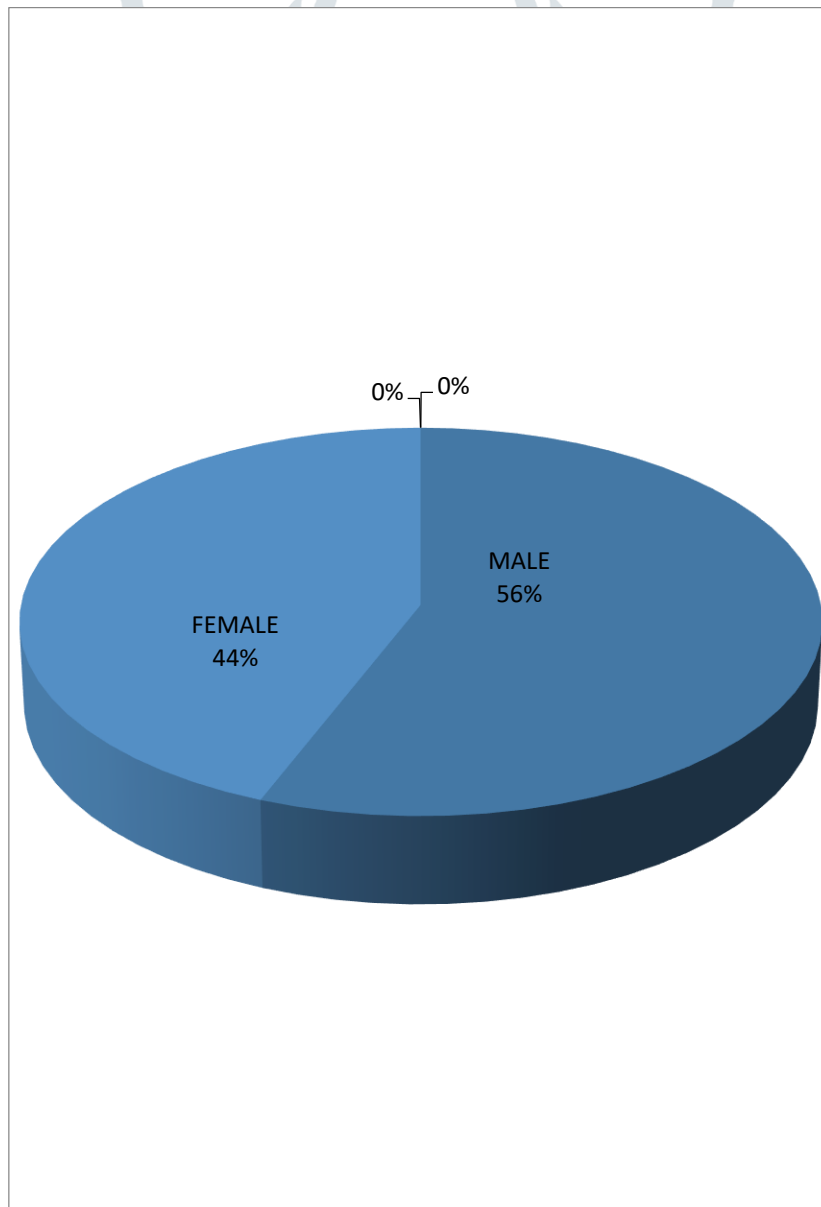


- In present study the highest number of patients was in 16-30 years of group (40%).
- Followed by 35-45 years of group (34%).
- The lowest number of age group 1-15 year of age comprising (2%).

TABLE 2: GENDER WISE DISTRIBUTION OF PATIENTS

GENDER	MALE		FEMALE		TOTAL	
	FREQUENCY	%	FREQUENCY	%	FREQUENCY	%
TOTAL	28	56	22	44	50	100

GRAPH NO. 2: GENDER WISE DISTRIBUTION OF PATIENTS



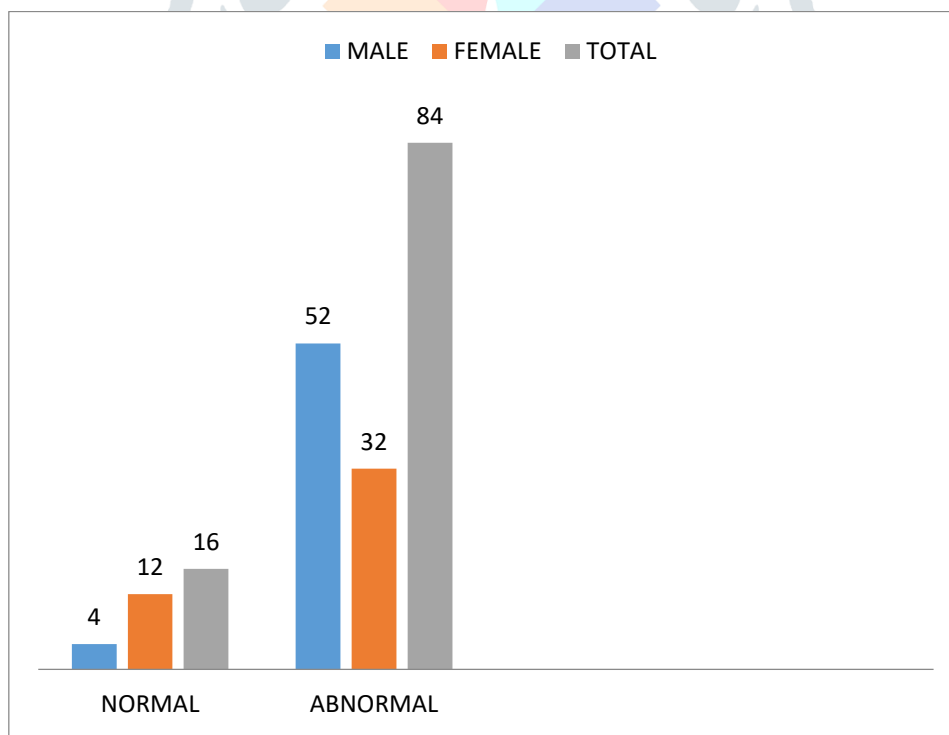
- In present study we show that male patient were effected more than female.
- In this study it was observed that 56% male and 44% female patients.

TABLE 3: ON THE BASIS OF NORMAL AND ABNORMAL PATIENT

CT DIAGNOSE	MALE		FEMALE		TOTAL	
	FREQ	%	FREQ	%	FREQ	%
NORMAL	2	4	6	12	8	16
ABNORMAL	26	52	16	32	42	84

$\chi^2 = 3.7144,$ p value =.053

GRAPH 3: ON THE BASIS OF NORMAL AND ABNORMAL PATIENT

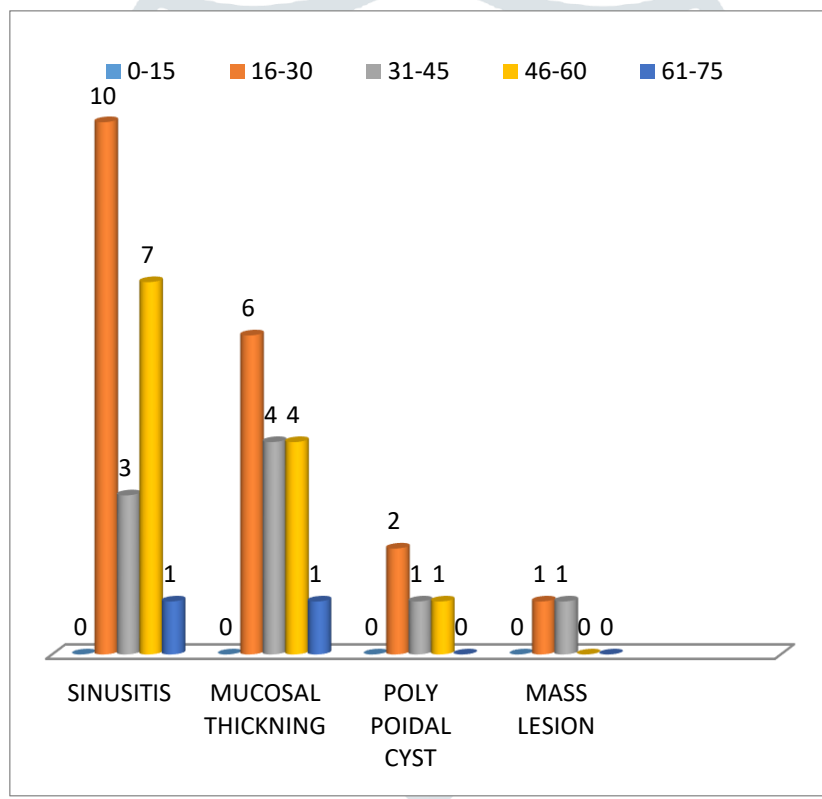


- In our study we observed that 16% of patient were normal and 84% patient were shows pathology.
- This was most commonly found in male 52% and female shows only 32%.

TABLE 4: DISTRIBUTION OF ABNORMALITIES IN VARIOUS AGE GROUP

CT DIAGNOSE	0-15	16-30	31-45	46-60	61-75	TOTAL	%
SINUSITIS	0	10	3	7	1	21	50
MUCOSAL THICKNING	0	6	4	4	1	15	35.71
POLYPOIDAL CYST	0	2	1	1	0	4	9.52
MASS LESION	0	1	1	0	0	2	4.76

GRAPH 4: DISTRIBUTION OF ABNORMALITIES IN VARIOUS AGE GROUP



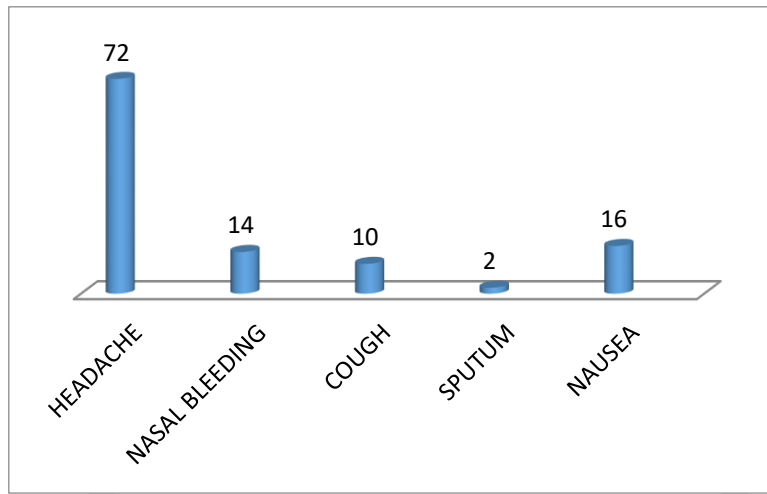
- Sinusitis was present in most of the cases 21 (50%) patient.
- It was mostly found in the age group of 16-30years10 patient.
- 0-15years none of the case was observed.

TABLE 5: DISTRIBUTION OF CLINICAL HISTORY

CLINICAL HISTORY	FREQUENCY	PERCENT
HEADACHE	36	72
NASAL BLEEDING	7	14
COUGH	5	10

SPUTUM	1	2
NAUSEA	8	16

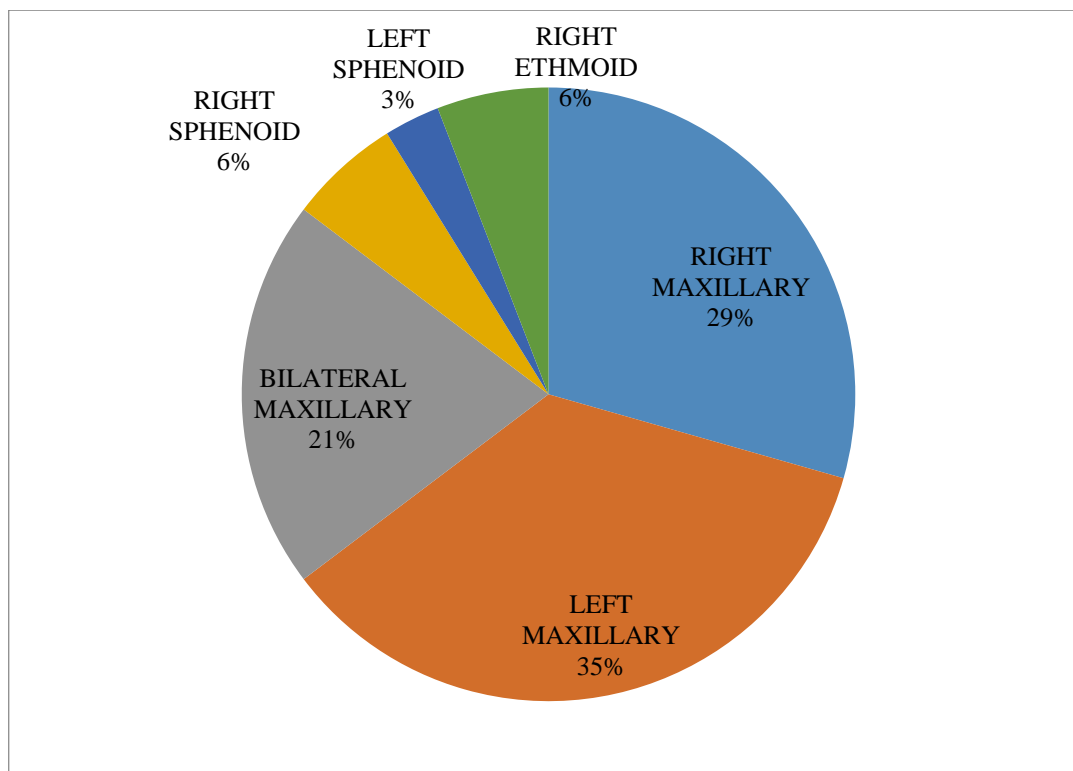
GRAPH 5: DISTRIBUTION OF CLINICAL HISTORY



- Headache was the most common clinical symptoms 36 (70%) patient.
- Nasal bleeding found in 7 (14%) patient.

TABLE 6: DISTRIBUTION ON THE BASIS OF FINDING LOCATION

LOCATION	NO. OF PATIENT
LEFT MAXILARY	12
B/L MAXILARY	7
RIGHT SPHENOID	2
LEFT SPHENOID	1
RIGHT ETHMOID	2
LEFT ETHMOID	1
B/L ETHMOID	2
RIGHT FRONTAL ETHMOID	3
LEFT FRONTAL ETHMOID	2

GRAPH 6: DISTRIBUTION ON THE BASIS OF FINDING LOCATION

- On the basis of location left maxillary were most commonly effected 12(35%) patient.
- Left maxillary also effected after the right maxillary (29%).
- Left Sphenoid was less affected only 3% patient.

Discussion:

In the present study we have selected 50 patients, we found that male 28 (56%) and female 22(44%) in number male: female ratio of 1.2:1.

SINUSITIS:

In present study sinusitis was the most common pathology that show in most of the patient 21 (50%).

MUCOSAL_THICKNING:

In present study mucosal thickening was shows in 15 (35.71%) patient and was second most common pathology.

POLYPOIDAL_CYST:

In present study polypoidal cyst was show in 4 (9.52%) patient.

MASS LESION:

In present study mass lesion was present in very few patient 2 (4.76%).

ON THE BASIS OF LOCATION:

In present study most of the patient's location were left maxillary (12 patient) followed by right maxillary (10patient). Left sphenoid and left ethmoid was in few patient that show the location.

CONCLUSION

CT scan is the investigation of choice in patients with clinically suspected with headache, nasal bleeding, and nausea. However due to concern regarding radiation exposure, sonogram are reemerging as imaging method in such situations. Accurate diagnosis of the NCCT PNS is crucial for finding an effective treatment. CT scan has emerged as a versatile and reliable tool in the evaluation of patients with NCCT PNS, and location of disease.

Our study concluded 50patient that have symptoms of study in this 8patient was normal and 42 were abnormal that show pathology.

In our study 21 (50%) patient shows sinusitis in this most of the patient were in the age of 16-30 years (10 patient). Sinusitis was most commonly found in male, mucosal thickening shows in 15(35.71%) patient and it shows mainly in the age group of 16-30years (6patient), polypoidal- cyst shows in 4 (9.52%) patient and most commonly in the age group of 16-30years (2patient), Mass lesion was present in 2patient.

Most commonly effected side was left maxillary.

Our study observed that CT scan with appropriate imaging parameters adds sensitivity and specificity in evaluation of PNS.

CT scan may be useful as a complimentary/adjunct modality to increase the diagnostic read of the PNS in patients with in clinical documented pathology. Since this study contains small sample size with possibility of inherent bias. A large study is warranted to confirm the findings of this study.

CT is a safe and reliable technique for the study of PNS to evaluate accurate disease.

REFERENCES:

1. <https://www.radiologyinfo.org/en/info.cfm?pg=sinusct>
2. Sinusitis. American Academy of Allergy, Asthma & Immunology. <http://www.aaaai.org/conditions-and-treatments/allergies/sinusitis.aspx>. Accessed Jan. 11, 2016.
3. Hamilos DL. Chronic rhino sinusitis: Clinical manifestations, pathophysiology and diagnosis. <http://www.uptodate.com/home>. Accessed Jan. 11, 2016.
4. Sinusitis (sinus infection). National Institute of Allergy and Infectious Diseases. <http://www.niaid.nih.gov/topics/sinusitis/pages/index.aspx>. Accessed Jan. 14, 2016.
5. Complications of sinusitis. American Rhinologic Association. http://care.american-rhinologic.org/complications_sinusitis. Accessed Jan. 14, 2016.
6. Rosenfeld RM, et al. Clinical practice guideline (update): Adult sinusitis. *Otolaryngology — Head and Neck Surgery*. 2015; 152:S1.
7. Adult sinusitis. American Rhinologic Association. http://care.american-rhinologic.org/adult_sinusitis. Accessed Jan. 15, 2016.
8. Cebula M, Danielak-Nowak M, Modlinska S. Impact of Window Computed Tomography (CT) Parameters on Measurement of Inflammatory Changes in Paranasal Sinuses. *Pol J Radiol*. 2017. 82:567-70. [Medline]. [Full Text].
9. **A John Vartanian, MD, MS, FACS** Assistant Clinical Professor, Department of Surgery, Division of Head and Neck, University of California, Los Angeles, David Geffen School of Medicine; Instructor, Department of Otolaryngology-Head and Neck Surgery, University of Southern California Keck School of Medicine
10. A John Vartanian, MD, MS, FACS is a member of the following medical societies: American Academy of Facial Plastic and Reconstructive Surgery, American College of Surgeons, American Medical Association, American Academy of Otolaryngology-Head and Neck Surgery
11. Euclid Seeram, "Computed Tomography" Physical Principles, Clinical Applications, and Quality Control Third Edition; Copyright 2009
 - a. http://en.wikipedia.org/wiki/Computed_tomography#History
12. Euclid. *Computed Tomography: Physical Principles, Clinical Applications, and Quality Control*. St. Louis: Saunders Elsevier, 2009. <http://pir.georgetown.edu/nbrf/rslibio.html>
13. Angelfire.com/nd/Hussainpassu/physics_of_computed_tomography.pdf
14. BranstetterBF, WissmanJL. Role of MR and CT in the paranasal sinuses. *OtolaryngolClinNAm* 2005;38(6):1279-99.
15. Perez-Pinas, SabateJ, CarmonaA, et al. Anatomical variation in the human paranasal sinus region studied by CT. *JAnat*2000;197(Pt 2):221-7.
16. Lloyd GAS, Lund VJ, ScaddingGK, et al. CT of paranasalsinus and functional endoscopic surgery: a critical analysis of 100 symptomatic patients. *JLO* 1991;105(3):181-5.
17. Computed tomography
18. <http://www.imaginis.com/ct-scan/brief-history-of-ct>.
19. <http://teachmeanatomy.info/head/organs/the-nose/paranasal-sinuses/>
20. Aksoy EA, Ozden SU, Karaarslan E, et al. Reliability of high-pitch ultra-low-dose paranasal sinus computed tomography for evaluating paranasal sinus anatomy and sinus disease. *J Craniofac Surg*. 2014 Sep. 25(5):1801-4.
21. Pirimoglu B, Sade R, Sakat MS, Ogul H, Levent A, Kantarci M. Low-Dose Noncontrast Examination of the Paranasal Sinuses Using Volumetric Computed Tomography. *J Comput Assist Tomogr*. 2018 May/Jun. 42 (3):482-6.
22. Al Abduwani J, ZilinSkienne L, Colley S, Ahmed S. Cone beam CT paranasal sinuses versus standard multidetector and low dose multidetector CT studies. *Am J Otolaryngol*. 2016 Jan-Feb. 37 (1):59-64.
23. Jagram Verma1, Sushant Tyagi1*, Mohit Srivastava2, Aman Agarwal1
Computed tomography of paranasal sinuses for early and proper diagnosis of nasal and sinus pathology [23]
24. Chinnala Sai Chaitanya1 and Atkuri Raviteja2 COMPUTED TOMOGRAPHIC EVALUATION OF DISEASES OF PARANASAL SINUSES
25. ManjitBagul Computed Tomography Study of Paranasal Sinuses Pathologies
26. Branstetter B.F., Weissman J.L.
27. Indian Journal of Otolaryngology and Head & Neck Surgery March 2007, Volume 59, Issue 1, pp 35–40| Cite as Management protocols of Allergic Fungal Sinusitis.