AUTOMATIC SEGMENTATION OF BONE AND CARTILAGES USING ANNOTATED KNEE IMAGES

[1]Aishwarya S, [2]Pooja N, [3]Shashikala K S, [4]Revathi S A

[1]Student, [2]Student, [3]Student, [4]Assistant Professor,
Department of Computer Science,
RV College of Engineering, Bangalore, India.

ABSTRACT

Segmentation of knee bones from MRI has advanced as a tool for the analysis of knee joint pathologies. This paper intended at creating a fully automated bone segmentation model for knee bone and cartilages such as femur and tibia by using annotated MR images. Knee MR Images are pre-processed, augmented, annotated and segmented using Neural Networks. The first step in the proposed model is preprocessing and augmentation where cropping, resizing and resampling occurs. SimpleITK toolkit is a library which provides certain readymade functions for preprocessing and segmentation. In the next step we create annotated images using 3D Slicer. Annotation helps in detecting the object (knee bone and cartilages) from the image. Convolutional neural network method called U-Net is used as the fundamental method to perform segmentation of the knee bones and cartilage. Segmented bones are used for the Age Assessment using the ossification degree of growth plates. Age Prediction is a convoluted process where determining the chronological oldness of a person who lacks the authorized certification is done. While no technique provides a proper method to identify the age, the proposed system helps in analyzing the age using the growth plates present in the bone. This paper provides a step towards a solution by fully automating the extraction of bone in knee MRIs using convolutional neural networks to reduce the data complexity. Furthermore, the discussions concerning the MRI classification results used to segment the bone will be discussed.

***IndexTerms* - Magnetic resonance image, Annotation, U-Net, Age assessment, Augmentation.**

I. INTRODUCTION

Osteoarthritis is a deteriorating knee joint syndrome that occurs because of wear and tear of cartilages existent in the knee joint. This degeneration can be examined by the radiologist with the assistance of MRIs [1]. MR imaging technique is used in a few population-based investigations for many years to deliver significant evidence concerning the essential structures related to the knee discomfort and evolution of the osteoarthritis [4].

In Medical image segmentation, mechanism has to partition the image into different segments, each of them signifying a different entity and in the recent period, the research of deep learning techniques, predominantly the convolutional neural networks (CNN), has been used for muscular and skeleton cartilage segmentation from the MRI [9]. Convolutional Neural Networks gave decent outcomes in easier image segmentation problems but it hasn't made any good improvement on complex ones. That′s where U-Net comes in the picture [2]. U-Net was first intended especially for medical image segmentation.

This project work aims to explain and approve the techniques for segmenting the femur bone, tibia bone and their respective cartilage using U-Net [9]. A noteworthy drawback in the clinical routine of the advanced MRI technique is lengthy image processing time. To measure MRI factors in cartilage, the cartilage requires to be segmented, which is typically done by a human expert, a proficient Radiologist, and takes a few hours to complete segmenting all cartilage. This way of segmentation is not scalable, error-prone, and tremendously slow. Deep learning-based simulations are successful in performing rapidly and accurately.

II. METHODOLOGY

2.1 Pre-processing

2.1.1 Training, Validation, and Testing Sets

The records were divided into 3 subsets and each was used for different purposes such as testing, training and validation. The training part of data is the largest of all these and its data is applied to the authentic learning process.

The validation data is the one which was used to find the performance and also to see if there is any overfitting arise in the model. If the accuracy of the validation set drops lower than the results of the training data, the network is starting to memorize the information it knows rather than generalizing on the theory.

The third subset is stated as the testing data. In contrast to the validation set, it′s only used once in the very end, to give a final score. The indication is that by building a model based on the validation results a convinced amount of evidence bleed occurs, where the network will implicitly absorb from the validation data.

2.1.2 Cropping, Resizing, and Resampling

The framing comprises of large areas of the upper leg and lower leg which were being visible in the image. Since these were not seen as important, they were cropped out. Although there is no hypothetical size limitation to be used in CNNs, it would be necessary to decrease the spatial resolution by resizing and to reduce the calculations performed. So the images were converted to 224 x 224 pixels for each slice, still, the images had factors that helps in identifying the shape of the Femur and Tibial bone, hence the images were resized. To get the images from two different highest sources on a similar scale, different methodologies were tried. Resampling is a process where images are resized by reducing or increasing the number of pixels. Hence the 41 slices per image of the training data were padded with blank pixels to 48 slices.

2.2 Augmentation

Image augmentation is a general method to virtually increase the dataset size. In medical imaging, augmentation is performed with transformations that are applied to the images and labels equally. Image augmentation are performed by the ImageDataGenerator class which is a deep learning library supported by Keras. By supplying different arguments different augmentation steps can be performed. Vertical shift and horizontal shift can be done by passing width_shift_range (24,-24) and height_shift_range (24,-24) parameters, rotation can be done by passing rotation range (90 degree) argument, brightness adjustment by passing brightness range argument. Augmentation methods include a variety of image transformations.

2.3 Annotation

Annotation of an image is a process of labelling and getting the required information associated with the initial image. In the Knee MRI the femur bone, tibia bone and the cartilages are labelled accordingly. It helps in extracting only the object of our concern from the image. Annotation of medical images is very important in constructing Statistical models and in medical fields. 3D Slicer is an open-source software application that can be used for medical image computing. Femur is colored in blue, tibia is colored in green and the cartilages in yellow to differentiate between them.

2.4 Bone segmentation

U-Net model follows the architecture of convolutional neural network which was specially created for segmenting medical images [9]. By merging the local learning patterns of convolutions with the spatial reductions of pooling, the input is compressed to a dense representation of its most important features.

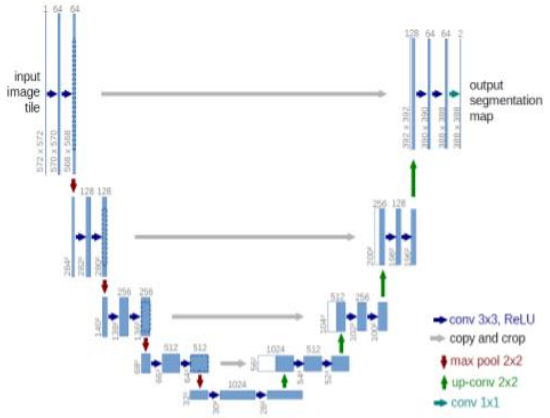

Figure 1 U-Net Architecture

Segmentation is a process where each pixel of an image is classified. As such, early CNN segmentation models used small patches of the input image only to predict a single-pixel through a classification pipeline. Afterward, a full segmentation map was assembled using each of these pixels. This process was very slow, and it also prevented the network to have a field of view larger than the inserted patch. The images were masked with different values for each labels such as background=0, femur=1, femoral cartilage=2, tibia=3, tibial cartilage=4. With this information, it was possible to train a network that would segment the bones and cartilages while still diff erentiating between them. An improvement for segmentations came through architectures referred to as encoder-decoder models.

The encoding process describes the same spatial compression used in classification networks. Afterward, in the decoding step, the spatial resolution is brought back to its original shape and further processed by additional convolutions. This yields huge speed improvements, while also increasing the accuracy of the prediction. The number of parameters in a neural network has a high correlation with its learning capacity. By adding more nodes that can be adjusted during training, the model can approximate a more complex function that transforms the input into the output. The downside is that a larger parameter count will also increase the possibility of overfitting the data. A convention in the field of CNNs is to gradually increase the number of channels, while the spatial resolution is reduced due to the use of Max Pooling. U-Net also shows this behaviour on the left side of its architecture.

2.5 Cartilage segmentation

The white smooth surface present between the femur and the tibia is the articular cartilage. The gradually degradation of this tissue is the main cause of osteoarthritis. The segmentation includes femur, tibia and patella cartilage [4]. Deep CNN model, U-Net is used to segment the MRI dataset. The ground truth required for this process is manual segmentation done by the radiologist [21]. Manual segmentation is a long procedure which is done with careful observation. The automatic segmentation is robust and the results are better than the manual segmentation. Validation of predicted results with respect to the ground truth is evaluated based on:

a. Does the model correctly predict the ground truth?
b. Can the model correctly predict a segment that is not in the ground truth?
c. And if some segments are not found in the segmented image

The evaluation metric used is Dice similarity coefficient. This depends on the overlap of the manual segmentation and automated results. The accuracy of this model is based on the voxel count of the MRI dataset it is mentioned in the results section below [21].

2.6 Age assessment

The age assessment is a complex process used in determining the age of people who does not have proper documentation. Ossification is the natural process of bone formation**.** Ossification degree of growth plates works as an indicator of the age assessment[17]. Therefore, it is necessary to have approaches that enable the discovery of bone structures. In this paper, fully automatic segmentation of knee bone MRI using U-Net is presented.

Multiple pre-processing steps are used in this proposed system to correct and reduce the size of images. Augmentation is a process which increases the size of dataset virtually. The architecture of the segmentation algorithm looks like the encoder-decoder model. Compared to manual segmentations the proposed network attains a (DSC) Dice similarity coefficient score of 98%. Due to the usage of augmentation over fitting was eliminated. As a result, the segmented images can be used for the age estimation of several topics. To make full use of the neural networks and to get an accurate and dependable age prediction, testing must be performed on a large dataset. The proposed segmentation results in the improvement of age estimation methods.

III. RESULTS

3.1 Bone Segmentation

The results in this paper are based on test data set with which network has not been trained with. The network architecture was implemented using a single segmentation channel that merged Femur, Tibia and cartilage maps. However, tests were also run to validate the performance for each bone and cartilage on its own and also combine the three separate predictions into a multichannel segmentation. The same architecture and training procedure was used for this task.

The proposed model achieves a Dice similarity coefficient (DSC) score of 98.0% and an Intersection over Union (IOU) of 96.0%. Precision and Recall are perfectly balanced. The error shows a small value of 1.2%

Table 1 Numeric evaluation of bone segmentations

DICE:	0.981027953039
IoU:	0.962762383775
Precision:	0.98148222917
Recall:	0.980574101198
Error:	0.00370926134877

Combining the three separate segmentations to a single model gives comparable results as well. The error is reduced by a factor of 3, which is expected because the channels are increased by 3. Compared to previous studies, the proposed model shows slightly better results than the multi-atlas segmentation and significantly higher scores than the ray casting technique. The network shows excellent performance on slices of the MR Images often with Dice similarity coefficient (DSC) scores of over 98%.

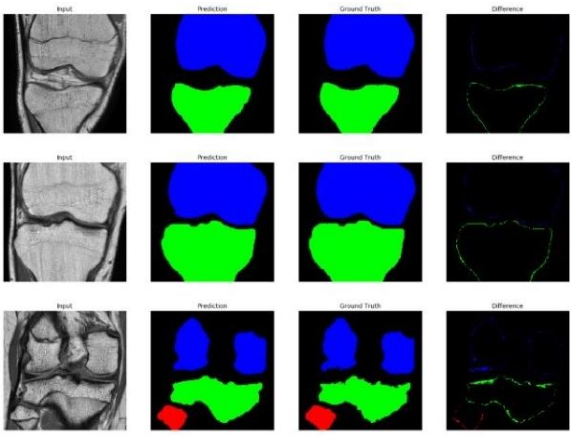

Figure 3 Input, predicted, ground-truth, difference between ground truth & predicted

3.2 Age Assessment

The main goal of this experiment is to implement the automatic segmentation of bone and cartilage. The images obtained after segmentation could then be used to make age assessments that focused on the bone and the growth plate. After performing age assessment the final result displays the percentage of no of candidates who are young and old. The age range is calculated by finding the difference between maximum and minimum age. And the average age is calculated by finding its mean.

Table 2 Numeric evaluation of age assessment

```
Oldest candidate: 20.9
Youngest candidate: 14.4
Age range: 6.5
Average age: 17.4
```

3.3 Cartilage Segmentation

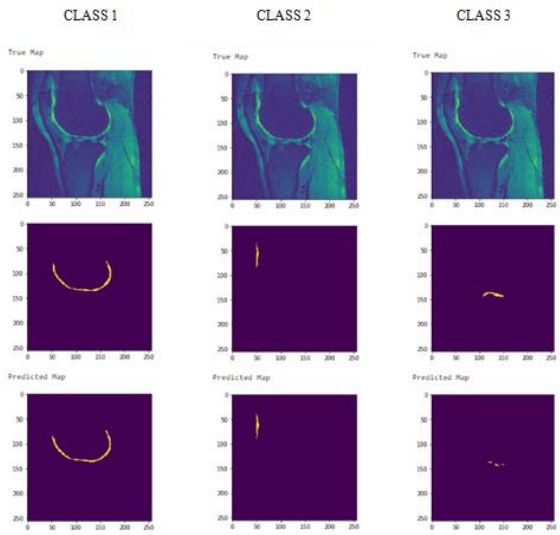

Figure 4 Femur, Patella, and Tibia cartilage segmentations

Fig 4 shows cartilage segmentation of femur, patella, and tibia (class1: Femur, class2: Patella, class3: Tibia). Where first row shows the original image, second row shows the ground truth and the third row shows the predicted image for all three classes [21].

Table 3 Numeric evaluation of cartilage segmentations

```
validate loss: 0.4389, Dice Score (class 0): 0.6701,
Dice Score (class 1): 0.7718, Dice Score (class 2): 0.6211

Out[401]:
(0.4389190546103886,
 0.6701074129059201,
 0.7717708831741696,
 0.6211016121364775)
```

To evaluate the volumetric segmentation accuracy, the dice coefficient (DC) was used for bone and cartilage, Dice Coefficient is 2 * the Area of Overlap divided by the total number of pixels in both images and it is defined as:

$$DC = \frac{2\,|S \cap R|}{|S| + |R|}$$

Here S and R represent the U-Net segmentation and the manual segmentation ground truth, respectively.
The DC ranges between 0 and 1 with a value of 1 indicating a perfect segmentation and a value of 0 indicating no overlap at all.

The model was tested on the test dataset. It yielded dice scores of 0.678, 0.773, and 0.593 for Femur, Patella and Tibia respectively.

1V. DISCUSSION

The main aim of the existing study is to discover the performance achieved using U-net to improve and estimate the robustness of the convolutional neural network for programmed automatic segmentation of the knee bone from MRIs. The U-net methodology is well-matched for executing prompt and precise segmentation of the bone and the cartilages present in the knee. This segmentation based on deep learning methods has promising prospective claims in biomedical imaging.

Segmentation was the most time-consuming stage where the two bones (femur and tibia) and the cartilages (femoral, tibial and patella) were cautiously segmented using the U-Net method. Using the pre-trained volume, one can likely relate transmission with a marginal effort to resolve related complications. Exploration must be done more systematically on how the segmentation work can be used on growth-related approximations to increase the outcomes more. Supplementary data about the patient′s height and weight may benefit to increase accuracy in the forthcoming.

We propose the usage of deep learning techniques to computerize the segmentation of knee bone and cartilages [4]. The age can be determined by the Growth plate′s existent in knee bone. Age assessment is one of the objectives accomplished using segmented knee bone MRIs.

The automatic segmentation technique will increase the accuracy and decreases time effort for segmentation of knee bones and cartilage technique [1]. The automatic segmentation of bones, coronal view MRI is used and for cartilage segmentation sagittal view MRI is used. Training these MRI was consuming more time. This project consumed about 60% of the dataset for training and the 40% for validation. The MR Images are in (Meta-Image Header) MHD file format which is used for medical imaging analysis. Training MR Images using deep neural network is time consuming.

V. CONCLUSION

This paper presented the development of a fully automated workflow based on convolutional neural networks, which segments bones and cartilages in MRI data of human knees. It shows an excellent performance of 98% Dice similarity coefficient (DSC) while distinguishing between Femur, Tibia, and Fibula. It is robust against noise and adaptable to changes in resolution due to its fully convolutional structure. This also helps to visualize all of the layers in the network. Furthermore, it was possible to combine the segmentation with part of the architecture as a pre-trained model to assess the age of candidates with a mean difference of 0.48 years ± 0.32.

VI. REFERENCES

[1] Felix Ambellan,″ Automated segmentation of knee bone & cartilage combining statistical shape knowledge & CNN: Data from the Osteoarthritis Initiative″, IEEE 2019
[2] Zhaoye Zhou, ″Deep convolutional neural network for segmentation of knee joint anatomy″, HHS 2019
[3] Alejandra Duarte, ″Knee Cartilage Segmentation Using Diffusion-Weighted MRI″, IEEE 2019
[4] Ian Carvalho, ″Cartilage Segmentation for Knee MRI images″, IEEE 2019
[5] Arjun D Desai, Garry E. Gold, Brian A. Hargreaves, ″Technical Considerations for Semantic Segmentation in MRI using Convolutional Neural Networks ″, IEEE, 2019
[6] Alexander Tack,Alejandra Duarte, ″accurate automated volumetry of cartilage of the knikoee using convolutional neural networks: data from the osteoarthritis initiative**″,** IEEE, 2019
[7] Fang Liu, ″SUSAN: Segment Unannotated image Structure using Adversarial Network″, IEEE 2018
[8] Felix Ambellan, ″Automated segmentation of knee bone and cartilage combining SSK & CNN″, IEEE 2018
[9] Berk Norman, ″Use of 2D U-Net convolutional Neural Networks for Automated Cartilage Segmentation of Knee MR Imaging Data″, RSNA , 2018
[10] Anita Thengade1, Dr. Archana Rajurkar, ″ A Comprehensive Survey of Articular Cartilage Segmentation Methods on Knee MRI ″, IEEE 2018

[11] Zhou Z, Zhao G, Kijowski R, Liu F. Deep Convolutional Neural Network for Segmentation of Knee Joint Anatomy. Magn. Reson. Med. 2018

[12] Houda Bakir, "Automatic Knee Cartilage Segmentation and Visualization", IEEE 2018

[13] Archit Raj, "Automatic knee cartilage segmentation using fully volumetric convolutional neural networks for evaluation of osteoarthritis", Research gate, 2018

[14] Fang Liu, "Deep Convolutional Neural Network and 3D Deformable Approach for Tissue Segmentation in Musculoskeletal Magnetic Resonance Imaging", IEEE 2018

[15] Boyu Zhang, "3D U-net with Multi-level Deep Supervision: Fully automatic segmentation of Proximal Femur in 3D MR Images", IEEE 2018

[16] Kijouski, "Deep Convolutional Neural Network for Segmentation of Knee Joint Anatomy", Pubmed 2018

[17] Andrew T. Pennock, "Bone Age Assessment Utilizing Knee MRI", Orthop J Sports Med 2017

[18] Paul Louis, "Automated Segmentation of Bones for the Age Assessment in 3D MR Images using Convolutional Neural Networks", IEEE 2017

[19] Andrea Aprovitola, "Knee bone segmentation from MRI", Elsevier 2017

[20] Heiko Seim, "Model-based Auto-Segmentation of Knee Bones and Cartilage in MRI Data", RSNA 2017

[21] Boyu Zhang, "Computer-Aided Knee Joint Magnetic Resonance Image Segmentation - A Survey", Elsevier 2017

[22] Chaitra V Hegde "Automatic Knee Cartilage Segmentation", 2018

[23] Chunsoo Ahn, "Fully automated, level set-based segmentation for knee MRIs using an adaptive force function and template: data from the osteoarthritis initiative", PMC 2019

[24] William Burton II, "Semi-supervised learning for automatic segmentation of the knee from MRI with convolutional neural networks", Elsevier 2020

[25] Manoj Singh," Segmentation of cartilage from knee MRI images using the watershed algorithm",IJARIIT, 2018

[26] Dileep Kumar, "Knee Articular Cartilage Segmentation from MR Images", ACM 2018