



# A CASE OF PAIN ON THE LEFT LATERAL ORBITAL REGION

1 DR. VENKATESH.V. KULKARNI, 2 DR. PRAVEENA.V. KULKARNI

1 Professor, 2 Assistant Professor

1Department of Oral and Maxillofacial Pathology & Microbiology,  
Bharati Vidyapeeth (Deemed to be University) Dental College & Hospital, Pune. India.

**Abstract** - Pigmented basal cell carcinoma is an uncommon clinical presentation that can resemble a melanoma. While other subtypes of basal cell carcinoma (BCC) primarily affect individuals with light eyes and hair, fair complexion, and an inability to tan, pigmented BCC has a predilection for darker-skinned populations with dark brown eyes.<sup>1-3</sup>

**Keywords:** Pigmented basal cell carcinoma, non-melanoma cancer, Ultraviolet radiation

## INTRODUCTION

Basal cell carcinoma is the most common malignant tumour of skin, comprising 80% of non-melanoma cancers. It primarily occurs on sun-exposed areas of the body, such as the face, neck, scalp, ears, and hands. Intermittent exposure to ultraviolet radiation is an important risk factor. Pigmented basal cell carcinoma is a clinical and histological variant of basal cell carcinoma that exhibits increased pigmentation. It is a very rare variant, although its frequency can reach upto 6% of total basal cell carcinomas in Hispanics.<sup>4</sup>

## CASE REPORT

A 64-year-old male patient reported with a chief complaint of slight pain and itching near the left outer canthus of eye since last one year. Patient was apparently alright one year back when he noticed blackish lesion near the outer canthus of eye. The lesion was initially small in size and grew to the present size over a period of one year. No history of skin lesions elsewhere.

On examination, bluish black colored crusted lesion with rough surface and irregular borders measuring 2 x 2 cm in size was noted near left outer canthus of eye (figure 1). It was extending 2cm posterior to outer canthus of eye and 2 cm anterior to outer canthus of left eye involving one third lateral part of upper and lower eyelid. Scarring and crusting was seen on the lesion. On palpation lesion was non-tender with an indurated base. No ocular abnormalities were present. There was no lymphadenopathy. Patient was advised biopsy.

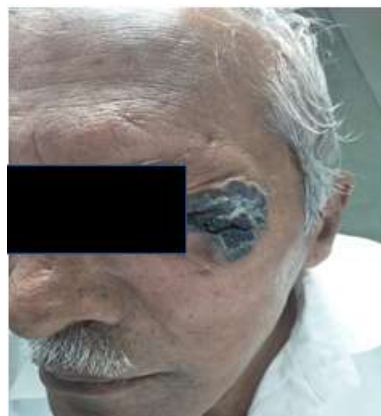

figure 1: single blackish elevated lesion near outer canthus of eye

Gross Pathology: single tissue specimen measuring about (1.8x0.5) cm in dimension, dark brown in color, firm in consistency with rough surface and irregular borders (figure 2).

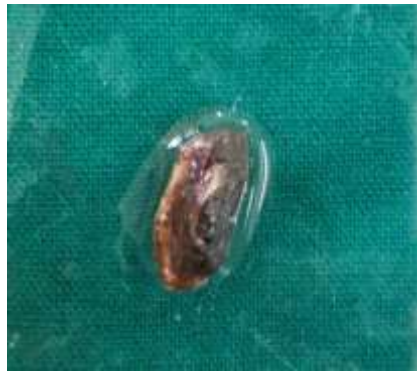

figure 2: tissue specimen

## HISTOPATHOLOGICAL EXAMINATION

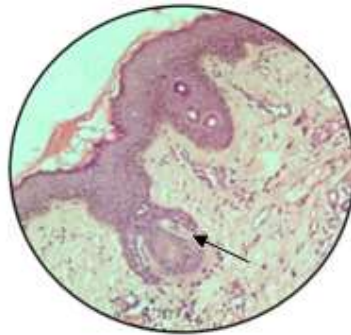


figure 3: artifactual retraction (Black arrow) (10X)

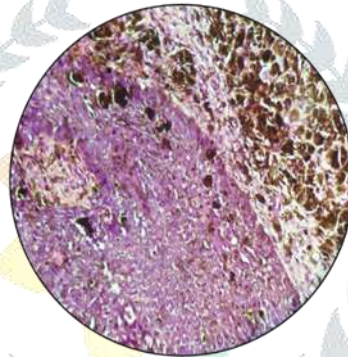


figure 4: Abundant melanin pigmentation (40X)

Basaloid cells showed intensely basophilic (blue-staining), large, relatively uniform nuclei, and scant cytoplasm resembling the basal keratinocytes of normal epidermis. Artifactual retraction of the stroma around tumor islands created microscopically visible clefts (figure 3). Abundant melanin pigmentation was also seen (figure 4). Differential diagnoses were malignant melanoma and basal cell carcinoma. To rule out Malignant melanoma HMB45 was done and which came to be negative (figure 5).




figure 5: HMB45-immunohistochemical staining- negative (10X)

**FINAL DIAGNOSIS - Pigmented Basal Cell Carcinoma**

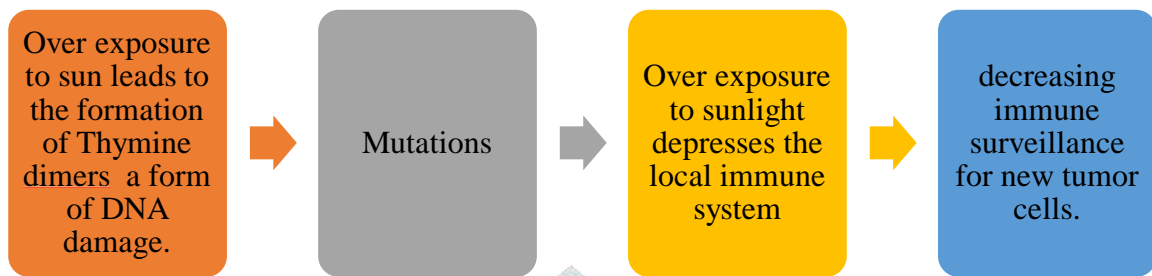
## DISCUSSION

Basal cell carcinoma (BCC), also known as basal cell epithelioma or rodent ulcer, is the most common type of skin cancer. Rodent ulcer is an old term for what is now called nodular basal cell carcinoma, a form

of skin cancer. The name, rodent ulcer, was used because of the tendency of this type of basal cell carcinoma to form an ulcer or sore on the skin with ragged edges.

Exposure to sunlight is a major risk factor for the development of basal cell carcinoma. Other risk factors include a fair complexion, a history of intense sun exposure or sunburns, a family history of skin cancer, and a weakened immune system.

How UV light causes carcinoma <sup>5,6</sup>



Basal cell carcinoma is more common in middle-aged or elderly individuals, typically occurring in people over 40 years of age. The gender distribution is slightly higher in males, with a male-to-female ratio of about 3:2. Approximately 80 percent of all cases of basal cell carcinoma are found on the head and neck region, including the face. This is because these areas are more frequently exposed to sunlight.

#### HISTOPATHOLOGY-

Basal-cell carcinomas may be divided into the following types:

- Nodular basal-cell carcinoma
- Cystic basal-cell carcinoma
- Morpheaform basal-cell carcinoma
- Infiltrative basal-cell carcinoma
- Micronodular basal-cell carcinoma
- Superficial basal-cell carcinoma
- Pigmented basal-cell carcinoma

Current theory is that basosquamous carcinoma is a rare variant of basal cell carcinoma with areas of differentiation into squamous cell carcinoma. This is supported by presence of transition zone- area of intermediate transition of atypia. BCC is admixed with an independent primary SCC of the skin. The resulting collision tumor is called basosquamous carcinoma. The diagnosis of basosquamous carcinoma is important because of the increased likelihood of local recurrence and increased risk of metastasis <sup>7</sup>

There are other rare clinical types of BCC.

- Wild-fire type BCC
- Giant pore BCC
- Angiomatous BCC
- Lipoma-like BCC

#### CONDITIONS ASSOCIATED WITH BCC

- Nevoid Basal Cell Carcinoma Syndrome
- Xeroderma Pigmentosum
- Bazex Syndrome

It's important to note that while basal cell carcinoma is the most common type of skin cancer, it is also the least aggressive and rarely metastasise. Metastatic rate is <0.1%, and reported sites of metastasis are skeletal and pulmonary. If these tumors left untreated, they can cause extensive tissue destruction, disfigurement, infiltration into cartilage, muscle or bone with even intracranial extension.

#### CONCLUSION

It is very important to pay attention on the diagnosis and treatment of BCC to prevent local tissue destruction and disfigurement.

## REFERENCES

1. Bart RS, Schnall S. Eye color in darkly pigmented basal-cell carcinomas and malignant melanomas: an aid in their clinical differentiation. *Arch Dermatol.* 1973;107(2):206-207.
2. Bigler C, Feldman J, Hall E, Padilla RS. Pigmented basal cell carcinoma in Hispanics. *J Am Acad Dermatol.* 1996;34(5, pt 1):751-752.
3. Gellin GA, Kopf AW, Garfinkel L. Basal cell epithelioma: a controlled study of associated factors. *Arch Dermatol.* 1965; 91:38-45.
4. Deepadarshan K. Mallikarjun M. and Noshin N. Abdu Pigmented Basal Cell Carcinoma: A Clinical Variant, Report of Two Cases. *J Clin Diagn Res.* 2013 Dec; 7(12): 3010–3011
5. Review Article Focus on Basal Cell Carcinoma Venura Samarasinghe *Journal of Skin Cancer* Volume 2011, Article ID 328615, 5 pages
6. Review-Molecular Pathogenesis of BCC-British Journal of Dermatology,2005,152.
7. Head and Neck Pathology Basosquamous Cell Cancer Hoyne, Draxl, Heather T Jun 13, 2013
8. Basosquamous Carcinoma of the Neck Philippine Journal Of Otolaryngology-Head And Neck Surgery Vol. 26 No. 1 January – June 2011

