JETIR.ORG ISSN: 2349-5162 | ESTD Year : 2014 | Monthly Issue
JOURNAL OF EMERGING TECHNOLOGIES AND INNOVATIVE RESEARCH (JETIR)
An International Scholarly Open Access, Peer-reviewed, Refereed Journal

First Trimester Ultrasound Detection of Osteogenesis Imperfecta: Prenatal ultrasound clues discussed with a case report

Shankar Dey [1*] ,Prasanna Roy [1]

[1] Ultra Clinic, Fetal Medicine & Fertility Centre, Asansol-713304, West Bengal, India

Abstract: Osteogenesis Imperfecta (OI) is a rare genetic disorder characterized by brittle bones and skeletal deformities. Prenatal diagnosis of OI can be challenging, and early detection is crucial for appropriate counseling and management.High index of suspicion is necessary for the early detection of this rare skeletal deformity. Ultrasound scan of the fetus during the first trimester can detect the abnormality when done in a appropriate setting and recommended protocol.This case report presents the first trimester ultrasound detection of OI, describing the prenatal ultrasound features, subsequent post-abortal findings matched with the ultrasound imaging and confirmatory genetic testing results.

Keywords: Osteogenesis imperfecta, first trimester ultrasound, prenatal diagnosis, genetic disorder, skeletal deformities

Introduction: Osteogenesis Imperfecta (OI), also known as brittle bone disease, is a rare hereditary disorder affecting collagen synthesis, leading to skeletal fragility and deformities [1] . Incidence of OI is reported to be one in 20000 people and have four major types[2] .Prenatal detection of OI is vital for parental counseling, facilitating informed decisions regarding continuation or termination of pregnancy, and guiding management strategies[2] . This case report describes the first trimester ultrasound detection of OI and presents the prenatal ultrasound features observed, followed by post-abortal findings.Genetic testing was done from the abortus and OI Type III confirmed.

Case Report: A 29-year-old primigravida presented for routine first trimester screening at 12 weeks 2 days of gestation.She was planned for a Nuchal translucency scan and double marker serum screening as per protocol of Down Syndrome screening in first trimester.The couple had no known family history of any skeletal abnormalities.Transabdominal and transvaginal ultrasound examination revealed some skeletal abnormalities in the fetus. Actually the only relevant and significant finding was very small right tibia and fibula along with a fractured appearance of the right leg.No other ultrasound abnormalities were detected in the fetus.The ultrasound in different modes like 2D, 4D VCI and 3D surface rendering were used to identify and clarify the abnormal appearance of the right leg. The ultrasound findings were consistent with OI type II or type III which are severe forms of the disorder associated with a poor prognosis [3]

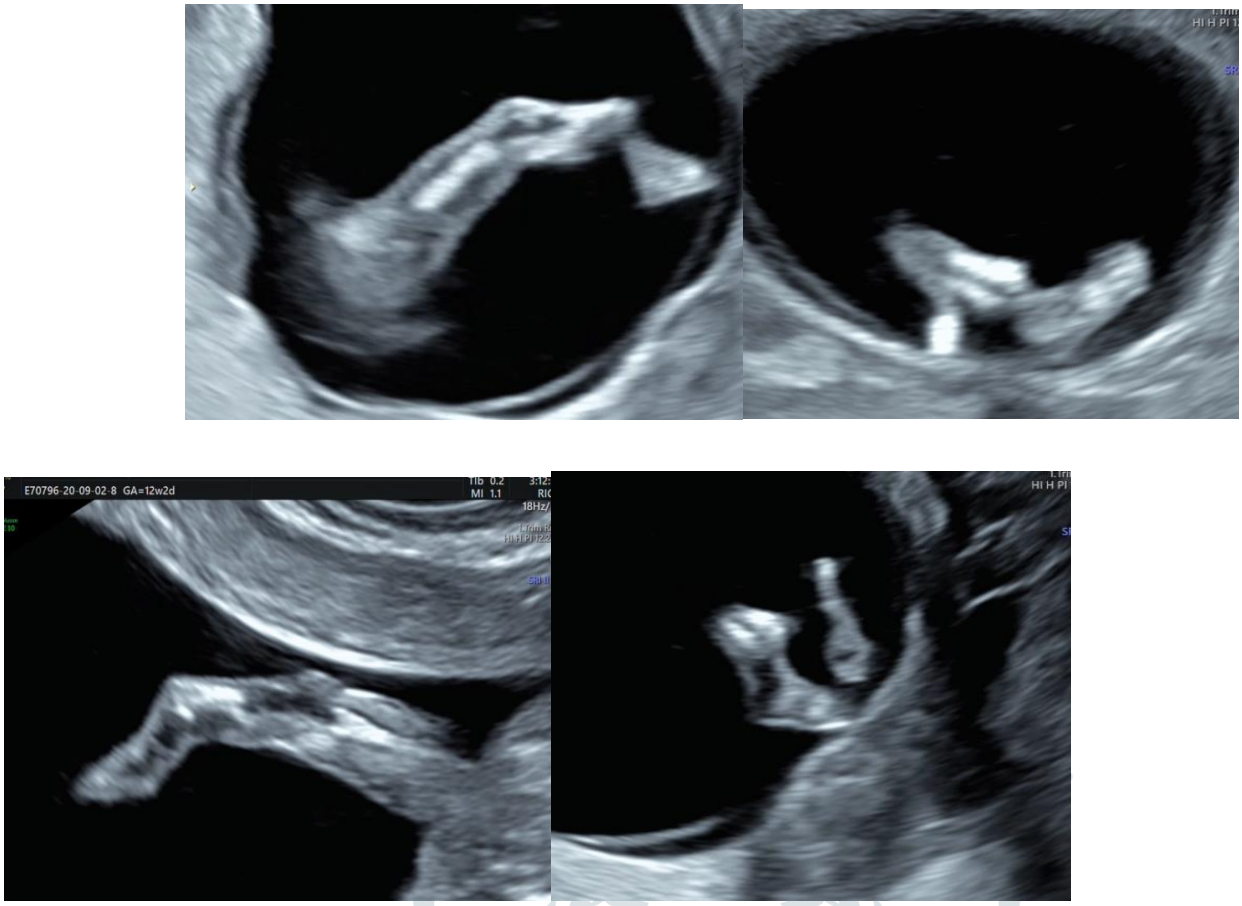

Figure 1(a,b,c,d). 2D Ultrasoud images showing fetal right leg with fractured appearance at its distal end, short tibia and fibula and hanging foot

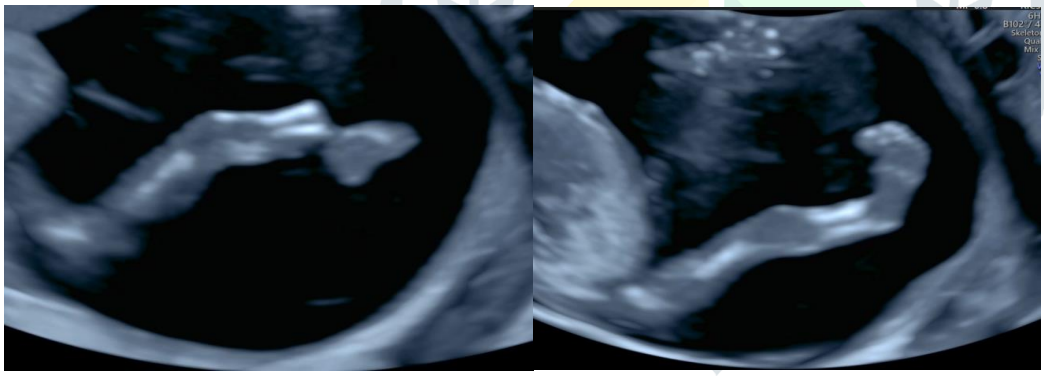

Figure 2 a 4D VCI skeletal mode ultrasound showing the fractured appearance of right leg with short tibia -fibula and hanging foot .Figure 2b showing the normal left leg in comparison.

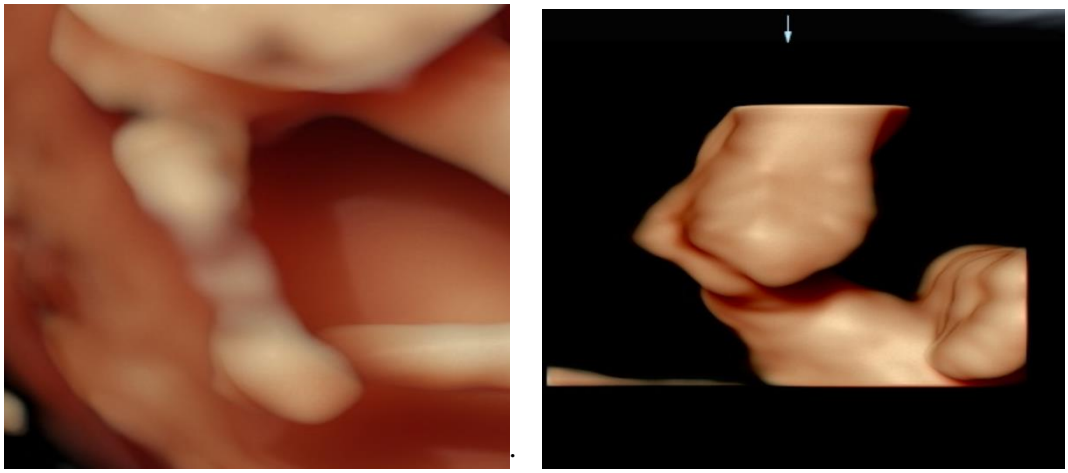

Figure 3. 3D ultrasound surface rendering mode showing the abnormal appearance of right leg (a) ; enlarged view at the fracture site (b)

Following thorough discussion and genetic counseling, the couple decided to terminate the pregnancy due to the anticipated poor outcome and associated complications. The procedure was performed at 12 weeks of gestation after taking informed consent . Post-abortal examination of the fetus confirmed the ultrasound findings, revealing the long bone fracture of its right leg Figure 2).

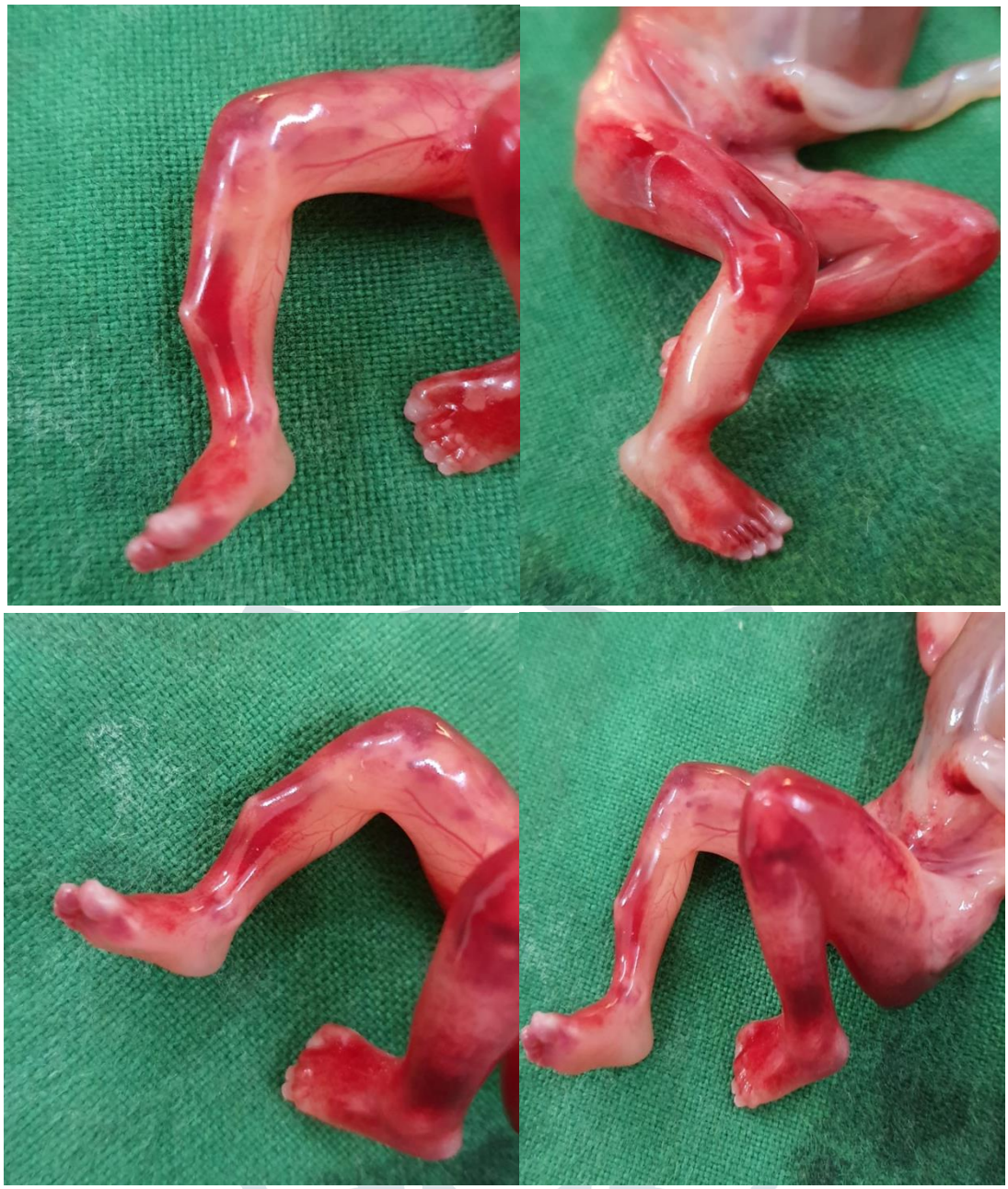

Figure 4 (a,b,c,d) Photographs of abortus showing the abnormality of right leg from different view angles

Samples sent to the laboratory for the genetic testing (clinical exome sequencing) and the report came out later as gene mutation consistent with the diagnosis of OI typeIII (Figure 5)

RESULT SUMMARY

Likely pathogenic variant causative of the reported phenotype was identified
*Correlation with clinical profile and family history is required

FINDINGS RELATED TO PHENOTYPE

Gene & Transcript	Variant	Location	Zygosity	Disorder (OMIM)	Inheritance	Classification
COL1A1 NM_000088.3	c.975_976delTG (p.Asp325Glufs*27)	Exon 15	Heterozygous	Osteogenesis Imperfecta, Type Iii (259420)	Autosomal Dominant	Likely Pathogenic

VARIANT INTERPRETATIONS

COL1A1 chr17:48273542_48273543delCA - Likely Pathogenic.
A heterozygous two-base pair deletion in exon 15 of the *COL1A1* gene (c.975_976delTG) that results in a frameshift and premature truncation of the protein 27 amino acids downstream to codon 325 (p.Asp325GlufsTer27) was detected. This frameshift variant is not reported in both the 1000 genomes and gnomAD databases. This variant is predicted to be damaging by Mutation taster. This variant is predicted to cause loss of normal protein function through protein truncation caused a frameshift mutation. The gene *COL1A1* has a low rate of benign loss of function variants as indicated by a high LoF variants Z-Score of 7.92. The observed variant is a loss of function variant in the gene *COL1A1*, which is intolerant of Loss of Function variants, as indicated by the presence of existing pathogenic loss of function variant NP_000079.2:p.Met1Val and 221 others. There are 139 downstream pathogenic loss of function variants, with the furthest variant being 1120 residues downstream of the variant p.Asp325GlufsTer27. **Based on the above evidence this variant has been classified as likely pathogenic according to the ACMG guidelines.**

Osteogenesis type III (OI3) is caused by heterozygous mutation in one of the genes for type I collagen, *COL1A1* or *COL1A2* .OI3 is characterized by low bone mass, bone fragility and susceptibility to fractures after minimal trauma. Disease severity ranges from very mild forms without fractures to intrauterine fractures.

Figure 4 : The CES report showing the mutation of COL1A1 gene related to OI typeIII

Discussion: Prenatal ultrasound plays a crucial role in the early detection and diagnosis of OI.The prenatal ultrasound findings of OI may present as shortened and curved femurs, humeri, or other long bones in the fetus; decreased bone density and mineralization resulting in a hypoechoic appearance of the affected bones;the presence of fractures as interruptions or irregularities in the bone structure; Additional small bones, known as Wormian bones, seen within the cranial sutures due to disrupted bone formation [4] .Some other features like polyhydramnios may be present due to reduced fetal swallowing caused by skeletal abnormalities, particularly involving the ribs and the fetus with OI may exhibit excessive joint mobility and increased flexibility.Nonspecific features like thickened placenta with calcifications may also be observed. In this case,the only ultrasound findings was fractured appearance of fetal right leg leading to a possible diagnosis of OI, prompting proper counseling and subsequent termination of the pregnancy.Importantly these sonographic findings may vary depending on the severity and type of OI.Presence of multiple abnormalities, such as shortened and bowed long bones, reduced mineralization, fractures, abnormal fetal movements, and polyhydramnios, should raise suspicion for OI.First trimester ultrasound detection of OI can present a diagnostic challenge due to the limited resolution of early gestational ultrasound and the subtle skeletal changes in the fetus. However, advanced imaging techniques, such as three-dimensional ultrasound and high-resolution magnetic resonance imaging (MRI), can aid in the accurate diagnosis and classification of OI[5] .

Genetic testing through chorionic villus sampling or amniocentesis , is essential for confirming the diagnosis and the specific type of OI, specifically where the ultrasound findings are not so obvious and couple wants to continue the pregnancy, as different types of OI have distinct clinical presentations and prognoses [6].In our case the final diagnosis is Type III OI which is very rare and severe , characterized by multiple fractures, craniofacial deformities, and undermineralization[7].However we got only unilateral fetal leg fracture appearance on ultrasound and confirmed in abortus. This unique and peculiar presentation of OI type III is the aim this case report.

Conclusion: Early detection of OI through first trimester ultrasound is crucial for appropriate counseling and management. Prenatal ultrasound features, such as shortened and bowed long bones, decreased echogenicity, irregular bone margins, and the beaded appearance of ribs, can raise suspicion of OI. Genetic testing and post-abortal examination further confirm the diagnosis and provide insights into the specific type and severity of OI. Improved imaging techniques and genetic analysis continue to enhance the accuracy of prenatal diagnosis, enabling informed decision-making for affected families.

References:

1. Sillence DO, Senn A, Danks DM (2019). Genetic heterogeneity in osteogenesis imperfecta. J Med Genet, 56(2), 73-80. doi:10.1136/jmedgenet-2018-105796
2. Lindahl K, Symoens S, Giunta C, et al. (2021). Clinical and molecular update on osteogenesis imperfecta. Mol Genet Genomic Med, 9(6), e1747. doi:10.1002/mgg3.1747
3. Van Dijk FS, Pals G, Van Rijn RR, et al. (2020). Classification of Osteogenesis Imperfecta revisited. Eur J Med Genet, 63(5), 103791. doi:10.1016/j.ejmg.2020.103791
4. Savarirayan R, Bompadre V, Bober MB, et al. (2018). Clinical practice guidelines for the management of osteogenesis imperfecta: the 2018 update. Osteoporos Int, 29(6), 1383-1395. doi:10.1007/s00198-018-4534-y
5. Ngo TH, Zhang X, Das S (2022). Prenatal Diagnosis of Osteogenesis Imperfecta: A Case Report and Review of the Literature. Case Rep Radiol, 2022, 1122063. doi:10.1155/2022/1122063
6. Cho SY, Lee KE, Park HD, et al. (2021). Prenatal Diagnosis of Osteogenesis Imperfecta in the Era of Next-Generation Sequencing. Genes (Basel), 12(5), 647. doi:10.3390/genes12050647
7. Nishimura G, Ito T, Shirota C, et al. (2020). Diagnostic pathway for patients with developmental skeletal abnormalities: clinical experience in Japan. Pediatr Radiol, 50(3), 364-373. doi:10.1007/s00247-019-04630-y