JETIR.ORG ISSN: 2349-5162 | ESTD Year : 2014 | Monthly Issue
JOURNAL OF EMERGING TECHNOLOGIES AND INNOVATIVE RESEARCH (JETIR)
An International Scholarly Open Access, Peer-reviewed, Refereed Journal

# "A COMPREHENSIVE CADAVERIC STUDY ON *SUSHRUTOKTA AVEDHYA SIRA* OF *SHRONI* WITH SPECIAL REFERENCE TO ITS REGIONAL AND SURGICAL ANATOMY"

**[1]Dr Nanda V Kuri, [2]Dr Mamata Murthy, [3]Dr Shruti Hegde**

[1]Final year PG Scholar, [2]Professor and HOD Department of Rachana Shareera
[3]Assistant Professor Department of Rachana Shareera
[1] Department of Rachana Shareera,
[1]Government Ayurveda Medical College, Dhanvantari Road Bengaluru, India

## ABSTRACT

### Background

*Sira shareera* occupies a significant place in Ayurvedic Rachana Shareera and forms the foundation for procedures such as *siravyadha karma*. Acharya Sushruta described 700 *sira*, among which 98 are categorized as *avedhya sira*, vessels that should not be punctured due to the risk of serious complications. Among the *koshtagata avedhya sira*, eight are situated in the *shroni pradesh*, comprising four *Vitapa* and four *Kateekataruna siras*.

### Objectives

To identify and study the probable anatomical counterparts of *Shronigata avedhya siras (Vitapa and Kateekataruna)*, understand their regional and surgical anatomy, and evaluate the rationale behind their classification as *avedhya sira*.

### Materials and Methods

A cadaveric observational study was conducted in the Department of *Rachana Shareera*, Government Ayurveda Medical College, Bengaluru. Two formalin-fixed cadavers were dissected. The regions corresponding to *vitapa* and *kateekataruna* were explored, and the vascular and related anatomical structures were identified, documented, and analysed.

### Results

In the *vitapa* region, the superficial external pudendal vein, superficial epigastric vein, and superficial circumflex iliac vein were identified draining into the great saphenous vein. In the *kateekataruna* region, superior and inferior gluteal vessels were observed deep to the gluteus maximus muscle in relation to the piriformis muscle. These vessels showed close association with adjacent nerves, arteries, and important anatomical structures.

### Conclusion

The vessels identified in the *vitapa* and *kateekataruna* regions possess characteristics such as proximity to vital neurovascular structures, deep anatomical location, variable calibre, and close association with arteries and lymphatics. These findings support their classification as *avedhya sira* and justify the classical prohibition of *siravyadha* in these regions.

**Keywords:** *Avedhya Sira, Siravyadha, Shroni, Vitapa, Kateekataruna,* Surgical Anatomy, Cadaveric Study

## INTRODUCTION

Anatomy is the foundation of medical science and plays a pivotal role in both traditional and contemporary healthcare systems. Among the anatomical concepts described in Ayurveda, *Sira shareera* occupies a unique position due to its direct relevance in diagnostic and therapeutic procedures. Acharya Sushruta described 700 *sira* distributed throughout the body and classified them based on location, function, and dosha predominance. Among these, 98 are categorized as *avedhya sira*, vessels that should not be punctured during *siravyadha* because injury may result in *vaikalya* or even *marana*.

Among the 32 *Koshtagata avedhya sira*, eight are located in *Shroni pradesh*, consisting of four *vitapa* and four *kateekataruna siras*. Since these regions are closely associated with *marma sthana* and contain important neurovascular structures, understanding their anatomical basis is essential. The present cadaveric study was undertaken to correlate classical descriptions with contemporary anatomical findings and to explore the surgical significance of these structures.

## SHRONI

Nirukti

Shabdha kalpa druma [1]

श्रोण - ऋ संघाते। ऋ - अशु श्रोणात्। संघातो – राशीकरणम्

Amarakosha[2]

कटिः। इत्यमरः

Paryaya - कटिः, श्रोणी, ककुद्मती

**Extent of shroni** [3]

श्रोणिरत्रोरुसन्धेरधस्तात् स्मरमन्दिरोपरितनविभागः| (Su.Su.35/12)

ऊरु- जानूपरिभागः, सक्थि (AMK)[4] – Part above the knee

सन्धि - अस्थिद्वय संयोगस्थान (*Vachaspatya)*[5]-where two bones meet

ऊरु -the thigh[6]

स्मर- स्मरयति उत्कण्ठयतीति|[7] - that which creates desire or passion

कामदेवः । इत्यमरः[8] - *Kamadeva* ( the god of love or desires )

मन्दिर – मन्द्यते सुप्यतेऽत्र मन्द्यते स्तूयते इति वा |[9] a place where one rests, sleeps, or is worshipped. गृहम् । इत्यमरः □ [10] - house ,abode or temple

स्मर मन्दिर- स्मरस्य मन्दिरं योनिः।[11](Hemachandra ) it's the synonym of *yoni*.

Thus, the *shroni* is the part which lies below the *urusandhi and* above the *smaramandira.*

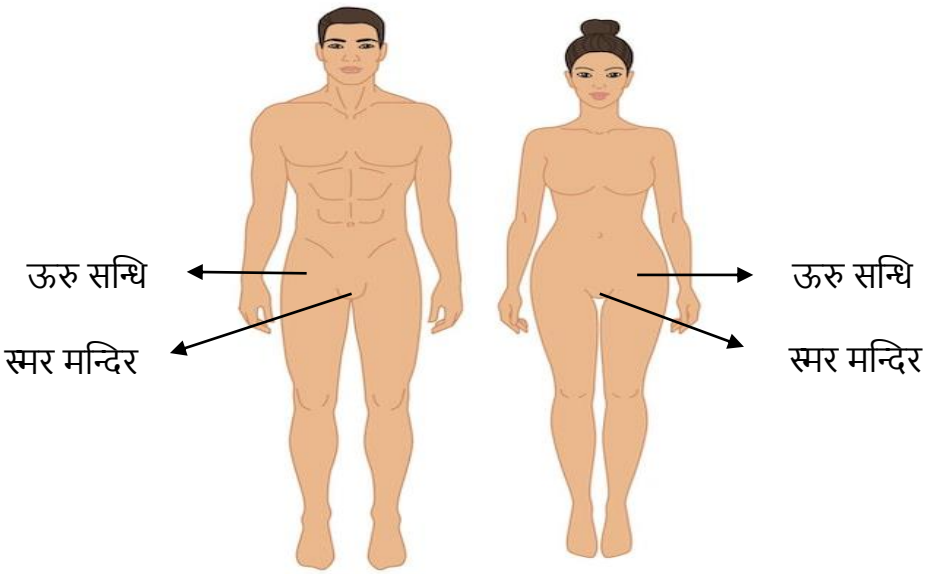

***VITAPA SIRA***

**Shabdhakalpadruma [12]**

Nirukti - वेटति शब्दायते इति ।

Meaning - That which produces sound / rustling sound or sound made by branches of leaves and tree.

**Amarakosha [13]**

- वृक्षविस्तारः
- *Vitapa – Pullinga or Napunsaka linga*
- *Samanarthaka – Vistara,Vitapa*

**Aptes dictionary [14]**

- The branch of a tree or creeper with its new sprout or shoot.
- The septum of the scrotum.

**Monier williams dictionary [15]**

- The perineum

*Vitapa* is also mentioned under the *sakti marma (adhoshakhagata marma)* by acharya Sushruta and Vagbhata.

***Sthana* of *vitapa marma***

- वङ्क्षणवृषणयोरन्तरे विटपं |[16] ( Su.Sha 6/24)
- मुष्कवङ्क्षणयोर्मध्ये विटपं षण्ढताकरम्|[17] (Ah.Sha.4/8 )

*Vankshana - Uru sandhi*[18]

*Vrushana – Anda kosha*[19]

*Antara – Madhya or avakasha* [20]

*Vitapa marma* is located in the region between the *vankshana* and *vrushana*

*Viddha lakshana* - तत्र षाण्ढ्यमल्पशुक्रता वा भवति;[21] (Su. Sha 8/22)

*Vitapa marma* is situated in between *vrushana* and *vankshana*. *Mushka* and *Vrishana* is the scrotal sac enclosing the male gonad i.e. testis. In case of female the homologous organ for the scrotum is labia majora. As per contemporary science the surface marking and location of particular organ are on the basis of the surface land marks in the body that may be bony structure or muscular boundaries with respect to the skin surface. The scrotum is attached to root of penis which is at the level of the inferior part of pubic symphysis. At the root of penis, a point which indicates the beginning of median raphe of the scrotum can be taken for the land mark of *Vrushana,* in case of female this point will be the midpoint between upper parts of two labia majora near the clitoris. [22]

*Vankshana* is *adhoshakagata sandhi*. It is *chala* type of *ulukhala sandhi*. This is the hip joint in contemporary science. The landmark given for the hip joint is the mid inguinal point. At this point the pulsation of the femoral artery can be felt against head of femur in living being. Head of the femur articulates with the acetabulum of the hip bone to form hip joint. Head of the femur lies at the level of mid inguinal point which gives the idea of hip joint.[23]

By considering all above explanation the location of the *vitapa marma* can be taken as midway between the mid inguinal point and lower part of pubic symphysis in the groin region.

***KATEEKATARUNA SIRA***

- There are 4 *kateekataruna sira* in *shroni pradesha* which are *avedhya.*
- *Kateekataruna* is also mentioned under *prushta marma* by Acharya Sushruta and Vagbhata.

➢ **कटि**

*Shabdhakalpadruma*[24]

कट्यते आव्रियते वस्त्रादिना|- area around which the cloths are tied.

कटात् श्रोणिवचन इति गौरादिषु पाठाद्

श्रोणिदेशः । इति मेदिनी ॥

*Vachaspati*-श्रोणिदेशे

*Amarakosha*[25] -कटः, श्रोणिफलकं, श्रोणी, ककुद्मती

*Apte*[26] - the hip, the buttock

- **तरुण**

*Shabdhakalpadruma* [27]

तरति प्लवते प्रमोदसलिले इति ।- That which floats or swims in the waters of joy

Amarakosha [28]- युवा

Apte[29] – young, youth full or juvenile.

Monier Williams[30] – juvenile

***Sthana* of *kateekataruna marma***

तत्र पृष्ठवंशमुभयतः प्रतिश्रोणिकाण्डमस्थिनी कटीकतरुणे[31]| (Su Sha)

पृष्ठं- शरीरपश्चाद्भागः ( AMK) The back (MW)

वंशः- पृष्ठावयव (SKD) The spine (MW)

प्रतिश्रोणिकाण्डमित्यत्र 'प्रतिश्रोणिकर्णौ' इति केचित् पठन्ति|

तत्र श्रोणिकर्णौ लक्षीकृत्य त्रिकसन्निधाने श्रोण्यामुपरि [32](Dalhana)

प्रति- against or in opposition to

श्रोणि- कटि (AMK) the hip and loins (MW)

कर्ण- The ear (MW)

त्रिक- पृष्ठवंशाधोभागः (AMK) Lower part of spine(apte) त्रयाणां सङ्घः

सन्निधानम्- निकटम् (SKD)

*Kateekatarunamarma* is situated in lower back, one on either side of vertebral column near bones of the pelvis. *Kateekatarunamarma* is an *asthimarma* so *asthi* are dominant structure in this area mainly Posterior aspect of ilium bone, sciatic notch, sacro-iliac joint. The word *Pratishronikandam* is referred to as *Pratishronikarnou* by Acharya Dalhana. This *Shronikarnou* is present on either side above the *trika* (Sacrum) bone attached to the pelvis. The structure that which resembles the ear in the pelvis is supposed to be auricular surfaces of the both the Ilium & Sacrum bone together forming the sacro-iliac joint. This joint has a peculiarity in the way the cartilages are attached to the articular surfaces of the Ilium & Sacrum bones, which can be understood from the following statement of Gray's anatomy, which reads as "The sacroiliac articulation is an amphiarthrodial joint, formed between the auricular surfaces of the sacrum and the ilium. The articular surface of each bone is covered with a thin plate of cartilage, thicker on the sacrum than on the ilium. These cartilaginous plates are in close contact with each other, and to a certain extent are united together by irregular patches of softer fibro cartilage, and at their upper and posterior part by fine interosseous fiber. Hence, the *taruna* predominance in this particular joint present at the *Kateeka* region, helps in determining the sacroiliac joint to be considered as the *Kateekataruna marma*. Acharya Sushruta opines injury to this *marma* exhibits death from blood loss and loss of complexion and patient become very debilitated. External trauma to this area causes pelvic fracture and fractured bone can damage surrounding blood vessels i.e. External iliac and internal iliac arteries, corresponding iliac veins thus causing pelvic haemorrhage which leads to blood loss.[33]

By considering all above explanations the *sthana* of *kateekataruna marma* can be taken as the point on either side of the *prushtavamsha* in the direction of the *shroni karna* (auricular surface of sacrum and ilium)

***Viddha lakshana***

तत्र शोणितक्षयात् पाण्डुर्विवर्णो हीनरूपश्च म्रियते|[34]

Injury to the *kateekataruna marma* leads to the *pandu*(anemia) due to the *shonita kshaya* (blood loss) & *marana* (death).

**Materials and Methods**

This observational cadaveric study was carried out in the Department of Rachana Shareera, Government Ayurveda Medical College, Bengaluru. Two formalin-fixed cadavers were selected for dissection.

The study involved:

1. Identification of probable sites of *Vitapa* and *Kateekataruna siras* using classical references.
2. Layer-wise dissection of inguinal and gluteal regions.
3. Identification of vascular and associated anatomical structures.
4. Documentation of observations.
5. Correlation of findings with Ayurvedic literature and modern anatomy.

## OBSERVATIONS

Cadaveric dissection was performed on two formalin-fixed cadavers to identify the probable anatomical counterparts of *Vitapa* and *Kateekataruna avedhya sira*.

In the *Vitapa* region, the superficial external pudendal vein, superficial epigastric vein, and superficial circumflex iliac vein were identified draining into the great saphenous vein. These vessels were found in close relation to the inguinal canal, superficial inguinal lymph nodes, and lymphatic vessels.

In the *Kateekataruna* region, superior and inferior gluteal vessels were identified deep to the gluteus maximus muscle in relation to the piriformis muscle. The vessels were closely associated with corresponding gluteal nerves and accompanied by venae comitantes.

## VESSELS FOUND IN THE *VITAPA STHANA*

**LEFT INGUINAL REGION**

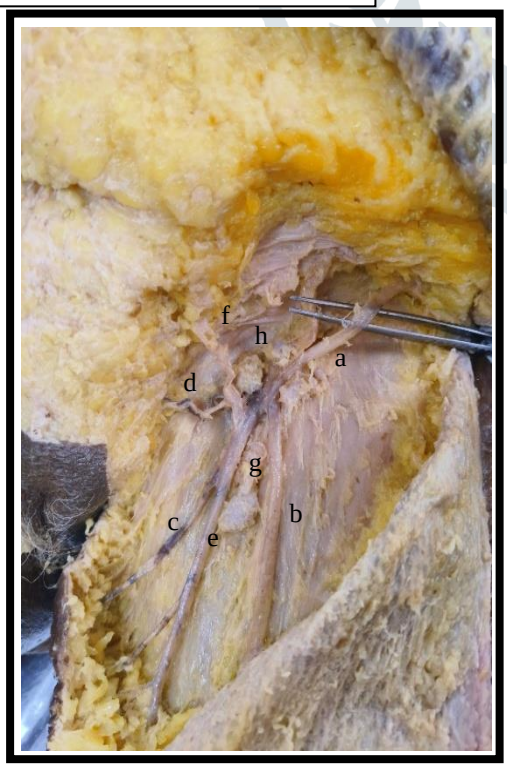


**Tributaries of left Great Saphenous vein**

a) Superficial circumflex iliac vein
b) Antero lateral vein
c) Postero medial vein
d) Superficial external pudendal vein
e) Great saphenous vein
f) Superficial Epigastric vein
g) Vertical group of inguinal lymph nodes
h) Horizontal group of inguinal lymph nodes

**RIGHT INGUINAL REGION**




**Tributaries of right Great Saphenous vein (veins appears stained because of embalming)**

a) Superficial circumflex iliac vein
b) Antero lateral vein
c) Postero medial vein
d) Great saphenous vein
e) Superficial epigastric vein
f) Superficial External Pudendal vein

## VESSELS FOUND IN THE KATEEKATARUNA STHANA

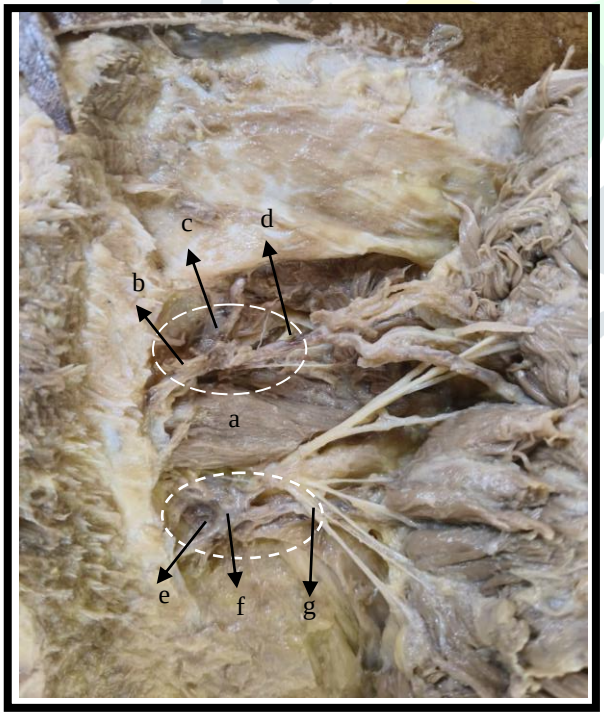


**Right gluteal vessels**

a. Piriformis
b. Superior gluteal artery
c. Superior gluteal vein
d. Superior gluteal nerve
e. Inferior gluteal vein
f. Inferior gluteal artery
g. Inferior gluteal nerve



**Venae Comitantes**
Right superior gluteal artery accompanying venae comitantes

## RESULTS

### *Vitapa* Region

The *Vitapa sira sthana* was identified in the region between the mid-inguinal point and pubic symphysis. The following vessels were observed:

- Superficial external pudendal vein
- Superficial epigastric vein
- Superficial circumflex iliac vein

These tributaries drained into the great saphenous vein, which subsequently drained into the femoral vein. The region also demonstrated close proximity to:

- Inguinal canal
- Superficial inguinal lymph nodes
- Lymphatic vessels
- Great saphenous vein termination into femoral vein

### *Kateekataruna* Region

The *Kateekataruna sira sthana* was identified approximately 2 cm lateral to the vertebral column, corresponding to the dimple of Venus over the posterior superior iliac spine.
The following structures were observed:

- Superior gluteal artery and vein
- Inferior gluteal artery and vein
- Superior gluteal nerve
- Inferior gluteal nerve
- Venae comitantes accompanying gluteal arteries

These structures were located deep to the gluteus maximus muscle and closely related to the piriformis muscle.

## DISCUSSION

### *Sthana of vitapa and kateekataruna avedhya sira*

A sira situated close to vital structures such as *marma*, *sevani*, *snayu*, *sandhi*, *dhamani*, or *jaala* is considered unsuitable for venesection. Injury to these structures during *siravyadha* may produce severe complications; therefore, Sushruta excluded several vessels located near important marma regions. Examples include *urvi* and *lohitaksha* in the *sakti*, *vitapa* and *katikataruna* in the *shroni*, *hridaya* and *sthanamoola* in the *vaksha*, *krukatika* and *vidhura* in the *greeva*, and *utkshepa*, *seemanta*, and *adhipati* in the *moordha*.

#### Vitapa sira

*Vitapa* is the *marma* situated in the midway between the *vrushana* and *vankshana*, it is the *snayu marma* of *vishalyaghna* variety. Cadaveric exploration was done around the area of *marma* which uncovered the vessels in the inguinal region which were further explored and appraised as the counterpart of *vitapa sira*. In this region veins were superficial but embedded in the adipose tissue and not accompanied with the artery and these veins were draining into the great saphenous vein and also they are lying in close proximity to the inguinal canal, improper *siravyadha* in this region may injure the inguinal canal and its contents. they are, ilio inguinal nerve and spermatic cord containing the vas deferens, pampiniform plexus of veins, testicular artery, genital branch of genitofemoral nerve in males and round ligament of uterus in females. Injury to vas deference can obstruct the sperm transport from testis. Injury to testicular vessels may reduce blood supply to testis which can affect spermatogenesis, injury to round ligament in females may cause disturbance of uterine support.

#### Kateekataruna sira

*Kateekataruna* is the *kaalantara pranahara asthi marma* situated on either side of the *prushtavamsha* along the *shroni khanda*. Cadaveric exploration was done around the area of this marma which uncovered the gluteal vessels situated deeply in relation with piriformis, beneath the gluteus maximus.

### *Visthara of vitapa and kateekataruna sira*

*Visthara* refers to the calibre or functional capacity of a vessel. Veins vary greatly in diameter depending upon their anatomical location and physiological function. Large veins such as the inferior vena cava possess a wide calibre due to their major circulatory role, whereas smaller superficial veins are delicate and fragile.

Although superficial veins are commonly used for procedures like intravenous injections, all superficial veins are not appropriate for *siravyadha.* Thin and fragile vessels do not permit adequate blood flow during venesection. According to Ayurvedic principles, proper *srava* should occur spontaneously after puncture. In vessels with very narrow calibre, blood flow becomes insufficient, leading to *ayoga* or complications such as *vaikalya* and even *marana*. Therefore, such vessels are excluded from *siravyadha*.

Among the vessels explored in this study the calibre of inferior gluteal veins and the superficial external pudendal vein was very narrow which becomes unsuitable for venesection. Superior gluteal vein, superficial circumflex iliac vein, superficial epigastric vein and the great saphenous vein have wide calibre, venesection or any injury of these vessels may lead to certain complications like excessive haemorrhage, hematoma formation, thrombophlebitis, varicosity and venous insufficiency etc.so such veins are unfit for venesection. Even though the caliber of the great saphenous vein is wide, only distal part of great saphenous vein is most commonly selected for venesection because venesection in the proximal part (vitapa sthana) may injure the femoral vein and there may be chances of injury to the inguinal canal and its contents as it is lying in close proximity to the vitapa sthana. And also, acharya Sushruta had given *shandya* and *alpa shukrata* as *vitapa marma viddha lakshana* which may correspond with the complications caused by the injury to the inguinal canal and its contents for example injury to the vas deference in male and round ligament in female may lead to the infertility in male and loss of uterus support in female.

**Depth of *vitapa* and *kateekataruna sira***

*Siravyadha* is ideally performed on superficial and easily accessible veins. Deeply situated vessels are avoided because the procedure does not involve deep incisions. Sushruta explains that excessively deep puncture (*Atividha*) may result in complications such as internal hemorrhage (*Antah Pravishati Shonitam*) and profuse bleeding (*Shonita Atipravrutti*). Hence, deeper structures are considered unsuitable for venesection.

***Vitapa sira***

In this region veins were superficial but embedded in the adipose tissue and not accompanied with the artery and these veins were draining into the great saphenous vein and also they are lying in close proximity to the inguinal canal, improper *siravyadha* in this region may injure the inguinal canal and its contents.

***Kateekataruna sira***

In present study the vessels in the *kateekataruna* area i.e. gluteal vessels were situated deeply beneath the gluteus maximus which becomes difficult for venesection.

***Relations***

The anatomical course of vessels is another important factor. Arteries and veins usually run together as neurovascular bundles. When veins are tortuous, coiled, or closely intertwined with arteries, puncturing them becomes hazardous. any arterial injury may lead to severe haemorrhage and vascular complications.

***Vitapa sira***

the superficial inguinal lymph nodes situated in the subcutaneous fat consist of upper and lower group, upper group forms the chain immediately below the inguinal ligament, lower group accompanies the lateral side of the termination of the great saphenous vein. Because of this close anatomical relationship, procedures performed in the region such as venesection, cannulation, surgical exposure carry significant clinical importance. Injury to the superficial inguinal lymph nodes or lymphatic vessels may lead to the leakage, lymphangitis, localized edema or secondary infection.

Most proximal part of great saphenous vein has two valves one is present just before it pierces the cribriform fascia, and another at its junction with the femoral vein, Injury to the proximal valves of the great saphenous vein, particularly near the saphenofemoral junction, may result in valvular incompetence causing reflux of blood from the femoral vein into the great saphenous vein, predisposing to varicosities and chronic venous insufficiency of the lower limb.

The proximity of these superficial veins to the femoral vein also increases the possibility of accidental deep venous injury during improper puncture. Since the femoral vein has large-caliber, deep vein trauma may result in profuse haemorrhage, thrombosis, embolic complications, or compression of adjacent structures within the femoral sheath. Infection from superficial tissues may further spread into deeper vascular compartments due to these anatomical communications.

Therefore, due to the presence of important vascular and lymphatic structures, this region can be considered unsuitable for venesection and supports vitapa sira inclusion under avedhya Sira

***Kateekataruna sira***

Among the vessels found in this study in the gluteal region both superior and inferior gluteal veins were running in close relation with the corresponding arteries as venae comitantes. the artery, vein and nerve were entering the gluteal region as a neurovascular bundle, and proximally the inferior gluteal vein was crossed by the inferior gluteal nerve.

## CONCLUSION

Dissection in the *Vitapa sira sthana* yielded the superficial vessels of the inguinal region they are superficial circumflex iliac vein, superficial epigastric vein, superficial external pudendal vein, accessary saphenous vein which are draining into the great saphenous vein, which in turn drains into the femoral vein this satisfy the number of *Vitapa sira* as 4 i.e great saphenous vein and the femoral vein of both the sides. These veins were embedded within the adipose tissue and they were not accompanying any arteries. Eventhough they are superficial, they are lying in close relation with the superficial inguinal lymph nodes and inguinal canal, injury to the lymph nodes may lead to the leakage, lymphangitis, localized edema or secondary infection and injury to inginal canal and its contents like vas deference, can obstruct the sperm transport from testis. Injury to testicular vessels may reduce blood supply testis which can affect spermatogenesis, injury to round ligament in females may cause disturbance of uterine support. During improper procedure of venesection, femoral vein may get injured and leading to the complications like profuse haemorrhage, hematoma formation,deep vein thrombosis, chronic venous insufficiency. By considering all these points *vitapa sira* are comprehended as *avedhya sira*.

Dissection in the *kateekataruna sira sthana* had shown the gluteal vessels, they are superior gluteal artery accompanying the superior gluteal veins as the venae comitantes along with the nerve, lying above the superior border of piriformis and inferior gluteal artery accompanying the inferior gluteal vein as the venae comitantes these vessels were crossed by the inferior gluteal nerve, lying below the inferior border of the piriformis. These findings satisfy the number of *kateekataruna sira* as 4, mentioned by acharya. As artery and veins are closely related with each other so there may be possibilities of injuring the accompanying artery.as the vessels are located deep in the gluteal region, they are not easily accessible for *siravyadha* so the *kateekataruna sira* is concluded as the *Avedhya sira*.

## REFERENCES


1. Raja Radhakanta Dev. editor. Shabdakalpadruma Panchama Kanda. Reprint ed. New Delhi. Nag Publishers.2006. p.172
2. Oka Govind Krishnaji(editor) The Namalinganusasana(Amarakosha) of Amarasimha. Ed. Poona. Law Printing Press.1913. p.293
3. Acharya Yadavji Trikamji(editor). Sushruta Samhita with Nibandha Sangraha commentary of Dalhanacharya and Nyayachandrika Panjika of Sri Gayadasacharya on Nidanasthana. Reprinted ed. Varanasi: Chaukhambha Sanskrit Sansthan.2019. p.150
4. Oka Govind Krishnaji(editor) The Namalinganusasana(Amarakosha) of Amarasimha. Ed. Poona. Law Printing Press.1913. p.292
5. Taranatha Tarka vachaspathi (compiler) Varanasi: Chowkhamba Sanskrit Series. p.521
6. Monier Williams(author). A Sanskrit English Dictionary Etymologically and Philosophically arranged. Ed. Oxford: Clarendron Press.1899. 69
7. Raja Radhakanta Dev. editor. Shabdakalpadruma Panchama Kanda. Reprint ed. New Delhi. Nag Publishers.2006. p.462
8. Raja Radhakanta Dev. editor. Shabdakalpadruma Panchama Kanda. Reprint ed. New Delhi. Nag Publishers.2006. p.462
9. Raja Radhakanta Dev. editor. Shabdakalpadruma Tritiya Kanda. Reprint ed. New Delhi. Nag Publishers.2006. p.624
10. Raja Radhakanta Dev. editor. Shabdakalpadruma Tritiya Kanda. Reprint ed. New Delhi. Nag Publishers.2006. p.624
11. Raja Radhakanta Dev. editor. Shabdakalpadruma Panchama Kanda. Reprint ed. New Delhi. Nag Publishers.2006. p.462
12. Raja Radhakanta Dev. editor. Shabdakalpadruma Chaturtha Kanda. Reprint ed. New Delhi. Nag Publishers.2006. p.383
13. Oka Govind Krishnaji(editor) The Namalinganusasana (Amarakosha) of Amarasimha. Ed. Poona. Law Printing Press.1913. p.169
14. Vaman Shivram Apte. The practical Sanskrit- English Dictionary. Reprint ed. New Delhi. Motilal Banarsidass Publishers. 2004.p.854
15. Monier Williams(author). A Sanskrit English Dictionary Etymologically and Philosophically arranged. Ed. Oxford: Clarendron Press.1899. p.584
16. Acharya Yadavji Trikamji(editor). Sushruta Samhita with Nibandha Sangraha commentary of Dalhanacharya and Nyayachandrika Panjika of Sri Gayadasacharya on Nidanasthana. Reprinted ed. Varanasi: Chaukhambha Sanskrit Sansthan.2019. p.371
17. Hari Sadasiv Sastri Paradakara(editor). Ashtanga Hrudayam of Vagbhata with Sarvanga Sundara of Arunadatta & Ayurvedarasayana of Hemadri.Varanasi Chaukhambha Surbharati Prakashan.2022. p.410
18. Oka Govind Krishnaji(editor) The Namalinganusasana (Amarakosha) of Amarasimha. Ed. Poona. Law Printing Press.1913. p.293
19. Oka Govind Krishnaji(editor) The Namalinganusasana (Amarakosha) of Amarasimha. Ed. Poona. Law Printing Press.1913. p.294
20. Oka Govind Krishnaji(editor) The Namalinganusasana (Amarakosha) of Amarasimha. Ed. Poona. Law Printing Press.1913. p.603
21. Acharya Yadavji Trikamji(editor). Sushruta Samhita with Nibandha Sangraha commentary of Dalhanacharya and Nyayachandrika Panjika of Sri Gayadasacharya on Nidanasthana. Reprinted ed. Varanasi: Chaukhambha Sanskrit Sansthan.2019. p.372
22. Giri et al. International Journal of Ayurveda and pharmaceutical chemistry 2019 Vol. 10 Issue 2.p.255 -264

23. Giri et al. International Journal of Ayurveda and pharmaceutical chemistry 2019 Vol. 10 Issue 2.p.255 -264
24. Raja Radhakanta Dev. editor. Shabdakalpadruma dwitiya Kanda.Reprint ed. New Delhi. Nag Publishers.2006. p.6
25. Oka Govind Krishnaji(editor) The Namalinganusasana (Amarakosha) of Amarasimha. Ed. Poona. Law Printing Press.1913. p.293
26. Vaman Shivram Apte. The practical Sanskrit- English Dictionary. Reprint ed. New Delhi. Motilal Banarsidass Publishers. 2004.p 327
27. Raja Radhakanta Dev. editor. Shabdakalpadruma Dwitiya Kanda. Reprint ed. New Delhi. Nag Publishers.2006. p .568
28. Oka Govind Krishnaji(editor) The Namalinganusasana (Amarakosha) of Amarasimha. Ed. Poona. Law Printing Press.1913. p.277
29. Vaman Shivram Apte. The practical Sanskrit- English Dictionary. Reprint ed. New Delhi. Motilal Banarsidass Publishers. 2004.p 469
30. Monier Williams(author). A Sanskrit English Dictionary Etymologically and Philosophically arranged. Ed. Oxford: Clarendron Press.1899. p.424
31. Acharya Yadavji Trikamji(editor). Sushruta Samhita with Nibandha Sangraha commentary of Dalhanacharya and Nyayachandrika Panjika of Sri Gayadasacharya on Nidanasthana. Reprinted ed. Varanasi: Chaukhambha Sanskrit Sansthan.2019. p.373
32. Acharya Yadavji Trikamji(editor). Sushruta Samhita with Nibandha Sangraha commentary of Dalhanacharya and Nyayachandrika Panjika of Sri Gayadasacharya on Nidanasthana. Reprinted ed.Varanasi: Chaukhambha Sanskrit Sansthan.2019. p 373
33. Anurag Tiwari, Vijay LaxmiGautam, Ashutosh Kumar Pathak, Abhinav. Conceptual Study of Katikataruna Marma and It's Clinical Significance. Bull. Env. Pharmacol. Life Sci., Vol 11[3] Feb 2022: 206-208.
34. Acharya Yadavji Trikamji(editor). Sushruta Samhita with Nibandha Sangraha commentary of Dalhanacharya and Nyayachandrika Panjika of Sri Gayadasacharya on Nidanasthana. Reprinted ed.Varanasi: Chaukhambha Sanskrit Sansthan.2019. p373